

**Borys Y. Reminetskyy  
Yaroslav I. Fedonyuk  
Volodymyr D. Voloshyn**

**GUIDANCE  
FOR PRACTICAL CLASSES  
ON HUMAN ANATOMY**

Ternopil  
“Ukrmedknyga”  
2003

## **Preface**

Notes for practical studies on Human Anatomy are not a textbook. We think about students who have dealings with spacious volume of anatomical knowledge. This edition does not enclose all depth of scientific data. Instead, it contains exposition in condensed and comfortable for readers form synopsis of anatomic basis. In this way we want to achieve a happy medium between complexity and simplification in describing the structure of human body.

We are most appreciative of our colleagues:

Assistant Professors Natalya Y. Lisnychuk, Ph.D. and Natalya V. Shovdra, M.D., and lecturer Svitlana I. Yavorsyka for their helping in preparation of these notes.

**Authors:**

## Contents

INTRODUCTION .....	5
SKELETAL SYSTEM AND ARTICULATIONS .....	9
MUSCULAR SYSTEM .....	32
DIGESTIVE SYSTEM .....	86
RESPIRATORY SYSTEM .....	103
URINARY SYSTEM .....	109
REPRODUCTIVE SYSTEM .....	112
ENDOCRINE SYSTEM .....	119
HEART .....	120
ARTERIAL SYSTEM .....	125
VENOUS SYSTEM .....	137
LYMPHATIC SYSTEM .....	142
NERVOUS SYSTEM .....	149
AUTONOMIC NERVOUS SYSTEM .....	181
THE SENSES AND CRANIAL NERVES .....	186



## INTRODUCTION

Anatomy is the study of the structure of the body. Derived from the Greek to cut up: the Latin 'to cut up' gives us dissect.

**Subdivisions.** Under the general heading of anatomy are several subdivisions.

**Gross anatomy** deals with those structures that can be seen without a microscope.

**Embryology** examines development of adult structure from fertilised ovum.

**Cytology** deals with the structure of individual cells.

**Histology** deals with aggregations of cells, tissues, or aggregations of tissues, organs.

**Neuroanatomy** deals with the elaborate connections of nerve cells.

## METHODS OF STUDY

**Dissection** of a fixed cadaver is the most important tool of anatomists. The dissection may be done by you, the students (and you will have opportunities to practice this skill during the course) or by someone else on your behalf, to produce prosections which show particular regions or features. Prosections save you time, but I suspect that dissection leaves a longer lasting impression of structure. **Living anatomy** is the observation of the living body at rest or in action. Instruments do exist to allow us to extend the view from the outside on patients. These are usually called-scopes: endoscopes, proctoscopes, bronchoscopes etc. all allow further examination. Nowadays these are often fibre optic devices aided by computer visualisation, and can allow a good view of the gall bladder or the inside of the knee joint. We can also add a range of indirect imaging techniques. The first of these was probably radiology, the directing of a beam of x-rays at a subject and the measurement of the intensity of what passes through, usually by means of darkening a photographic plate. Different tissues absorb radiation to different degrees, and the pattern of densities can record position shape and size of bones, fat, gas filled structures and so on. Interpretation is often a little difficult because structures at some distance from the source are magnified as the rays diverge and all structures are in focus, and so appear piled on top of each other in two dimensions. A plain radiograph can be enhanced by filling relevant bits of the patient with contrast medium, which is opaque to x-rays.

This can be injected into a blood vessel or swallowed to outline parts of the gut.

**Radio isotope imaging** is a variant of this where the contrast medium is replaced by a radio labelled substance avidly taken up by the target tissue – for instance radio iodine can be used to target the thyroid gland. **Tomography**, is a newer technique in which source and photographic plate are moved in relation to the subject. **Computer Assisted Tomography** (CAT) is an even more sophisticated technique in which both x-ray source and detector (replacing film) are moved around the body, producing a data stream which is interpreted by a computer as a series of images equivalent to cross sections through the body at fixed intervals. The drawback is of course that X rays are now known to be harmful, inducing mutation and tissue damage.

Alternatives include:

- **ultrasound** which reflects from boundary layers between tissues of different densities
- **magnetic resonance imaging** (MRI) produces images according to the atomic structure of their major components, by subjecting them to a strong collapsing magnetic force. Again pictures equivalent to cross sections of the body are produced.

We must also not neglect comparative anatomy.

## **Vocabulary**

Anatomy has a very specialised vocabulary, much of it inherited from Latin, Greek. There is a standard list of terms, in Latin, which has the disadvantage that virtually no one uses it.

## **Major parts of the body**

Anatomical usage follows general for most of the main parts, head neck, and trunk. The limbs are a little different. The Anatomist calls these the upper and lower limbs, and arm means between shoulder and elbow, and leg between knee and ankle. We subdivide the trunk into thorax, above the diaphragm and abdomen, below it.

## **The anatomical position**

For descriptive purposes the body is always imagined to be in the anatomical position, standing erect, arms by sides, palms of hands facing forwards. In this position directions are given by **superior**, **inferior**, **anterior**, **posterior**. These are equivalent to the zoologist's **cephalic**,

**caudal, ventral and dorsal.** Thus the eyes are always superior to the mouth, even if the patient is lying down or standing on his head. These terms are not quite equivalent to above, below, in front of and behind. To a layman acrobats' feet are above her head when she is dangling from a trapeze: to an anatomist they are inferior.

Other dimensions are referred to the midline – **median, medial** or **lateral**, or to their closeness to the body surface, **superficial** or **deep**. In the limbs structures near the trunk are **proximal**, those further away are **distal**. We have a problem with the hands and feet: the palms of the hands resemble the soles of the feet and the thumb is equivalent to the great toe. But the **palmar** surface of the hand faces anteriorly and the back is **dorsal**. In the foot we defy logic and call the inferior surface **plantar** (equivalent to palmar) and the superior surface **dorsal**, even though it faces upwards. But we are still not out of the wood because the great toe is medial but the thumb is lateral. To get around this the term preaxial is often used to describe the thumb or great toe side. Postaxial is the little toe or little finger side. The axis referred to runs to the tip of the middle finger or the second toe.

The other small problem, the penis, is described in its erect position, so that its dorsal surface faces anteriorly and superiorly when detumescent.

We also need to define planes, mutually at right angles. The horizontal plane is clear enough: the other two are a little less so. The **sagittal** plane (L. sagitta, an arrow) probably refers to the sagittal suture which runs from anterior to posterior in the newborn skull, and has an arrowhead in the form of the frontal fontanelle. Coronal is also difficult since it means crown, and I always think of a crown as being horizontal. But this is an older usage, as in the crown of an arch or a tooth, or the road, meaning something more like a halo. Once again these refer to the anatomical position.

Now that we can describe the body at rest we can also deal with movement.

**abduction** is movement of any part away from the midline in the coronal plain

**adduction** is return to the midline flexion is moving anything in the sagittal plane

**extension** is straightening it again.

**lateral** flexion is bending in the coronal plane

**opposition** which brings its palmar surface in contact with the palmar surface of the fingers.

**rotation** occurs around a vertical axis, or the main axis of the limb. If we rotate the head to the right we end up facing right. For the limbs we still use the displacement of the anterior aspect i.e. lateral rotation moves the palm laterally. The shoulder is a good joint to illustrate movement because it is so free. The slide shows what we can do, and how we describe it.

Hand and foot again pose problems because of their distinctive orientation. The hand has a rather unusual movement whereby the thumb can be brought to lie medially: in fact this crosses the bones of the forearm. The anatomical position of the hand is called supine, the reverse prone, so this movement is **pronation** reverse **supination**.

### **Variability in anatomy**

One important fact which an anatomist must recognise is that no two of us, even identical twins are exactly alike. The structure of the body varies with age, race, sex, genetic diversity, environmental history (especially during growth)

**connective tissue** – less elasticity – wrinkles

**cartilage** – less elasticity – degenerative changes such as osteoarthritis with associated changes. Costal cartilages often replaced by bone: bony spurs develop in unusual places.

**bone** – becomes brittle, reduced in size with less activity

**muscle** – ditto, plus deposition of fat.

**heart and blood vessels** – arteries become tortuous, walls become furred up with atheroma. Left ventricle is enlarged as consequence of load. Veins often varicose.

**nervous system** – Often small strokes will cause paralysis and reduction in size of some muscles.

**Sex** – The two sexes obviously differ in their reproductive organs: they also differ in many other respects: although variability is quite large within a sex height, weight and muscle mass will differ significantly. Males also have narrower hips and broader shoulders. Females have more dermal fat, distributed differently. Facial and body hair also differs.

**Genetic and other variation** – congenital anomalies – There is quite a high level of genetic and environmental variation which leads to the presence of extra fingers, a single kidney, or an extra rib or so. This may be genetical or due to the exposure of the fetus to something unpleasant during pregnancy – x-rays, medicaments, viruses. Superimposed upon this is the variation due to habit – a regular swimmer will have a better developed upper body than his or her classmates: a smoker may have inferior lung capacity.



## SKELETAL SYSTEM (OSTEOLOGY)

Bones form the skeleton that they divide into bones of the trunk, skull, and limbs. Bones of the trunk comprise vertebrae, sternum and ribs.

### **Vertebrae**

The vertebral column consists of 33-34 vertebrae: 7 cervical, 12 thoracic, 5 lumbar, 5 sacral and 4-5 coccygeal vertebrae. The sacral vertebrae fuse and form the sacrum and the coccygeal vertebrae fuse together and form the coccyx. Thus the sacral and coccygeal vertebrae are false vertebrae while the others are true vertebrae.

*Function of the vertebrae:* 1) Supporting and amortisation; 2) Defence; 3) Motor; 4) Metabolic; 5) Homeopoetic.

Each vertebrae has a vertebral corpus (body) and vertebral arch. They border vertebral foramina that form the vertebral canal when vertebrae lay each other in backbone. Vertebral arch carries 7 processes: unpaired *spinous process* (projecting dorsally), *paired transverse processes* (for articulation with the ribs), the *superior articular process* and the *inferior articular process processes* (for articulation vertebrae each other). The vertebral notches, one caudal and one cranial, together form the *intervertebral foramen*, which serves the passage of the spinal nerves.

### ***Peculiarities of the III-VII Cervical Vertebrae***

1. Transverse process carry foramen transversarium.
2. Spinous process is bifurcated.
3. The transverse process has an anterior tubercle and a posterior tubercle, between them we find a groove, the sulcus for the spinal nerve.
4. Articular surfaces lay in horizontal plane.

1<sup>st</sup> Cervical Vertebra, the Atlas differs basically from the other vertebrae:

It has not any vertebral body. In the atlas we therefore describe a smaller *anterior arch* and a larger *posterior arch*. Both arches have small protuberances: the *anterior* and *posterior tubercles*. Lateral to the large *vertebral foramen* of the atlas lie the *lateral masses*, each of which have a *superior* and an *inferior articular facet*. On the inner side of the anterior arch is the articular facet for the dens, *fovea dentis*. From the *foramen of the transverse process*, which is located in the *processus transversus*, a groove, the *sulcus arteriae vertebralis*, extends across the posterior arch for the reception of the vertebral artery.

2<sup>nd</sup> Cervical Vertebra. The axis carries the dens or *odontoid process*.

On the cranial surface of the body the axis carries a tooth-like process, the *dens axis*, which ends by the *apex dentis*. The surfaces of the dens have an *anterior articular facet* and the *posterior articular facet*.

The anterior tubercle of the 6th cervical vertebra can be very large and is designated as the *carotid tubercle*.

The 7<sup>th</sup> cervical vertebra has a particularly large spinous process, which is usually the highest palpable spinous process of the vertebral column; it is therefore called the *vertebra prominens*.

#### ***Peculiarities of the Thoracic Vertebrae***

1. Laterally, the vertebral body usually has two *costal facets*, each of which is half of an articular facet for articulation with the head of a rib.

2. *Transverse processes* carry a *costal facet* for articulation with the costal tubercle.

3. The spinous processes of the 1st through the 9<sup>th</sup> thoracic vertebrae overlap each other like roof tiles.

4. Articular surfaces lay in frontal plane.

The 1st thoracic vertebra has a complete articular facet at the cranial border of its body and a half facet at the caudal border. The 10<sup>th</sup> vertebra has only a half articular facet, while the 11<sup>th</sup> has a complete articular facet at its cranial border. The 12<sup>th</sup> thoracic vertebra has the articular facet for the head of the rib in the middle of the lateral surface of the body. There may be an *accessory process* and a *mamillary process* each side.

#### ***Peculiarities of the Lumbar Vertebrae***

1. The bodies are much larger than those of the other vertebrae.

2. The *spinous process* is flat and is directed sagittally.

3. The flattened lateral processes of the lumbar vertebrae may be called *costal processes*, and since they originate from rib anlagen.

4. Articular surfaces of the articular process lay in sagittal plane.

#### ***Peculiarities of the Sacral Vertebrae***

The sacrum consists of the five sacral vertebrae. It has a concave anterior or pelvic surface and a convex dorsal surface. The sacrum has the base and the *apex*. The pelvic surface has four paired pelvic *anterior sacral foramina* and *transverse lines*. In the convex dorsal surface there are *posterior sacral foramina* and five longitudinal ridges, not always clearly developed, have their origin in fusion of the corresponding processes of the vertebrae (*median sacral*, *intermediate sacral* and *lateral sacral crests*).

The *sacral canal* is located in bone and it terminates by the *sacral hiatus*, bounded laterally by the *two sacral horns*. *Auricular surface* for

the articulation with the hip bone and *sacral tuberosity* can be seen in *lateral parts*.

### **Coccyx**

The coccyx, which is usually formed from three to four vertebrae, has body and *cornua* or *horns*.

All vertebrae compose vertebral column, which has cervical and lumbar curves forward (lordosis), and thoracic and sacral curves backward (kyphosis).

### **Sternum**

The sternum consists of the *manubrium sterni*, the *body* and the *xiphoid process*. Between the manubrium and the body lies the *sternal angle*. At the cranial end of the manubrium sterni is the *jugular notch* and lateral to it on either side the *clavicular notches*. The sternum has costal *notches* for a continuous cartilaginous joint with the I-VII ribs.

### **Ribs**

In each rib we distinguish a bony part, the *os costale*, and at the anterior end the costal cartilage.

There are twelve pairs of ribs, of which the upper seven are connected directly to the sternum and are called true ribs. The lower five ribs, false ribs, are joined indirectly (8<sup>th</sup>-10<sup>th</sup>) or not at all (11<sup>th</sup>-12<sup>th</sup>) to the sternum. The 11<sup>th</sup> and 12<sup>th</sup> rib can be contrasted with the others as floating ribs.

Each rib has a head, neck and a *body*. The junction between the neck and the body is at the *tubercle*. The head and the tubercle each have an articular facet. From the 2<sup>nd</sup> to the 10<sup>th</sup> rib, the *articular facet of the head* is divided into two by the *crest of the head of the rib*. Lateral and ventral to the tubercle is the *angle of the rib*. With the exception of the 1<sup>st</sup>, 11<sup>th</sup> and 12<sup>th</sup>, all ribs have a *costal sulcus* on the lower surface.

The 1<sup>st</sup> rib is small and flattened. On the inner circumference of its cranial surface is an area of roughness, the *scalene tubercle*. Posterior to it lies the *sulcus of the subclavian artery*, and in front of it is the *sulcus of the subclavian vein*. The 2<sup>nd</sup> rib has *tuberosity for the serratus anterior muscle*.

### **Bones of the upper limb**

In the upper limb we distinguish the shoulder girdle and the free extremity.

The shoulder girdle is formed by the scapulae and the clavicles.

#### **Clavicle**

Clavicle is an S-shaped bone. Toward the sternum is the sternal end with the *sternal articular facet* and toward the scapula the flat *acromial*

end with *acromial articular* facet and between the two lies the body of the clavicle. Near the sternal end, on the lower surface of the clavicle, is the *impression for the cosloclavicular ligament*. The sulcus for the subclavian muscle lies on the undersurface of the clavicular body. The prominent *conoid tubercle* lies near the acromial end close to the *trapezoid line*.

**Scapula** is a flat, triangular bone. It has a *medial margin*, a *lateral margin* and a *superior margin*, which are separated from each other by the *superior* and *inferior* angles and *lateral angle*. The anterior or *costal* surface is flat and slightly concave (subscapular fossa). It sometimes shows clear lines of muscle attachments. The *dorsal surface* is divided by the *spine of the scapula* into a smaller *supraspinous fossa* and a larger *infraspinous fossa*. The spine rises laterally to terminate in a flattened process, the *acromion*. Near the lateral end lies an oval *articular facet* for articulation with the clavicle.

The lateral angle bears the *glenoid cavity with supraglenoid tubercle and the infraglenoid tubercle*. The *neck of the scapula* is adjacent to the glenoid cavity.

The *coracoid process* lies above the glenoid cavity. On the upper margin of the scapula, lies the *scapular notch*.

### ***The bones of the free upper limb***

The bones of the free upper limb are the skeleton of arm, forearm and hand.

**Humerus** articulates with the scapula and the radius and ulna. It consists of the body and upper (proximal) and lower (distal) ends.

The proximal end is formed by the *head of the humerus*, adjoining the *anatomic neck*. There are the greater tubercle, and medially is the lesser *tubercle*. Between these tubercles begins the *intertubercular sulcus*, which is bounded distally by the *crests of the lesser and greater tubercles*. The *surgical neck* lies proximally on the body of the humerus. In the middle of the body lies laterally the *deltoid tuberosity and sulcus for the radial nerve*. The body may be divided into an *anteromedial surface* with a *medial border*, and an *anterolateral surface* with a *lateral border*, which becomes sharpened distally and is called the *lateral supracondylar crest*. The distal end of the humerus bears on its medial side the large *medial epicondyle* and on the lateral side the smaller *lateral epicondyle*.

The *trochlea* and the *capitulum* of the humerus form the *humeral condyles* for articulation with the bones of the forearm. The *radial fossa* lies proximal to the capitulum and proximal to the trochlea is the somewhat larger *coronoid fossa*.

MC

Medial to the trochlea there is a shallow groove, the *sulcus for the ulnar nerve*. On the posterior surface above the trochlea is a deep pit, the *olecranon fossa*.

### **Ulna**

The ulna has a shaft and proximal and distal ends. The proximal end bears a hook-like process, the *olecranon*. Anteriorly the *trochlear notch* extends as far as the *coronoid process*, and laterally is the radial notch into which the articular circumference of the radius fits. At the junction with the shaft lies the *ulnar tuberosity*. Laterally lies radial notch. The *interosseous border* lies laterally. The *anterior surface* is separated from the *medial surface* by the *anterior border*. The latter in turn is separated from the *posterior surface* by the *posterior margin*. In the middle of the ulna, on its anterior surface, is the *nutrient foramen*. The *articular circumference* is on the head of the ulna. At the distal end of the ulna is the small *styloid process*.

### **Radius**

The radius consists of a shaft and proximal and distal ends. At the proximal end is the *head of the radius* with the *fovea articularis*, which is continuous with the *articular circumference*. On the medial side of the transition between the *neck of the radius* and the shaft lies the *radial tuberosity*. The shaft has a medially facing *interosseous border*, an *anterior surface*, and *anterior border*, a *lateral surface* and a *posterior border*, which forms the boundary between the *lateral* and the *posterior surfaces*. At the lower end of the radius lies the *styloid process* and medial to it is the *ulnar notch*. The *carpal articular surface* faces distally.

Bones of the hand consist of carpus, metacarpus and digits.

The **carpus** consists of eight carpal bones arranged in two rows of four. In the *proximal* row from lateral to medial are the scaphoid, lunate, triquetrum and pisiform. In the *distal* row from the lateral to the medial side are the trapezium, trapezoid, capitate and hamate.

The five **metacarpals** of the hand each have a head, a body and a base. On all of the there are articular facets at one end (base) for articulation with the carpals and at the other (head) for the phalanges.

Each digit consists of bones namely a proximal, a medial and a distal **phalanx**. The sole exception is the thumb, which has only two phalanges. At the distal end halanx there is *the tuberosity of the distal phalanx*.

### ***Bones of the lower limb***

Bones of the lower limb consist of girdle and free limb.

Pelvic girdle contains hip bones.

The **hip bone (os coxae)** consists of three parts, the pubis, the ilium and the ischium which synostose in the *acetabular fossa*, which is bordered by the *limbus of the acetabulum* and is surrounded by the *lunate articular surface*. The *acetabular notch* opens the acetabulum inferiorly and thus limits the *obturator foramen*.

The **Ilium** is divided into the *body* and the *ala*. The body forms part of the acetabulum and is delimited internally by the arcuate line. Internally the *iliac fossa* is visible. Behind the iliac fossa there is the sacropelvic surface with the *iliac tuberosity* and the *auricular surface*. The *iliac crest* starts anteriorly at the *superior anterior iliac spine* and divides into the outer and *inner* lips and an *intermediate line*. The iliac crest ends in the *posterior superior iliac spine*. Beneath the latter lies the *posterior inferior iliac spine*, whilst anteriorly beneath the anterior superior iliac spine lies the *anterior inferior iliac spine*. The *inferior gluteal*, *anterior gluteal* and *posterior gluteal* lines on the gluteal surface.

The **pubis** consists of a *body*, a *superior ramus* and an *inferior ramus*. The two rami border the obturator foramen anteriorly and inferiorly. Near to the superior end of the medially orientated *symphyseal surface* lies the *pubic tubercle*, from which the *pubic crest* extends medially and the *pubic pecten* runs laterally toward the *arcuate line of the ilium*. At the transition of the superior ramus of the pubis into the ilium, there is the elevation of the *iliopubic eminence*. The *obturator groove* lies inferiorly in the *superior ramus*.

The **Ischium** is divided into the *body* and the *ramus of the ischium*, which together with the inferior ramus of the pubis forms the inferior border of the obturator foramen. The ischium bears the *ischial spine*, which separates the *greater sciatic notch* from the *lesser sciatic notch*. The *ischial tuber* develops on the ramus of the ischium.

Free portion of the lower limb is divided into thigh, leg and foot.

Thigh contains Femur.

The **femur** is the largest long bone in the body and is divided into the shaft with the neck, and proximal and distal ends. Dorsally in shaft is the *linea aspera*. The *medial* and *lateral* lips of the linea aspera diverge proximally and distally, and the lateral lip ends in the *gluteal tuberosity*.

The *head of the femur* with the *fovea of the head*, has an irregular border with the neck. The transit from the neck to the shaft of the femur is marked anteriorly by the *intertrochanteric line*, and posteriorly by the

*intertrochanteric crest*. Immediately below the *greater trochanter* lies the *trochanteric fossa*. The *lesser trochanter* projects posteriorly and medially.

The distal ends are formed by the medial and *lateral condyles*. They are joined on the anterior surface by the *patellar articular surface* and they are separated posteriorly by the *intercondylar fossa*. The latter is demarcated from the posterior surface of the shaft by the *intercondylar line*, which forms the base of a triangle *popliteal surface*, the sides of which are formed by the divergent lips of the *linea aspera*.

The **patella** is the largest sesamoid bone of the human body. It is triangular in shape with its base facing proximally and its top, the *apex patellae* facing distally.

Tibia is positioned medially in leg and fibula – laterally.

The **tibia** has a somewhat triangular shaft and proximal and distal ends. At the proximal end lie the *medial* and *lateral condyles*. The proximal surface, the *superior articular facet* is interrupted by the *intercondylar eminence*. This elevation is subdivided into a *medial* and a *lateral intercondylar tubercle*. In front of and behind the eminence lie the *anterior* and *posterior intercondylar* area. The three-sided shaft of the tibia has a medial, lateral margins and sharp *anterior margin*, which proximally becomes the *tibial tuberosity* and is flattened distally. Margins separate the *medial, lateral and posterior surfaces*. Proximally on the posterior surface of the shaft of the tibia is a slightly roughened area, the *muscle solei line*.

The distal end is prolonged medially to form the *medial malleolus* with its *malleolar articular surface*. The *malleolar groove* runs along its posterior surface. The *inferior articular surface of the tibia*, which lies on the lower surface of the distal end of the tibia, articulates with the talus. On the lateral side, in the *fibular notch*, there is a syndesmotic connection, i. e., a fibrous joint, with the fibula.

**Fibula** consists of two extremities and a shaft. The proximal end is the *head of the fibula* with its *articular facet* and a small protuberance, the *apex of the fibula head*. The shaft of the fibula is approximately triangular in its middle part and has three margins and three surfaces. On the lateral surface of the distal end, which expands distalward, there is the large, flat *lateral malleolus* with a *facet for articulation with the talus on its inner surface*. Behind it there is a deep groove, the *lateral malleolar fossa*, to which the posterior talofibular ligament is attached.

*Bones of the foot* are divided into tarsal, metatarsal and phalanx bones.

**Tarsal** bones are positioned in 2 groups: proximal and distal. Proximal group includes **talus, calcaneus**. Distal group contains **navicular, cuboid, lateral, intermedial and medial cuneiform bones**.

**Metatarsal bones** (five) each have a head, a body and a base. On all of them there are articular facets at one end (base) for articulation with the tarsal and at the other (head) for the phalanges.

The bones of the digits: Each digit consists of more than one bone, namely a proximal, a medial and a distal **phalanx**. The sole exception is the halux, which has only two phalanges. At the distal end of the distal phalanx there is a *the tuberosity of the distal phalanx*.

### ***Bones of skull***

Bones of skull divide into neurocranium and viscerocranium bones. Neurocranium bones form the base and the roof.

Base of the skull has an inner and outer surfaces. It is formed by frontal, ethmoid, sphenoid temporal and occipital bones. Inner base consists of anterior, middle and posterior cranial fossae.

Roof of the skull is formed by occipital, parietal, temporal and frontal bones.

**Occipital** bone consists of occipital squama, lateral and basilar parts.

Squama is situated above and behind the foramen magnum and possesses external occipital protuberance and external crest on outer surface and it. Also there are the superior and inferior nuchal lines. The internal surface is deeply concave and carries a crucial eminence. At the point of intersection of the four divisions of the crucial eminence and internal occipital protuberance. Right and left sides of them is a deep groove, the superior sagittal sulcus, lower there is the internal occipital crest.

Lateral Parts (pars lateralis) are situated at the sides of the foramen magnum; on their under surfaces are the condyles with and the hypoglossal canal. Behind either condyle is the condyloid fossa. Laterally is the jugular process, excavated in front by the jugular notch. Basilar Part (pars basilaris) extends forward and upward from the foramen magnum and form the back part of the clivus. On its lower surface is the pharyngeal tubercle which gives attachment to the fibrous raphe of the pharynx.

The **Parietal** Bone (Os Parietale) form, by their union, the sides and roof of the cranium. Each bone is irregularly quadrilateral in form and has convex external (with tuber parietale) surface and concave internal surfaces. Bone has four corners: frontal, sphenoid, mastoid and occipital; and four



margins. Near the sagittal margin are several depressions for the arachnoid granulation.

The **Frontal** Bone (Os Frontale) consists of three portions – the squama, and an orbital and nasal portions, which enters into the formation of the roofs of the orbital and nasal cavities. Squama in the external surface has tuber frontale and the superciliary arches; are joined to one another by a smooth elevation named the glabella. At the supraorbital margin is a notch, sometimes converted into a foramen. The supraorbital margin ends laterally in the zygomatic process. Nasal part presents the ethmoid notch and a sharp spine. In nasal part they can find aperture for frontal sinus. The internal surface of the squama is concave and contains the superior sagittal sulcus and the frontal crest. The crest ends below in a small notch which is converted into a foramen, the foramen cecum. Orbital part presents the lacrimal gland fossa and the fovea trochlearis with trochlear spine.

The **Sphenoid** Bone (Os Sphenoidale) is situated at the base of the skull and is divided into a body, two great and two small wings and two pterygoid processes.

Body (corpus sphenoidale) contain the sphenoidal air sinuses. Superiorly there is chiasmatic groove and tuberculum sellae forward from the sella turcica with the hypophysial fossa and dorsum sellae. Behind the dorsum sellae is the clivus.

The anterior surface of the body (Fig. 146) presents the sphenoidal crest that continues into rostrum.

The Great Wings (alae major) have the cerebral surface with the foramen rotundum, foramen ovale and foramen spinosum. Also they differ maxillary, temporal (with the infratemporal crest) and orbital surfaces.

The Small Wings (alae minor) arise from the upper and anterior parts of the body. Between the two roots is the optic canal. Alae minor borders the superior orbital fissure with alae major.

Pterygoid Processes (processus pterygoidei) descend perpendicularly from the regions where the body and great wings unite. Each process consists of a medial and a lateral plate, the upper parts of which are fused anteriorly; a vertical sulcus, the pterygopalatine groove. The plates are separated below by the pterygoid incisura. The two plates diverge behind and enclose between them a V-shaped fossa, the pterygoid fossa. Pterygoid canal is in base of process. The medial pterygoid plate has the pterygoid hamulus.

The **Temporal** Bone (Os Temporale) is situated at the sides and base of the skull. Each consists of the squama, the petrous (pyramid) with

mastoid process and tympanic part. The squama has a groove for the middle temporal artery and the temporal line. It is a long the zygomatic process. The mandibular fossa is bounded, in front, by the articular tubercle.

Pars petrosa [pyramis] has a base and apex, and anterior, posterior and inferior surfaces, and three angles, and contains the of the organ of hearing and balance. The base is fused with the internal surfaces of the squama and mastoid portion. The anterior surface has eminentia arcuata, the tegmen tympani; hiatus and sulcus canalis nervi petrosi majoris; laterally hiatus and sulcus canalis nervi petrosi minoris; near the apex of the bone, the termination of the carotid canal (foramen internus); above this canal the trigeminal impression. The posterior surface has the internal acoustic meatus, the aperture externa aqueductus vestibuli, the subarcuate fossa. The inferior surface contain foramen coroticum externus, the jugular fossa, a small opening of the aqueductus cochleae, the styloid process and the stylomastoid foramen. Mastoid Process is perforated by the mastoid foramen and carries the sigmoid sinus sulcus. A section of the mastoid process shows it to be hollowed out into a number of spaces, the mastoid cells and mastoid antrum.

Tympanic Part (pars tympanica) forms the walls and the floor of the bony external acoustic meatus. It borders the tympanomastoid fissure.

#### ***Canals of the temporal bone:***

1. **Carotid canal** starts in *external carotid foramen* on lower surface of the piramis and finishes by internal opening in apex of the piramis.

2. **Facial canal** starts in internal acoustic meatus on back surface of the piramis and finishes in stylomastoid foramen on lower surface of the piramis.

3. **Musculotubarius canal** is divided into semicanalis m. tensoris tympani and semicanalis tubae auditivae. It starts on anterior margin of the piramis and leads to the tympanic cavity.

4. *Caroticotympanic canaliculi* (paired) start on medial wall of the external carotid foramen and lead to the the tympanic cavity.

5. *Canaliculus for chorda tympani* starts in facial canal, passes through the tympanic cavity and finishes in petrotympanic fissura.

6. *Tympanic canaliculus* starts in the petrosal fossula and finishes in hiatus canalis nervi petrosi minoris.

7. *Mastoid canaliculus* starts on the floor of the jugular fossa and passes to the tympanomastoid fissura.

**Ethmoid bone** (Os Ethmoidale) is situated at the anterior part of the base of the cranium, between the two orbits, at the roof of the nose. It

consists of cribriform plate, a perpendicular plate, constituting part of the nasal septum; and two lateral labyrinths. Cribriform Plate (lamina cribrosa) is perforated by foramina carries the crista galli which borders the foramen coecum.

The Labyrinth (labyrinthus ethmoidalis) consists of a number of thin-walled cellular cavities, the ethmoidal cells, arranged in three groups, anterior, middle, and posterior, and interposed between two vertical plates of bone; the lateral plate forms part of the orbit – lamina frontalis. Medially labyrinth has concha nasalis superior and concha nasalis media. There is superior nasal meatus between them.

### ***Bones of viscerocranium***

Bones of viscerocranium include: maxilla, zygomatic, nasal, palatine, lacrimal bones, vomer, greater portion of the ethmoid, mandible and inferior nasal concha.

**Maxilla** – paired bone, has a body and four processes: frontal, zygomatic, alveolar and palatine. Frontal process riches the nasal part of the frontal bone, medially it carries ethmoidal crest for middle nasal concha. Zygomatic process joins zygomatic bone. Alveolar process carries dental alveoli for insertion the teeth. Palatine process forms bony palatine.

There are four surfaces in maxillary body: anterior, upper (orbital), medial (nasal) and back (infraorbital). Anterior surface is bordered by infraorbital margin where it is infraorbital foramen. Nasal surface carries maxillary hiatus that communicates nasal cavity with maxillary (Haymory) sinus.

**Zygomatic** bone (paired) has frontal and temporal processes; lateral, temporal and orbital surfaces.

**Nasal** bone (paired) forms bony part of nasal dorsum.

**Palatine** bone (paired) forms part of nasal cavity, mouth, orbit and pterygopalatine fossa. It has perpendicular and horizontal laminae.

**Lacrimal** bones (paired) forms anterior part of the medial orbital wall.

**Vomer** (unpaired) is located in nasal cavity and forms bony septum nasi with perpendicular lamina (ethmoid bone).

**Mandible** (unpaired) has a body and two rami. There is alveolar arch with teeth alveoli. Mandibular angle is located between, body and rami and it carries masseteric and pterygoid tuberosities for attachment of mastication muscles. Ramus contains coronal and condilar processes. Mandibular canal starts on the inner surface of the ramus and terminates by mental foramen in body. It contains vessels and nerves that supply teeth in the lower jaw. This is only bone that form synovial joint.

**Inferior nasal concha** (paired) – thin plate that separate middle and inferior nasal meatus.

**Hyoid** bone is positioned in neck above the larynx. It has body, large and small horns.

### ***Skull as whole***

*Orbit* has a superior, inferior, lateral and medial walls. Upper wall formed by frontal bone and sphenoid lesser alae. Lower wall composed by maxilla, zygomatic and palatine bones. Lateral wall formed by zygomatic bone and sphenoid greater alae. Medial wall consists of frontal process of the maxilla, lacrimal bone, orbital plate of the ethmoidal bone and sphenoid body.

Orbit opens out that bordered supraorbital and infraorbital margins. Superior orbital fissure positioned between upper and lateral walls, inferior orbital fissure – lower and lateral walls.

Laterally one can find fossa for lacrimal gland. Infraorbital sulcus and canal are on the lower wall. Canal opens by infraorbital foramen in canine fossa on facial surface of the skull. Anterior and posterior ethmoid foramen are on medial orbital wall. Orbit communicates with skull cavity by the optic canals and nasal cavity – through nasolacrimal canal (on medial orbital wall).

*Bony cavity of the nose* opens forward by piriform aperture, backward connects nasopharynx through choanae. Nasal cavity has a superior, inferior, lateral and medial walls and it is separated by bony septum into right and left halves.

Lateral wall formed by:

- frontal process of the maxilla
- lacrimal bone
- ethmoidal labyrinth
- perpendicular plate of the palatine bone
- medial plate of the pterygoid process (sphenoid bone)

Upper wall (roof) formed by frontal bone and cribriform plate (ethmoid bone). Lower wall composed by bony palatine (palatine process of the maxilla and horizontal plate of the palatine bone).

Bony nasal septum consists of perpendicular plate (ethmoid bone) and vomer.

1. *Superior nasal meatus* passes between upper and middle nasal conchae (ethmoid bone) and communicates with sphenoid sinus through *sphenoethmoidal recess*. Posterior ethmoid cells open into superior nasal meatus

2. *Middle nasal meatus* runs between middle and lower nasal conchae and communicates with frontal (through ethmoid infundibulum) and maxillary (Haymory) sinus (through semilunar hiatus), and with anterior and middle ethmoid cells.

3. *Inferior nasal meatus* passes between lower nasal concha and bony palate; nasolacrimal canal and incisive canal open in it.

***Pterygopalatine fossa*** formed anteriorly by *maxillary tuber*, posteriorly by base of pterygoid process of the sphenoid bone and medially – by the perpendicular plate of the palatine bone. Pterygopalatine fossa communicates with internal cranial base through foramen rotundum, with orbit by inferior orbital fissura, with mouth cavity through greater and lesser palatine canals, with external cranial base (foramen lacerum) through pterygoid canal, and it communicates with nasal cavity through sphenopalatine foramen.

***Temporal fossa*** formed by frontal squama, temporal squama, greater wings of sphenoid bone and parietal bone. It bordered superiorly by inferior temporal line, inferiorly – infratemporal crest and zygomatic arch. Temporal fossa contains temporal muscle.

***Infratemporal fossa*** bordered anteriorly by tuber maxillae, superiorly – infratemporal crest, medially it continues into pterygopalatine fossa. Anteriorly infratemporal fossa communicates with orbit through inferior orbital fissura. Medially infratemporal fossa communicates with pterygopalatine fossa by pterygomaxillary fissura.

#### ***Peculiarities of foetal skull***

Anterior fontanelle positioned between unfused halves of the frontal bones. It is overgrown until 1 year old age. Posterior fontanelle located between parietal and occipital bones. It is overgrown till 2-3 months age. Mastoid fontanelle (paired) located between parietal, occipital and temporal bones. It is overgrown in last days before birth or during first 2-3 months. Sphenoid fontanelle (paired) located between frontal, parietal, sphenoid and temporal bones. It is overgrown in last week before birth or during first 2-3 months of life.

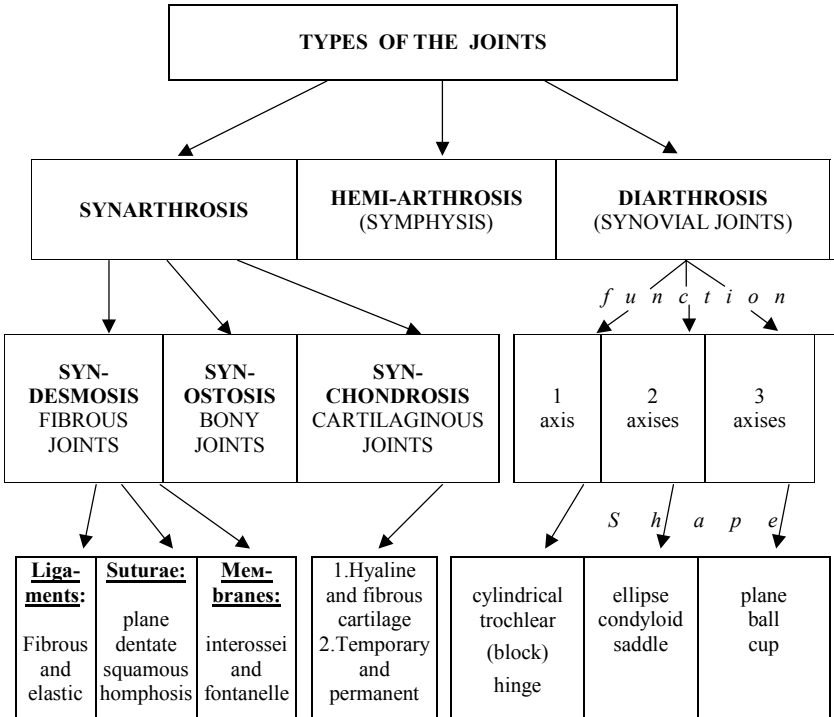
#### ***Obligatory structural elements of the synovial joints:***

1. Articular surfaces, covered by hyaline cartilage.
2. Articular capsule.
3. Articular cavity.
4. Synovia.

***Additional structures of the joints:*** ligaments, bursae, plicae, disks, meniscus, articular labium.

# Articulations

(ARTHROSYNDESMOLOGY)



According to the structure articulations are divided into:

1. simple joint – has only two articular surfaces;
2. compound joint – has more than two articular surfaces;
3. combined joint – some joints that move only together in the same time;
4. complex joint – has disks, meniscus or ligament that divide articular cavity into two floors.

## Articulations of the Vertebral Column

The articulations of the vertebral column consist of a series of fibrocartilages joints between the vertebral bodies, and a series of joints between the vertebral arches. Articulations of Vertebral Bodies: the individual vertebrae move only slightly on each other. When, however, this slight degree of movement between the pairs of bones takes place in all the joints of the vertebral column, the *total range of movement is very considerable*.

**The Intervertebral disks** are interposed between the adjacent surfaces of the bodies of the vertebrae, from the axis to the sacrum. In *shape* and *size* they correspond with the surfaces of the bodies between which they are placed, except in the cervical region, where they are slightly smaller from side to side than the corresponding bodies. In *thickness* they vary not only in the different regions of the column, but in different parts of the same fibrocartilage; they are thicker in front than behind in the cervical and lumbar regions, and thus contribute to the anterior convexities of these parts of the column; while they are of nearly uniform thickness in the thoracic region, the anterior concavity of this part of the column being almost entirely owing to the shape of the vertebral bodies. Each disc composed, at its circumference, of laminae of fibrous tissue and fibrocartilage, forming the *annulus fibrosus*; and, at its center, of a soft, pulpy, highly elastic substance, of a yellowish color, which projects considerably above the surrounding level when the disk is divided horizontally. This pulpy substance (*nucleus pulposus*), especially well-developed in the lumbar region, is the remains of the notochord. The intervertebral fibrocartilages are important shock absorbers. Under pressure the highly elastic nucleus pulposus becomes flatter and broader and pushes the more resistant fibrous laminae outward in all directions.

### **Thoracic cage as whole**

Thoracic cage composed by 12 thoracic vertebrae, 12 pairs of the ribs and sternum. Ribs are separated each other by intercostal spaces. Thoracic cage has superior and inferior apertures. Superior aperture bordered jugular sternal incisura, 1<sup>st</sup> rib and 1<sup>st</sup> vertebrae body. Inferior aperture bordered 12<sup>th</sup> vertebrae body, xiphoid process of the sternum and lower ribs. Anterolateral margin of the inferior aperture formed by joining of the 7<sup>th</sup>-10<sup>th</sup> ribs and named as costal arch. Right and left costal arches boundary substernal angle. Dorsally near thoracic vertebrae bodies are pulmonary grooves. Thoracic cage guards the internal organs: heart, lungs, trachea, esophagus etc.

### **Pelvis as whole**

	<b>Name</b>	<b>Shape</b>	<b>Type</b>	<b>Function</b>	<b>Axes of moving</b>
1.	Art. atlantooccipitalis	condyloid	combined	2 axes	frontal, sagittal
2.	Art. atlantoaxialis	1.Cylindrical 2.Plane	combined	1 axis	vertical
3.	Art. intervertebralis (zygapophysialis)	Plane	combined	3 axes	vertical frontal sagittal
4.	<b>COSTOVERTEBRAL ARTICULATION</b>				
5.	Art. capitis costae	ball (spherical)	combined compound complex	3 axes	sagittal
6.	Art. costotransversaria	cylindrical	combined	1 axis	frontal
7.	Art. sternocostalis	plane	simple 1 <sup>st</sup> rib - synchondrosis 2 <sup>nd</sup> complex	3 axes	vertical frontal sagittal
8.	Art. interchondrales				
9.	Art. sternoclavicularis	ball (spherical)	simple (complex)	3 axes	vertical frontal sagittal
10.	Art. acromioclavicularis	plane	simple (1/3 complex)	3 axes	vertical frontal sagittal
11.	Art. Humeri Shoulder joint	ball (spherical)	simple	3 axes	vertical frontal sagittal
12.	ART. CUBITI: ELBOW JOINT 1.Art. Humeroradialis+ 2.Art. Humeroulnaris+ 3.Art. Radioulnaris proximalis	hinge	compound	1 axis	frontal 1.frontal 2.frontal 3.vertical



	<b>Articular surfaces</b>	<b>Movement</b>	<b>Ligaments</b>
1.	Condili occipitales fovea art. superior atlantis	Bending forward, backward and laterally	membrana a.-o. anterior membrana a.-o. posterior
2.	fov. dentis atlantis facies art. anterior dentis facies art. posterior dentis fov. art. inferior atlantis fov. art. superior axis lig. transversum atlantis	rotation right and left	lig. transversum atlantis lig. cruciformis atlantis lig. apicis dentis ligg. alaria lig. flava membrana tectoria
3.	facies art. processus art. vertebrae superior facies art. processus art. vertebrae inferior	limited	lig. nuchae, lig. flava ligg. interspinalia lig. supraspinale ligg. intertransversaria ligg. longitudinales ant., post.
4.			
5.	facies art. capitis costae facies art. foveae costalis superior et inferior	lifting and descending of the ribs	lig. capitis costae intraarticulare lig. capitis costae radiatum
6.	facies art. tuberculi costae facies art. foveae costalis transversalis	lifting and descending of the ribs	ligamenta costotransversaria
7.	facies art. Incisurae costalis sterni extremitas sternalis cartilagini costalis	limited	lig. sternocostalis intraarticularis lig. sternocostalis radiatum
8.			membrana intercostalis externum membrana intercostalis internum
9.	facies art. Incisurae clavicularis sterni f. a. Extremitas sternalis clavicularae	lifting and descending forward-backward rotation	lig. sternoclaviculare anterius lig. sternoclaviculare posterius lig. interclavicularae lig. costoclavicularae
10.	f. a. Acromii f. a. Extremitas acromialis clavicularae	lifting descending	lig. acromioclaviculare lig. Trapezoideum + } + lig. conoideum lig. } =coracoclaviculare
11.	f. a. capitis humeri f. a. cavitatis glenoidales scapulae	flexion extension adduction and abduction rotation	lig. coracohumerale
12.	f. a. trochleae humeri f. a. capitis humeri f. a. incisurae trochlearis ulnae f. a. foveae capitis radii circumferentia articularis radii f. a. incisurae radialis ulnae	flexion extension	lig. collaterale ulnare lig. collaterale radiale lig. annulare radii lig. quadratum

	<b>Name</b>	<b>Shape</b>	<b>Type</b>	<b>Function</b>	<b>Axes of moving</b>
13.	Art. radioulnaris distalis	cylindrical.	combined	1 axis	vertical
14.	<b>ARTICULATIO MANUS</b>				
15.	Art. radiocarpea	ellipse	compound	2 axes	frontal sagittal
16.	Art. mediocarpea	combination of 2 balls	compound	1 axis	frontal
17.	Art. carpometacarpea	plane	compound	3 axes	-
18.	Art. intermetacarpea	plane	compound	3 axes	-
19.	Art. carpometacarpea pollicis	saddle	simple	2 axes	frontal sagittal
20.	Art. Metacarpophalangea	ball (spherical)	simple	2 axes	frontal sagittal
21.	Art. interphalangea	troccllear	simple	1 axis	frontal
22.	Art. sacroiliaca	plane	simple	3 axes	-
23.	Art. coxae	cup	simple	3 axes	vertical frontal sagittal

	<b>Articular surfaces</b>	<b>Movement</b>	<b>Ligaments</b>
13.	circumferentia articularis ulnae f. a. incisurae ulnaris radii g.	супінація пронація	membrana interossea
14.			
15.	f. a. Carpea radii discus triangularis f. a. Proximales ossis scaphoidei, lunati, triquetri	flexion extension adduction abduction circumduction	igg. intercarpeae ig. Collaterale carpi radiale ig. Collaterale carpi ulnare ig. Radiocarpeum palmare ig. Radiocarpeum dorsale
16.	f. a. ossea carpea	flexion extension	igg. Intercarpeae interossea igg. Intercarpeae dorsalia igg. Intercarpeae palmaria ig. carpi radiatum
17.	f. a. distales carpeal bones f. a. basis metacarpeal bones	limited	ig. carpometacarpea palmaria ig. carpometacarpea dorsalia ig. carpometacarpea interossea
18.	f. a. basis ossea metacarpea 2-5	limited	igg. metacarpea palmaria igg. metacarpea dorsalia ig. metacarpea interossea
19.	f. a. ossis trapezii f. a. basis ossis metacarpea I	flexion with opposition extension with reposition circumduction adductio, abduction	igg. carpometacarpeae pollicis palmaria igg. carpometacarpeae pollicis dorsalia
20.	f. a. distales ossis metacarpea f. a. basis falangis	flexion, extension, adduction, and abduction circumduction	igg. collateralia ig. palmare ig. metacarpea transversa profunda
21.	f. a. falangis	flexion extension	igg. collateralia igg. palmaria
22.	f. auricularis ossis sacri f. auricularis ossis ilii	limited	ig. sacroliaca interossea ig. sacroliaca ventralia ig. sacroliaca dorsalia ig. iliolumbale ig. sacrotuberale ig. sacrospinale
23.	f. a. capitis femoris f. lunatum acetabuli	flexion, extension adduction, rotation. circumduction	ig. iliofemorale ig. ischiofemorale ig. pubofemorale ig. capitis femoris lig. ligam. orbicularis ig. transversum acetabule

	Name	Shape	Type	Function	Axes of moving
24.	Art. genus	condyloid	complex	2 axes	frontal vertical when bended
25.	Art. Tibiofibularis proximal	plane	simple	3 axes	-
26.	Art. Talocruralis Ankle joint	trochlear	compound	1 axis	frontal
27.	Intertarseal articulations: Art. subtalaris	cylindrical	simple	1 axis	sagittal
28.	Art. Talocalcaneo-navicularis	ball	compound	3 axes	vertical frontal
29.	Art. calcaneo-cuboidea	plane	simple	3 axes	
30.	Art. cuneo-navicularis	plane.	Compound		
31.	29 + 30 = Art. tarsi transversa (Shonar's joint)				

	<b>Articular surfaces</b>	<b>Movement</b>	<b>Ligaments</b>
24.	f.a.inferior femoris f.a.superior tibiae f.a.patellaris femoris f.a.patellae <u>plicae</u> : 1.Plicae alares 2.Plicae synoviales, infrapatellaris	flexion, extension and rotation when bended	lig. transversum genus lig. collaterale tibiale lig. collaterale fibulare ligg. popliteum obliquum ligg. popliteum arcuatum retinacula pattellae laterale, mediale lig. patellae lig. cruciata anterius et posterius lig. meniscofemorale anterior lig. meniscofemorale posterior
25.	f.a.capitis fibulae f.a.fibularis tibiae	limited	ligg.capitis fibulae anterior et posterior
26.	f.a.tibiae inferior f.a.malleoli medialis f.a.malleoli lateralis f.a.superior trochlea f.a.medialis trochlea f.a. lateralis trochlea	Flexion, Extension, Lateral movements when bended	lig. mediale. Parts: 1. Tibionavicularis 2. Tibiocalcanea 3. Tibiotalaris anterior 4. Tibiotalaris posterior Lig.talofibulare anterius laterale Lig.talofibulare posterius laterale Lig.calcaneofibulare
27.	f.a.calcanei posterior tali f.a.posterior calcanei	supination with	lig. plantare longum
28.	f.a.calcanei anterior et medii tali et naviculare f.a.anterior et medii ossis calcanei f.a.posterior ossis navicularis	adduction and plantar flexion, pronation with abduction and dorsal flexion	lig. calcaneonaviculare plantare lig. talocalcaneum interossea lig. talocalcaneum med. lig. talocalcaneum lat.
29.	f.a.cuboiclea ossis calcanei f.a.posterior ossis cuboiclei		lig. talonaviculare lig. calcaneocuboideum plantare
30.	f. a. cuneidea ossis navicularis f. a. navicularis ossis cuneidei		
31.	f. a. cuboidea ossis calcanei, f. a. posterior ossis cuboidei f. a. navicularis tali, f. a. posterior ossis navicularis		lig. bifurcatum: lig.calcaneocuboideum + lig. calcaneonavicularis

	Name	Shape	Type	Function	Axes of moving
24.	Art. tarsometarsea (Lisfrank's joint)	plane.	compound	3 axes	-
25.	Artt. intermetatarseae	plane.	compound	3 axes	-
26.	Art. metatarsophalangea	ball	simple	3 axes	vertical frontal
27.	Art. interphalangea	trochlear	simple.	1-och	frontal
28.	Art. temporomandibularis	condyloid	combined complex	3 axes	vertical frontal sagittal

Hip and sacral bones that joined by sacroiliac joint and pubic symphysis form the pelvis which has upper and lower portions. Upper portion is major pelvis, lower is minor pelvis. Major pelvis separates from minor by terminal line that includes promontorium, arcuate line in iliac bones, pubic crests and upper margin of the symphysis. Major pelvis bordered posteriorly 5<sup>th</sup> lumbar vertebrae body, laterally – iliac alae. Minor pelvis formed by pubic and ischial bones, it has upper orifice (entrance) and lower orifice (exit). Obturator foramen closed by fibrous plate – obturator membrane. On lateral wall of the minor pelvis found greater and lesser sciatic foramen, that bordered by sacrospinal and sacrotuberal ligaments.

***Major pelvis has a transverse size:***

- spinarum distance (25-27 cm) between right and left superior anterior iliac spines;
- cristarum distance (28-29 cm) between widest points on right and left iliac crests;
- trochanteric distance (30-32 cm) between greater trochanters of the femurs.

***Minor pelvis has a size:***

	<b>Articular surfaces</b>	<b>Movement</b>	<b>Ligaments</b>
24.	f.a. on cuneiform and cuboid bones, f.a. metatarsal bones	limited	ligg. tarsometatarsae interossea ligg. tarsometatarsae mediale ligg. tarsometatarsae media ligg. tarsometatarsae laterale
25.		limited	ligg. metatarsae dorsalia et plantaria ligg. metatarsae interossea
26.	f.a. of the heads (tarsal bones), f.a of the bases (phalanges)	flexion,extension, slight abduction	ligg. Collateralia, ligg. plantaria lig. metatars. profundum transvers.
27.	f.a. on phalanges	flexion, extension	ligg. Collateralia ligg. Plantaria
28.	f. a. fossae mandibularis ossis temporalis f. a. capitis mandibulae	lifting-descending, forward-backward, right-left	lig. laterale, lig. Stylomandibularis

***Minor pelvis has a size:***

- straight size of the inlet (11 cm) between symphysis and promontorium;
- oblique size of the inlet (12 cm) between sacroiliac joint in one side and iliopubic eminence other side;
- transverse size of the inlet (13 cm) between the widest points of the terminal lines;
- straight size of the outlet from (9 cm) between apex coccyges and lower margin of the pubic symphysis;
- transverse size of the outlet (11 cm) between inner margins of the ischiadic tuber.

Straight size of the entrance to the minor pelvis in female named gynecological conjugate. Generally female has lower and wider pelvic than in male, promontorium extends forward not so much, therefore pelvic aperture more rounded. The sacral bone in female is wider and shorter and angle between inferior pubic rami is much 90°.

In vertical position of the body upper pelvic aperture bent forward with angle to the horizontal plane 55-60° in female and 50-55° in male.

*Conducting axis* of the lesser pelvis connects the middle points of all straight sizes. Normally conducting axis is the way for occipital fontanelle of the fetus during birth.

# MUSCULAR SYSTEM (MYOLOGY)

Muscles of the back subdivide into superficial and deep (proper) groups.

## *Superficial Back Musculature*

### **1. Trapezius**

- Origin:
  1. external occipital protuberance
  2. along the medial sides of the superior nuchal line
  3. ligamentum nuchae (surrounding the cervical spinous processes)
  4. spinous processes of C1-T12
- Insertion:
  1. posterior, lateral 1/3 of clavicle
  2. acromion
  3. superior spine of scapula
- Action:
  1. elevates scapula
  2. upward rotation of the scapula (upper fibers)
  3. downward rotation of the scapula (lower fibers)
  4. retracts scapula
- Blood: transverse cervical artery
- Nerve:
  1. spinal Accessory (XI) (efferent or motor fibers)
  2. ventral rami of C3 & C4 (afferent or sensory fibers)

### **2. Latissimus dorsi**

- Origin:
  1. spinous process of T7-L5
  2. upper 2-3 sacral segments
  3. iliac crest
  4. lower 3 or 4 Ribs
- Insertion: lateral lip of the intertubercular groove
- Action:
  1. adduction of humerus
  2. medial rotation of the humerus
  3. extension from flexed position
  4. downward rotation of the scapula
- Blood: thoracodorsal artery



- Nerve: thoracodorsal nerve, C6,7,8

### **3. Rhomboid major**

- Origin:
  1. spinous processes of T2-T5
  2. supraspinous ligament
- Insertion: medial scapula from the scapular spine to the inferior angle
- Action: retract scapula
- Blood:
  1. deep branch of transverse cervical artery, OR
  2. dorsal scapular artery
- Nerve: dorsal scapular nerve, C5

### **4. Rhomboid minor**

- Origin:
  1. spinous process of C7 & T1
  2. ligamentum nuchae
  3. supraspinous ligament
- Insertion: medial margin of the scapula at the medial angle
- Action: retract scapula
- Blood:
  1. deep branch of transverse cervical artery, OR
  2. dorsal scapular artery
- Nerve: dorsal scapular nerve, C5, [C4]

### **5. Levator scapulae**

- Origin: transverse processes of C1-C3 or C4
- Insertion: superior angle of scapula toward the scapular spine
- Action:
  1. elevates the scapula
  2. extends and/or laterally flexes the head
- Blood: transverse cervical artery
- Nerve:
  1. nerves off cervical plexus, C3,4
  2. dorsal scapular nerve, C5

### **6. Serratus posterior superior**

- Origin: vertebrae C7-Th2
- Insertion: 2-5 ribs
- Action:
  1. elevates ribs
- Blood:
  1. posterior intercostal art., deep cervical artery upper part

- Nerve: intercostal nerves, Th1-Th4

### **7. Serratus posterior inferior**

- Origin: vertebrae Th11-L2
- Insertion: 8-12 ribs
- Action:
  1. depresses the ribs
- Blood: posterior intercostal arteries
- Nerve: intercostal nerves, Th9-Th12

## ***Deep Back Musculature***

### **1. Splenius capitis**

- Origin:
  1. lower portion of ligamentum nuchae
  2. spinous processes of C3-T3(4)
- Insertion:
  1. superior nuchal line
  2. mastoid process of temporal bone
- Action:
  1. bilateral contraction: extend head & neck
  2. unilateral contraction: rotate and laterally bend head & neck to the contracted (same) side
- Blood: muscular branches of the aorta
- Nerve: dorsal rami of spinal nerves

### **2. Splenius cervicis**

- Origin: spinous process of T3-T6
- Insertion: posterior tubercles of transverse processes of C2-C4
- Action:
  1. bilateral contraction: extend head & neck
  2. unilateral contraction: rotate and laterally bend head & neck to the contracted (same) side
- Blood: muscular branches of the aorta
- Nerve: dorsal rami of spinal nerves

### **3. Erector Spinae Muscles:**

#### **Iliocostalis lumborum**

- Origin: common tendinous origin: (same for all lower erector spinae)
  1. sacrum
  2. iliac crest
  3. spinous processes of lower thoracic & most lumbar vertebrae

- Insertion: lower border of angles of ribs (5)6-12

- **Action: (same for all erector spinae)**

1. bilateral:

- a. extension of vertebral column
- b. maintenance of erect posture
- c. stabilization of vertebral column during flexion, acting in

contrast to abdominal muscles and the action of gravity

2. unilateral:

- a. lateral bend to same side
- b. rotation to same side
- c. opposite muscles contract eccentrically for stabilization

- Blood: muscular branches of the aorta

- Nerve: dorsal rami of spinal nerves

### **Iliocostalis thoracis**

- Origin: upper border of ribs 6-12 (medial to I. lumborum's insertion.)

- Insertion: lower border of angles of ribs 1-6 (sometimes transverse process of C7)

- Action: (same for all erector spinae)

- Blood: muscular branches of the aorta

- Nerve: dorsal rami of spinal nerves

### **Iliocostalis cervicis**

- Origin: angles of ribs 1-6

- Insertion: transverse processes of C4-C6

- Action: (same for all erector spinae)

- Blood: muscular branches of the aorta

- Nerve: dorsal rami of spinal nerves

### **Longissimus thoracis**

- Origin: common tendinous origin: (same for all lower erector spinae)

1. sacrum

2. iliac crest

3. spinous processes of lower thoracic & most lumbar vertebrae

- Insertion:

1. transverse processes of all thoracic vertebrae

2. all ribs between tubercles and angles

3. transverse processes of upper lumbar vertebrae

- Action: (same for all erector spinae)

1. bilateral:

- a. extension of vertebral column

- b. maintenance of erect posture (pneumonic = I Like Standing)

c. stabilization of vertebral column during flexion, acting in contrast to abdominal muscles and the action of gravity

2. unilateral:

a. lateral bend to same side

b. rotation to same side

c. opposite muscles contract eccentrically for stabilization

• Blood: muscular branches of the aorta

• Nerve: dorsal rami of spinal nerves

### **Longissimus cervicis**

• Origin: transverse processes of T1-T5(6)

• Insertion: transverse processes of C2-C6

• Action: (same for all erector spinae)

• Blood: muscular branches of the aorta

• Nerve: dorsal rami of spinal nerves

### **Longissimus capitis**

• Origin:

1. transverse and articular processes of middle and lower cervical vertebrae

2. transverse processes of upper thoracic vertebrae

• Insertion: posterior aspect of mastoid process of temporal bone

• Action: (same for all erector spinae)

• Blood: muscular branches of the aorta

• Nerve: dorsal rami of spinal nerves

### **Spinalis thoracis**

• Origin: common tendinous origin: (same for all lower erector spinae)

1. sacrum

2. iliac crest

3. spinous processes of lower thoracic & most lumbar vertebrae

• Insertion: spinous processes T3(4)-T8(9)

• Action: (same for all erector spinae)

1. bilateral:

a. extension of vertebral column

b. maintenance of erect posture (pneumonic = I Like Standing)

c. stabilization of vertebral column during flexion, acting in

contrast to abdominal muscles and the action of gravity

2. unilateral:

a. lateral bend to same side

b. rotation to same side

c. opposite muscles contract eccentrically for stabilization

- Blood: muscular branches of the aorta
- Nerve: dorsal rami of spinal nerves

### **Spinalis cervicis**

- Origin: spinous processes of C6-T2
- Insertion: spinous processes of C2 (and possibly extend to C3 or C4)
- Action: (same for all erector spinae)
- Blood: muscular branches of the aorta
- Nerve: dorsal rami of spinal nerves

### **Spinalis capitis**

- Origin: spinous processes of lower cervical & upper thoracic vertebrae
- Insertion: between superior & inferior nuchal lines of occipital bone
- Action: (same for all erector spinae)
- Blood: muscular branches of the aorta
- Nerve: dorsal rami of spinal nerves

## **4. Transversospinal Muscles**

### **Semispinalis thoracis**

- Origin: transverse processes of T6-T12 vertebrae
- Insertion: spinous processes of upper thoracic & lower cervical vertebrae
- Action:
  1. bilaterally extends vertebral column, especially head and neck
  2. controls lateral flexion to side opposite contraction (eccentric for stability)
  3. maintains head posture
- Blood: muscular branches of the aorta
- Nerve: dorsal rami of spinal nerves

### **Semispinalis cervicis**

- Origin: transverse processes of T1-T6 vertebrae and can go down to lower thoracic
- Insertion: spinous processes of C2-T5(6)
- Action:
  1. bilaterally extends vertebral column, especially head and neck
  2. controls lateral flexion to side opposite contraction (eccentric for stability)
  3. maintains head posture
- Blood: muscular branches of the aorta
- Nerve: dorsal rami of spinal nerves

### **Semispinalis capitis**

- Origin:
  1. transverse processes of T1-T6

- 2. articular processes of C4-C7
- Insertion: between superior & inferior nuchal lines of occipital bone
- Action:
  1. bilaterally extends vertebral column, especially head and neck
  2. controls lateral flexion to side opposite contraction (eccentric for stability)
  3. maintains head posture
- Blood: muscular branches of the aorta
- Nerve: dorsal rami of spinal nerves

### **Multifidus**

- Origin:
  - cervical region: from articular processes of lower cervical vertebrae
  - thoracic region: from transverse processes of all thoracic vertebrae
  - lumbar region:
    1. lower portion of dorsal sacrum
    2. PSIS
    3. deep surface of tendinous origin of erector spinae
    4. mamillary processes of all lumbar vertebrae
- Insertion: spinous process of all vertebrae extending from L5 – C2 (skipping 1-3 segments)
- Action:
  1. bilaterally extends vertebral column
  2. controls lateral flexion to side opposite contraction (eccentric for stability)
  3. unilaterally rotate vertebral bodies (column) to opposite side
- Blood: muscular branches of the aorta
- Nerve: dorsal rami of spinal nerves

### **Long rotators**

- Origin: transverse process of one vertebra
- Insertion: skips one vertebra to insert on the base of spinous process of vertebra above
- Action:
  1. rotate to opposite side
  2. bilateral extension
- Blood: muscular branches of the aorta
- Nerve: dorsal rami of spinal nerves

### **Short rotators**

- Origin: transverse process of one vertebra
- Insertion: base of spinous process of vertebra immediately above

- Action:
  1. rotate to opposite side
  2. bilateral extension
- Blood: muscular branches of the aorta
- Nerve: dorsal rami of spinal nerves

## **Segmental Muscles:**

### **5. Interspinalis**

- Origin: spinous processes of each vertebra
- Insertion: to the spinous process of vertebra immediately above
- Action: extension of the vertebrae segments
- Blood: muscular branches of the aorta
- Nerve: dorsal rami of spinal nerves

### **6. Intertransversi**

- Origin: (A to A and B to B)
- cervical region:
  - A. from the anterior tubercle of transverse process
  - B. from the posterior tubercle of transverse process
- thoracic region: (poorly developed)
- lumbar region:
  - A. lateral aspect of the transverse process
  - B. mamillary process
- Insertion:
- cervical region:
  - to the anterior tubercle immediately above
  - to the posterior tubercle immediately above
- thoracic region: (poorly developed)
- lumber region:
  - lateral aspect of the transverse process immediately above
  - B. to the accessory process on the vertebra immediately above
- Action:
  1. laterally flexes each respective pair of vertebrae
  2. (also eccentric muscle contraction provides stability)
- Blood: muscular branches of the aorta
- Nerve: dorsal rami of spinal nerves

### **7. Levators costarum (short and long)**

- Origin: cervical and thoracic vertebrae
- Insertion: ribs
- Action: elevates ribs

- Blood: posterior intercostal arteries
- Nerve: intercostal nerves, C8 – Th1-Th10

## **8. Suboccipital Musculature**

### *Obliquus capitis inferior*

• Origin: spinous process of axis (C2) • Insertion: transverse process of atlas (C1) • Action: rotates the head to the contracted side • Blood: muscular branches of vertebral artery • Nerve: suboccipital nerve, (dorsal rami C1)

### *Obliquus capitis superior*

• Origin: transverse process of atlas (C1) • Insertion: between superior and inferior nuchal line of occiput  
 • Action: 1. bilaterally extends the head 2. laterally flexes to the contracted side  
 • Blood: muscular branches of vertebral artery • Nerve: suboccipital nerve, (dorsal rami C1)

### *Rectus capitis posterior major*

• Origin: spinous process of axis (C2) • Insertion: inferior nuchal line (lateral to minor) • Action:  
 1. bilaterally extends the head 2. rotates the head to the contracted side  
 • Blood: muscular branches of vertebral artery • Nerve: suboccipital nerve, (dorsal rami C1)

### *Rectus capitis posterior minor*

• Origin: posterior tubercle of atlas (C1) • Insertion: inferior nuchal line (adjacent to midline) • Action: bilaterally extends the head • Blood: muscular branches of vertebral artery • Nerve: suboccipital nerve, (dorsal rami C1)

They differ some regions in back: vertebral region, sacral region, scapular region, subscapular region, and lumbar region.

**Muscles of the thorax** subdivide into superficial and proper (deep) groups.

### *Pectoral Musculature*

#### **1. Pectoralis major**

- Origin:
  1. medial 1/3 of clavicle



2. anterior aspect of manubrium & length of body of sternum
  3. cartilaginous attachments of upper 6 ribs
  4. external oblique's aponeurosis
- Insertion:
    1. lateral lip of bicipital groove to the crest of the greater tubercle
    2. clavicular fibers insert more distally; sternal fibers more proximally
  - Action:
    1. adducts humerus
    2. medially rotates humerus
    3. flexion of the arm from extension (clavicular portion)
  - Blood:
    1. pectoralis branch of thoracoacromial artery (runs with lateral pec. nerve)
    2. lateral thoracic artery (lesser supply, and runs with medial pectoral nerve)
  - Nerve:
    1. lateral pectoral nerve, C5,6,7 to clavicular portion
    2. medial pectoral nerve, C8,T1 to sternal portion

## 2. Pectoralis minor

- Origin: outer surface of ribs 2-5 or 3-5 or 6
- Insertion: medial aspect of coracoid process of the scapula
- Action:
  1. depresses & downwardly rotates the scapula
  2. assists in scapular protraction from a retracted position
  3. stabilizes the scapula
- Blood: lateral thoracic artery
- Nerve: medial pectoral nerve, C8,T1

## 3. Subclavius

- Origin: first rib about the junction of bone and cartilage
- Insertion: lower surface of clavicle
- Action: assists in stabilizing the clavicle
- Blood: clavicular branch of thoracoacromial artery
- Nerve: nerve to the subclavius, C5,6

## 4. Serratus anterior

- Origin: fleshy slips from the outer surface of upper 8 or 9 ribs
- Insertion: costal aspect of medial margin of the scapula
- Action:
  1. protract scapula
  2. stabilize scapula

3. assists in upward rotation
- Blood:
    1. lateral thoracic artery supplies the upper part
    2. thoracodorsal artery supplies the lower part
  - Nerve: long thoracic nerve, C5,6,7

Follow muscles belong to ***Proper (deep) group of the thorax:***

1. External intercostal muscles elevate the ribs
2. Internal intercostal muscles lower ribs
3. Subcostal muscles lower the ribs
4. Transversus thoracis muscles lower the ribs
5. Levators costarum (short and long). They originate from cervical and thoracic vertebrae, insert to ribs. Action: elevates ribs.

**Diaphragm** – muscular and tendon organ that separates thoracic and abdominal cavities. It has muscular portion and the tendon. Muscular part is divided into three parts: sternal part, costal and lumbar parts. There are weak places where diaphragmatic hernia can be happen – *lubocostal* and *sternocostal triangles*. The diaphragm is the dome-shaped sheet of muscle that separates the chest from the abdomen. It is attached to the spine, ribs and sternum and plays a very important role in the breathing process. The lungs are enclosed in a kind of cage in which the ribs form the sides and the diaphragm, an upwardly arching sheet of muscle, forms the floor. When we breathe, the diaphragm is drawn downward until it is flat. At the same time, the muscles around the ribs pull them up like a hoop skirt. The chest cavity becomes deeper and larger, making more air space. The muscle fibers of the diaphragm converge on the **central tendon**, which is a thick, flat plate of dense fibers. There are openings in the diaphragm for the esophagus (*esophageal hiatus*), the phrenic nerve (which controls the movements of the diaphragm to produce breathing), and the aorta (*aortic hiatus*) and vena cava blood vessels (*foramen venae cavae inferioris*), which lead to and from the heart. When air is drawn into the lungs, the muscles in the diaphragm contract, pulling the central tendon down. This enlarges the chest, and air then passes into the lungs to fill the larger space. The diaphragm sometimes contracts involuntarily because the controlling nerves are irritated by eating too fast (or for some other reason). At this time, if air is inhaled, the space between the vocal cords at the back of the throat close suddenly, producing the clicking noise we call “hiccups.”

### **Breathing**

The **diaphragm** contracts and moves downward elongating the thoracic cavity while the **external intercostal muscles** contract widening the thoracic cavity causing air to fill the lungs through suction (*inspiration*). The diaphragm and external intercostal then relax, decreasing the thorax size and reducing lung capacity forcing air out of the lungs (*expiration*).

### **Muscles and Fasciae of the Abdomen**

The muscles of the abdomen may be divided into three groups: (1) the **anterior**; (2) the **lateral muscles**; (3) the **posterior muscles**.

Muscles of *anterior* abdominal wall

1. **Rectus abdominis** is a long flat muscle, which extends along the whole length of the front of the abdomen, and is separated from its fellow of the opposite side by the *linea alba*. The Rectus is crossed by fibrous bands, three in number, which are named the **tendinous interseptions**. **Action** – **Rectus** pulls ribs downward, bend the backbone, takes part in ‘prelum abdominale’.

2. The **Pyramidalis** pulls the linea alba.

*Lateral* abdominal muscles include: Obliquus externus abdominis, Obliquus internus abdominis, Transversus abdominis.

1. The **external abdominal oblique muscle** lies on the sides and front of the abdomen and is the largest and the most superficial of the three flat muscles in this area. It is broad, thin and irregularly four-sided and occupies the lateral walls of the abdomen, stretching across to the front. Both sides, acting together, flex the vertebral column by *drawing the pubis toward the xiphoid process*. One side also bends the vertebral column sideways and rotates it to opposite direction.

2. The **internal abdominal oblique muscle** is also irregularly four-sided in form and lies under the external oblique muscle. Both sides, acting together, flex the vertebral column, drawing cartilages down toward the pubis. One side acting alone bends the vertebral column sideways, rotating it to the same direction. Both of the abdominal oblique muscles work to compress abdominal contents, assist in the digestive process and in forced expiration.

3. The **transversus abdominal muscle** compresses the abdominal viscera.

**Actions.** When the pelvis and thorax are fixed, the **abdominal muscles** *compress the abdominal viscera* by constricting the cavity of the abdomen, in which action they are materially assisted by the descent of the diaphragm. By these means assistance is given in expelling the feces

from the rectum, the urine from the bladder, the fetus from the uterus, and the contents of the stomach in vomiting.

If the pelvis and vertebral column were fixed, these muscles compress the lower part of the thorax, materially *assisting expiration*. If the pelvis alone be fixed, the thorax is bent directly forward, when the muscles of both sides act; when the muscles of only one side contract, the trunk is bent toward that side and *rotated* toward the opposite side.

If the thorax be fixed, the muscles, acting together, *draw the pelvis upward*, as in climbing; or, acting singly, they draw the pelvis upward, and *bend the vertebral column to one side or the other*. The Recti, acting from below, *depress the thorax*, and consequently *flex the vertebral column*; when acting from above, they flex the pelvis upon the vertebral column. The Pyramidales are tensors of the linea alba.

### **The Posterior Muscles of the Abdomen**

The **Quadratus lumborum** is irregularly quadrilateral in shape, and broader below than above. It *arises* by aponeurotic fibers from the iliolumbar ligament and the adjacent portion of the iliac crest for about 5 cm., and is *inserted* into the lower border of the last rib.

In front of the Quadratus lumborum are the colon, the kidney.

**Actions.** The Quadratus lumborum draws down the last rib, and acts as a muscle of inspiration by helping to fix the origin of the diaphragm. If the thorax and vertebral column are fixed, it may act upon the pelvis, raising it toward its own side when only one muscle is put in action; and when both muscles act together, either from below or above, they straighten the trunk.

In the middle line aponeurosis of the opposite obliqui muscles and transversus abdominis muscles form the **linea alba**, which extends from the xiphoid process to the symphysis pubis. Linea alba is the place of middle section (laparotomy).

### **Sheath of rectus abdominis muscle**

The Rectus is enclosed in a **sheath** (vagina for rectus abdominis) formed by the aponeuroses of the Obliqui and Transversus, which are arranged in the following manner. At the lateral margin of the Rectus, the aponeurosis of the Obliquus internus divides into *two lamellæ*, one of which passes in front of the Rectus, blending with the aponeurosis of the Obliquus externus, the other, behind it, blending with the aponeurosis of the Transversus, and these, joining again at the medial border of the Rectus, are inserted into the **linea alba**. This arrangement of the aponeurosis exists

from the costal margin to midway between the umbilicus and symphysis pubis, where the posterior wall of the sheath ends in a thin curved margin, the **linea arcuata**, the concavity of which is directed downward: *below* this level the aponeuroses of all three muscles pass in front of the Rectus. The Rectus, in the situation where its sheath is deficient below, is separated from the peritoneum by the *transversalis fascia*.

### **Inguinal canal**

**Inguinal ligament** is formed by lower margin of external oblique abdominis muscle. It fixed between anterior superior iliac spine and pubic tubercle in each side. A ligament is a tough band of white, fibrous, rather elastic tissue. Ligaments support many internal organs; including the uterus, the bladder, the liver, and the diaphragm. The inguinal ligament supports the region around the groin (between the abdomen and the thigh), preventing an inguinal hernia, or protrusion of part of the intestine into the muscles of the groin. **Inguinal canal** exists at norm, length 4-5 cm. It located above the inguinal ligament. Inguinal canal in male contains spermatic cord, in female – round ligament of uterus. Anterior wall of the canal is formed by aponeurosis of external oblique abdominis muscle, lower wall – by inguinal ligament, back wall – by transversalis fascia, upper wall – by lower margin of internal oblique and transversus abdominis muscles. Inguinal canal has two rings. *Superficial inguinal annulus* enclosed by *medial* and *lateral crura* of aponeurosis of external oblique abdominis muscle, *intercrural fibbers* and *reflected ligament*. *Deep inguinal annulus* is formed by convexity of *transversalis fascia*. Inguinal rings, also linea alba, umbilical ring are weak places of the front abdominal wall, where hernia can look out.

### **Fossae and folds on back surface of front abdominal wall**

Back surface of front abdominal wall is covered by parietal sheet of peritoneum and carries unpaired *median umbilical fold (plicae)* and paired – *medial* and *lateral umbilical folds (plicae)*. *Medial umbilical fossa* projected into superficial inguinal ring, which positioned between medial and lateral umbilical folds. Straight inguinal herniae can pass through this fossa. *Lateral umbilical fossa* placed laterally from lateral umbilical fold. It answers the deep inguinal ring and during pathologic cases can contain oblique inguinal herniae. There is *supravesical fossa* between median and medial umbilical folds.

They differ some **REGIONS IN ABDOMEN**:

*In Epigastrium (upper floor) –*

Right Hypochondriac Epigastric, Left Hypochondriac regions

*In Mesogastrium (middle floor) –*

Right Lateral, Umbilical and Left Lateral regions

*In Hypogastrium (lower floor) –*

Right Inguinal, Pubic and Left Inguinal regions

## **Muscles of the Head subdivided into Mastication and Facial Expression (mimetic) groups**

### **Muscles of Mastication**

#### **Masseter**

- Origin:
  - Superficial:
    1. zygomatic process of the maxilla
    2. inferior border of zygomatic arch
  - Intermediate: inner surface of zygomatic arch
  - Deep: posterior aspect of inferior border of zygomatic arch
- Insertion:
  - Superficial:
    1. angle of mandible
    2. lateral surface of mandibular ramus
  - Intermediate: ramus of mandible
  - Deep:
    1. superior ramus of mandible
    2. coronoid process of mandible
- Action:
  1. closes the lower jaw (clenches the teeth)
  2. may deviate mandible to opposite side of contraction
- Blood: masseteric artery
- Nerve: masseteric nerve

#### **Medial pterygoid**

- Origin:
  1. medial surface of lateral pterygoid plate of the sphenoid
  2. palatine bone
  3. pterygoid fossa
- Insertion:
  1. inner surface of mandibular ramus
  2. angle of the mandible
- Action:
  1. closes the lower jaw (clenches the teeth)
  2. can protrude the mandible in combination with the lateral pterygoid
- Blood: medial pterygoid artery
- Nerve: medial pterygoid nerve

#### **Lateral pterygoid**

- Origin:

1. Superior head: lateral surface of the greater wing of the sphenoid
  2. Inferior head: lateral surface of the lateral pterygoid plate
- Insert together:
    1. neck of the mandibular condyle
    2. articular disk of the TMJ
  - Action:
    1. deviates mandible to side opposite of contraction (during chewing)
    2. opens mouth by protruding mandible (inferior head)
    3. closes the mandible (superior head)
  - Blood: lateral pterygoid artery • Nerve: lateral pterygoid nerve

### **Temporalis**

- Origin:
- Temporal fossa
- Insertion: coronoid process of the mandible
- Action:
  1. closes the lower jaw (clenches the teeth)
  2. retraction, pulls back

**Muscles of *Facial Expression*** (mimetic muscles) have such peculiarities:

1. Originate in bones of face and insert into skin
2. Do not throw over joints
3. Do not have proper fasciae (exception is buccinator muscle)
4. Placed round natural orifices of the face (eyes, nostrils, ears and mouth)
5. They have an antagonists – elastic skin

**Muscles of *Facial Expression*** (mimetic)

### **Orbicularis oculi**

- Origin:
  1. orbital portion: nasal process of frontal bone
  2. palpebral portion: palpebral ligament
  3. lacrimal portion: lacrimal crest of lacrimal bone
- Insertion: circumferentially around orbit meeting in palpebral raphe
- Action: powerfully closes the eye
- Blood: ophthalmic artery
- Nerve: zygomatic branch of facial nerve

### **Corrugator supercillii**

- Origin: frontal bone just above the nose
- Insertion: skin of the medial portion of the eyebrows
- Action: draws the eyebrows downward and medially
- Blood: ophthalmic artery



- Nerve: zygomatic branch of facial nerve

### **Orbicularis oris**

- Origin:
  1. alveolar border of maxilla
  2. lateral to midline of mandible
- Insertion:
  1. circumferentially around mouth
  2. blends with other muscles
- Action:
  1. closes the lips
  2. protrudes the lips
- Blood: facial artery
- Nerve: buccal branch of facial nerve

### **Levator labii superioris**

- Action:
  1. elevates the upper lip
  2. flares the nostrils

### **Zygomaticus minor**

- Action: elevates the upper lip

### **Zygomaticus major**

- Action: lifts and draws back the angle(s) of the mouth (as in smiling)

### **Risorius (may be absent)**

- Action: draws the mouth laterally (as in smiling)

### **Levator anguli oris**

- Action: lifts the angle(s) of the mouth (as in smiling)

### **Buccinator**

- Action: compresses the cheek(s)

### **Depressor anguli oris**

- Action: lowers the angle(s) of the mouth (as in frowning)

### **Depressor labii inferioris**

- Action: draws the lower lip downward and laterally

### **Epicranial Musculature**

#### **Occipitalis (2 bellies)**

- Origin:
  1. lateral 2/3 of superior nuchal line
  2. external occipital protuberance
- Insertion: galea aponeurosis, over the occipital bone
- Action: draws back the scalp to raise the eyebrows and wrinkle the brow
- Blood: occipital artery

- Nerve: posterior auricular branch of facial nerve

### **Frontalis (2 bellies)**

- Origin: galea aponeurosis, anterior to the vertex
- Insertion: skin above the nose and eyes
- Action: draws back the scalp to raise the eyebrows and wrinkle the brow
- Blood: ophthalmic artery
- Nerve: temporal branch of facial nerve

### **Anterior, posterior and superior auricularis muscles**

- Action: draws the auricle

There are *parotid fascia*, *masseteric fascia* and *buccopharyngeal fascia* in head region.

*Regions of head:* frontal, parietal, occipital, temporal, auditory, mastoid and facial regions. Facial area has orbital, infraorbital, parotido-masseteric, zygomatic, nasal, oral and mental regions.

## **NECK MUSCULATURE**

### **SUBDIVIDES INTO SUPERFICIAL AND DEEP GROUPS**

#### **Superficial Neck Musculature**

##### **Platysma**

• Origin: subcutaneous skin over delto-pectoral region • Insertion: invests in the skin widely over the mandible • Action: 1. depress mandible and lower lip 2. tenses the skin over the lower neck

• Blood: superficial vessels of the neck • Nerve: cervical branch of facial nerve (VII cranial)

##### **Sternocleidomastoid**

- Origin: (two heads)

1. manubrium of sternum
2. medial portion of clavicle

- Insertion: mastoid process of temporal bone • Action:

1. rotates to side opposite of contraction
2. laterally flexes to the contracted side
3. bilaterally flexes the neck

- Blood:

1. occipital artery
2. superior thyroid artery

- Nerve:

1. motor: spinal accessory (XI cranial)
2. sensory: ventral rami of C2, (C3)

## **Suprahyoid group**

### 1. Stylohyoid

• Origin: styloid process of temporal bone • Insertion: lateral margin of hyoid (near greater horn) • Action:

1. pulls the hyoid superiorly & posteriorly during swallowing
2. fixes the hyoid bone for infrahyoid action

• Blood: facial & occipital artery • Nerve: facial nerve (VII cranial)

## **Digastric**

• Attachments:

1. post belly: mastoid process of temporal bone
2. anterior belly: digastric fossa of internal mandible

• both bellies meet and attach at the lateral aspect of body of hyoid by a pulley tendon • Action:

1. open mouth by depressing mandible
2. fixes hyoid bone for infrahyoid action

• Blood: branches of the external carotid • Nerve:

1. posterior belly: facial nerve (VII cranial)
2. anterior belly: mylohyoid nerve

## **Mylohyoid**

• Origin: inner surface of mandible off the mylohyoid line • Insertion:

1. body of hyoid
2. along midline at mylohyoid raphe

• Action:

1. elevates the hyoid bone
2. raises floor of mouth (for swallowing)
3. depresses mandible when hyoid is fixed

• Blood: lingual artery

• Nerve: mylohyoid nerve (branch of mandibular division, V3 cranial)

## **Geniohyoid**

• Origin: inner surface of the mandible

• Insertion: body of hyoid (paired muscles)

• Action:

1. pulls the tongue
2. depress the mandible
3. works with mylohyoid

• Blood: lingual artery

• Nerve:

## **Infrahyoid group**

### 1. Sternohyoid

- Origin:
  1. posterior aspect of manubrium
  2. sternal end of clavicle
- Insertion: body of hyoid • Action:
  1. depresses hyoid & larynx
  2. acts eccentrically with the suprahyoid muscles to provide them a stable base
- Blood:
  1. inferior thyroid artery (primary)
  2. superior thyroid artery
- Nerve:
  1. upper portions: superior root of ansa cervicalis, C2
  2. lower portions: inferior root of ansa cervicalis, C2,3

### **Omohyoid**

- Attachments:
  1. superior belly: hyoid bone (lateral to sternohyoid)
  2. inferior belly: superior scapular border (medial to suprascapular notch)
- both bellies meet at the clavicle & are held to the clavicle by a pulley tendon • Action:
  1. depresses hyoid & larynx
  2. acts eccentrically with the suprahyoid muscles to provide them a stable base
- Blood:
  1. inferior thyroid artery (primary)
  2. superior thyroid artery
- Nerve:
  1. upper portions: superior root of ansa cervicalis, C2
  2. lower portions: inferior root of ansa cervicalis, C2,3

### **Sternothyroid**

- Origin: posterior aspect of manubrium
- Insertion: oblique line of thyroid cartilage
- Action:
  1. depresses hyoid & larynx
  2. acts eccentrically with the suprahyoid muscles to provide them a stable base
- Blood:
  1. inferior thyroid artery (primary)
  2. superior thyroid artery
- Nerve:

1. upper portions: superior root of ansa cervicalis, C2
2. lower portions: inferior root of ansa cervicalis, C2,3

### **Thyrohyoid**

- Origin: oblique line of thyroid cartilage
- Insertion: body of hyoid
- Action:
  1. depresses hyoid
  2. may assist in larynx elevation
- Blood:
  1. inferior thyroid artery (primary)
  2. superior thyroid artery
- Nerve:
  1. upper portions: superior root of ansa cervicalis, C2
  2. lower portions: inferior root of ansa cervicalis, C2,3

**Deep Neck Muscles** have **lateral, medial** groups

### **Deep Lateral Neck Musculature**

#### **Anterior scalene**

- Attachment A: anterior tubercles of transverse processes of C3-C6
- Attachment B: 1st rib
- Action:
  - if transverse process fixed: 1. elevates the ribs for respiration
  - if ribs fixed: 2. rotates to side opposite of contraction
  3. laterally flexes to the contracted side
  4. bilaterally flexes the neck
- Blood: inferior thyroid artery (branch of the thyrocervical trunk)
- Nerve: ventral rami C3-C6

#### **Middle scalene**

- Attachment A: transverse processes of all cervical vertebrae
- Attachment B: 1st rib (behind anterior scalene)
- Action:
  - if transverse process fixed: 1. elevates the ribs for respiration
  - if ribs fixed: 2. rotates to side opposite of contraction
  3. laterally flexes to the contracted side
  4. bilaterally flexes the neck
- Blood: ascending cervical artery
- Nerve: ventral rami C3-C8

## **Posterior scalene**

- Attachment A: posterior tubercles of transverse processes of C5 & C6
- Attachment B: 2nd and/or 3rd rib
- Action:
  - if transverse process fixed: 1.elevates the ribs for respiration
  - if ribs fixed: 2.rotates to side opposite of contraction
  - 3.laterally flexes to the contracted side 4.bilaterally flexes the neck
- Blood: ascending cervical artery
- Nerve: ventral rami C5-C7

## **Neck prevertebral deep Musculature**

### **Longus colli**

- Origin: lower anterior vertebral bodies and transverse processes
- Insertion: anterior vertebral bodies and transverse processes several segments above
- Action: flexes the head and neck
- Blood: muscular branches of the aorta
- Nerve: ventral rami C2-C6

### **Longus capitis**

- Origin: upper anterior vertebral bodies and transverse processes
- Insertion: anterior vertebral bodies and transverse processes several segments above
- Action: flexes the head and neck
- Blood: muscular branches of the aorta
- Nerve: ventral rami C1-C3

### **Rectus capitis anterior**

- Origin: anterior base of the transverse process of the atlas
- Insertion: occipital bone anterior to foramen magnum
- Action: flexes the head
- Blood: muscular branches of the aorta
- Nerve: ventral rami C2,3

### **Rectus capitis lateralis**

- Origin: transverse process of the atlas
- Insertion: jugular process of the occipital bone
- Action: bends the head laterally
- Blood: muscular branches of the aorta
- Nerve: ventral rami C2,3

## **Topography of the neck**

### **Neck has follow regions:**

Anterior region is bordered overhead by lower margin of mandible, from below by sternum, from one side – by the sternocleidomastoid muscle. Median line of the neck divides anterior region into *right* and *left anterior triangles*. There are some areas in each triangle:

**1. Submandibular trigone** bordered by lower margin of mandible and both bellies of digastric muscle

2. There is **lingual trigone of Pyrohov** in Submandibular triangle that bordered by back margin of mylohyoid muscle, tendon of posterior belly of digastric muscle and hypoglossal nerve. There is lingual artery in this triangle.

3. **Carotid trigone** bordered by posterior belly of digastric muscle, superior belly of omohyoid, anterior margin of the sternocleidomastoid and linea alba of the neck.

4. Muscular (omotracheal) trigone bordered by superior belly of omohyoid, anterior margin of the sternocleidomastoid and linea alba of the neck.

5. **Mental trigone** bordered by anterior bellies of both digastric muscles, hyoid bone and mandible.

**Sternocleidomastoid region** answers the projection of the same name muscle.

Lateral region of the neck is bordered by back margin of the sternocleido-mastoid, anterior margin of the trapezius muscle and upper margin of clavicle. There are follow areas in this region:

1. Omo-trapezial trigone is bordered by back margin of the sternocleidomastoid, lower belly of omohyoid and anterior margin of the trapezius muscles.

2. Omo-clavicular (greater supraclavicular) trigone of neck is bordered by back margin of the sternocleidomastoid, lower belly of omohyoid and upper margin of the clavicle.

Posterior region answers the projection of the trapezius muscle.

## **Cervical fascia**

According V.M.Shevkunenko there are 5 cervical fasciae:

I – **superficial cervical** fascia envelops the platizma

Proper cervical fascia has two sheets:

II – **superficial lamina** of the proper cervical fasciae starts from front surface of the sternum and clavicle, lower margin of mandible and attaches the spinous processes of the cervical vertebrae. It forms the sheath for sternocleidomastoid and trapezius muscles.

III – **deep lamina** of the proper cervical fasciae starts from back surface of the sternum and clavicle and attaches to the hyoid bone from sides bordered by omohyoid muscles. This fascia forms linea alba of neck and the sheath for infrahyoid muscles.

**Suprasternal interaponeurotic space** made up between superficial and deep lamina of the proper cervical fasciae. It contains jugular venous

arch and fat tissue. Suprasternal space connects with lateral recesses located behind the lower part of sternocleidomastoid muscle.

IV – **internal cervical fascia** subdivides into *parietal* and *visceral* sheets. Parietal lamina envelopes all organs of neck together and visceral – each organ separately. **Previsceral space** positioned between parietal and visceral laminae and contains adipose tissue, lymphatic nodes, and nerves and communicates with anterior mediastinum. **Pretracheal space** located before trachea between parietal and visceral sheets.

V – **prevertebral fascia** envelops all deep cervical muscles forming their sheathes. Retropharyngeal space made up between V fascia and parietal lamina of IV fasciae. **Retrovisceral space** positioned between internal cervical and prevertebral fasciae and contains adipose tissue and continues into posterior mediastinum.

According international nomenclature (PNA) there are 3 laminae of cervical fasciae:

1. **Superficial lamina** meets the superficial lamina of the proper cervical fasciae according V.M.Shevkunenko and contains the *suprasternal space*.

2. **Pretracheal lamina** meets the deep lamina of the proper cervical fasciae according V.M.Shevkunenko and forms *carotid sheath*.

3. **Prevertebral lamina** meets the same fasciae according V.M.Shevkunenko.

**Interscalenum space** positioned between anterior and middle scalene muscles where subclavian artery passes. **Anterscalenum space** located in front of scalene muscles where subclavian vein passes.

Deep lamina of the proper cervical fasciae (V.M.Shevkunenko) associating infrahyoid muscles forms omoclavicular aponeurosis or *cervical sail* (Rishe). Cervical sail assists to drain superficial veins of neck that spliced with it.

**Musculature of upper limb** divides into muscles of the shoulder girdle and free limb.

### **Shoulder Girdle Musculature**

Deltoid

- Origin:
  1. lateral, anterior 1/3 of distal clavicle
  2. lateral boarder of the acromion
  3. scapular spine



- Insertion: deltoid tuberosity of humerus
- Action:
  1. abducts arm
  2. flexion and medial rotation (anterior portion)
  3. extension and lateral rotation (posterior portion)
- Blood:
  1. posterior humeral circumflex artery
  2. deltoid branch of thoracoacromial artery
- Nerve: axillary nerve, C5,6

### **Supraspinatus**

- Origin:
  1. supraspinous fossa
  2. muscle fascia
- Insertion: uppermost of three facets of the greater tubercle of humerus
- Action:
  1. abduction of arm (first 15-20°)
  2. stabilizes glenohumeral joint
- Blood: suprascapular artery (poorly supplied)
- Nerve: suprascapular nerve, C5,6

### **Infraspinatus**

- Origin:
  1. infraspinous fossa
  2. muscle fascia
- Insertion: middle facet of greater tubercle of humerus
- Action:
  1. external rotation of the humerus
  2. stabilizes the glenohumeral joint
- Blood:
  1. suprascapular artery
  2. scapular circumflex artery
- Nerve: suprascapular nerve, C5,6

### **Teres minor**

- Origin: middle half of the scapula's lateral margin
- Insertion: lowest of three facets of the greater tubercle of humerus
- Action:
  1. lateral rotation of the humerus
  2. stabilizes the glenohumeral joint
- Blood: scapular circumflex artery
- Nerve: axillary nerve, C5,6

## **Teres major**

- Origin: inferior, lateral margin of the scapula
- Insertion: crest of lesser tubercle (just medial to the insertion of latissimus dorsi)
- Action:
  1. assists in adduction of arm
  2. assists in medial rotation of arm
  3. assists in extension from an flexed position
- Blood: thoracodorsal artery
- Nerve: lower subscapular nerve, C5,6

## **Subscapularis**

- Origin: subscapular fossa
- Insertion: lesser tubercle of humerus
- Action:
  1. medial rotation of the humerus
  2. stabilizes the glenohumeral joint
- Blood: Branches of subscapular artery
- Nerve: upper & lower subscapular nerves, C5,6

## **Brachium (arm) Musculature**

### **ANTERIOR GROUP**

#### **Coracobrachialis**

- Origin: coracoid process of the scapula
- Insertion: medial shaft of the humerus at about its middle
- Action:
  1. flexes the humerus
  2. assists to adduct the humerus
- Blood: muscular branches of the brachial artery
- Nerve: musculocutaneous nerve, C5,6,(C7)

#### **Biceps brachii**

- Origin:
  1. long head- supraglenoid tubercle and glenohumeral labrum
  2. short head- tip of the coracoid process of the scapula
- Insertion:
  1. radial tuberosity
  2. bicipital aponeurosis
- Action:
  1. flexes the forearm at the elbow (when supinated)
  2. supinates forearm from neutral
  3. stabilizes anterior aspect of shoulder
  4. flexes shoulder (weak if at all)

- Blood: muscular branches of brachial artery
- Nerve: musculocutaneous nerve, C5,6

### **Brachialis**

- Origin:
  - 1.lower 1/2 of anterior humerus
  - 2.both intermuscular septa
- Insertion:
  - 1.ulnar tuberosity
  - 2.coronoid process of ulna slightly
- Action: elbow flexion (major mover)
- Blood:
  - 1.muscular branches of brachial artery
  - 2.radial recurrent artery
- Nerve: musculocutaneous nerve, C5,6

## **POSTERIOR GROUP**

### **Triceps brachii**

- Origin:
  - 1.long head – infraglenoid tubercle of the scapula
  - 2.lateral head – upper half of the posterior surface of the shaft of the humerus, and the upper part of the lateral intermuscular septum
  - 3.medial head – posterior shaft of humerus, distal to radial groove and both the medial and lateral intermuscular septum (deep to the long & lateral heads)
- Insertion:
  - 1.posterior surface of the olecranon process of the ulna
  - 2.deep fascia of the antebrachium
- Action:
  - 1.long – adducts the arm, extends at the shoulder, and a little elbow flexion
  - 2.lateral – extends the forearm at the elbow
  - 3.medial – extends the forearm at the elbow
- Blood:
  - 1.muscular branches of the brachial artery
  - 2.superior ulnar collateral artery
  - 3.profunda brachii artery
- Nerve: radial nerve, C6,7

### **Anconeus**

- Origin: posterior surface of the lateral epicondyle of the humerus
- Insertion: lateral aspect of olecranon extending to the lateral part of ulnar body
- Action:

1. extends the forearm at the elbow
  2. supports the elbow when in full extension
- Blood: middle collateral artery from the profunda brachii artery
  - Nerve: radial nerve, C7,8

## **Antibrachial (forearm) Anterior (Flexor) Musculature**

### **1<sup>st</sup> layer:**

#### **Brachioradialis**

- Origin:
  1. upper lateral supracondylar ridge of humerus (between the triceps and brachialis muscles)
  2. lateral intermuscular septum of humerus
- Insertion:
  1. superior aspect of styloid process of radius
  2. lateral side of the distal 1/2 to 1/3 of the radius
  3. antebrachial fascia
- Action:
  1. flexes the forearm at the elbow
  2. pronates the forearm when supinated
  3. supinates the forearm when pronated
- Blood: radial recurrent artery • Nerve:
  1. radial nerve, C5,6 OR
  2. deep branch of the radial nerve

#### **Pronator teres**

- Origin:
  1. humeral head:
    - a. upper portion of medial epicondyle via the CFT (common flexor tendon)
    - b. medial brachial intermuscular septum
  2. ulnar head – coronoid process of ulna
  3. antebrachial fascia
- Insertion: lateral aspect of radius at the middle of the shaft (pronator tuberosity) • Action:
  1. pronates forearm (during rapid or forced pronation)
  2. weakly flexes the elbow
- Blood:
  1. muscular branches of ulnar artery
  2. muscular branches of radial artery
- Nerve: median nerve, C6,7

#### **Flexor carpi radialis**

- Origin:
  1. medial epicondyle via the CFT (common flexor tendon)
  2. antebrachial fascia

- Insertion: base of the 2nd and sometimes 3rd metacarpals • Action:
  1. flexes the hand at the wrist
  2. radially deviates the wrist
  3. may assist to pronate the forearm
- Blood: muscular branches of radial artery
- Nerve: median nerve, C6,7

### **Palmaris longus**

- Origin:
  1. medial epicondyle via the CFT (common flexor tendon)
  2. antebrachial fascia
- Insertion:
  1. central portion of the flexor retinaculum
  2. superficial portion of the palmar aponeurosis
- Action: flexes the hand at the wrist
- Blood: muscular branches of ulnar artery
- Nerve: median nerve, C6,7

### **Flexor carpi ulnaris**

- Origin:
  1. humeral head – medial epicondyle via the CFT (common flexor tendon)
  2. ulnar head: a. medial aspect of olecranon b. proximal 3/5 of dorsal ulnar shaft c. antebrachial fascia
- Insertion:
  1. pisiform & hamate bones (via the pisohamate ligament)
  2. base of the 5th metacarpal (via the pisometacarpal ligament)
- Action:
  1. flexes the hand at the wrist
  2. ulnarly deviates the wrist
  3. stabilizes wrist to permit powerful thumb motion
- Blood: muscular branches of ulnar artery • Nerve: ulnar nerve, C8, T1

### **2<sup>nd</sup> layer:**

#### **Flexor digitorum superficialis**

- Origin:
  1. humeral-ulnar head:
    - a. medial epicondyle via the CFT (common flexor tendon)
    - b. medial border of base of coronoid process of ulna
    - c. medial (ulnar) collateral ligament
    - d. antebrachial fascia
  2. radial head: oblique line of radius along its upper anterior border
- Insertion: both sides of the base of each middle phalanx of the 4 fingers
- Action:

- 1. flexes the proximal and middle phalanges
- 2. flexes the wrist if fingers are extended
- Blood:
  - 1. muscular branches of ulnar artery
  - 2. muscular branches of radial artery
- Nerve: median nerve, C7,8,T1

### **3d layer:**

#### **Flexor digitorum profundus**

- Origin:
  - 1. anterior & medial surface of upper 3/4 ulna
  - 2. adjacent interosseous membrane
- Insertion: distal phalanx of medial 4 digits (through FDS tunnel)
- Action:
  - 1. flexes the distal IP joints and in so doing flexes the proximal and middle IP joints
  - 2. flexes the wrist if fingers are extended
- Blood:
  - 1. muscular branches of the ulnar artery
  - 2. muscular branches of the radial artery
  - 3. anterior interosseous artery (from ulnar artery)
- Nerve:
  - 1. medial portion – ulnar nerve, C8,T1
  - 2. lateral portion – anterior interosseous branch of median nerve, C8,T1

#### **Flexor pollicis longus**

- Origin:
  - 1. middle anterior surface of the radius
  - 2. interosseous membrane
  - 3. (may also originate from lateral border of coronoid process
  - 4. or medial epicondyle)
- Insertion: palmar aspect of base of the distal phalanx of thumb (deep to flexor retinaculum)
- Action:
  - 1. flexes the distal phalanx of the thumb (IP joint)
  - 2. flexes the other joints to the wrist (McP, CMC and weakly at the wrist)
- Blood:
  - 1. muscular branches of radial artery
  - 2. anterior interosseous artery
- Nerve: anterior interosseous branch of median nerve, C8,T1

### **4<sup>th</sup> layer:**

#### **Pronator quadratus**

- Origin: distal 1/4 anteriomedial surface of ulna
- Insertion: distal 1/4 anteriolateral surface of radius
- Action: pronates the forearm and hand

- Blood:
  1. anterior interosseous artery
  2. muscular branches of the radial artery
- Nerve: anterior interosseous branch of median nerve, C8,T1

## **Antebrachial Posterior (Extensor) Musculature**

### ***Superficial:***

#### **Extensor carpi radialis longus**

- Origin:
  1. lower lateral supracondylar ridge (below the brachioradialis)
  2. lateral intermuscular septum of humerus
- Insertion: base of 2nd metacarpal • Action:
  1. extends the hand at the wrist
  2. radially deviates the hand at the wrist
  3. weakly flexes the forearm at the elbow
  4. weakly supinates the forearm
- Blood: radial recurrent artery • Nerve:
  1. radial nerve, C5,6 OR 2. deep branch of the radial nerve

#### **Extensor carpi radialis brevis**

- Origin:
  1. lateral epicondyle via the CET (common extensor tendon)
  2. radial collateral ligament
  3. antebrachial fascia
- Insertion: base of 3rd metacarpal • Action:
  1. extends the hand at the wrist
  2. radially deviates the hand at the wrist
- Blood: radial recurrent artery
- Nerve: deep branch of the radial nerve, C6,7

#### **Extensor digitorum**

- Origin:
  1. lateral epicondyle via the CET (common extensor tendon)
  2. antebrachial fascia
- Insertion:
  1. base of middle phalanx of each of the four fingers (central band)
  2. base of distal phalanx of each of the four fingers (2 lateral bands)
- Action:
  1. extends the four medial digits
  2. extends the wrist if fingers flexed
  3. abducts the digits (spreads the digits as it extends them)
- Blood: posterior interosseous artery
- Nerve: posterior interosseous nerve of the radial nerve, C6,7,8

#### **Extensor digiti minimi**

- Origin:
  1. lateral epicondyl via the CET (common extensor tendon)

- 2. antebrachial fascia 3. ulnar aspect of extensor digitorum
- Insertion:
  1. base of middle phalanx of the 5th digit (central band)
  2. base of distal phalanx of the 5th digit (2 lateral bands)
- Action:
  1. extends the 5th digit 2. abducts the 5th digit
- Blood: posterior interosseous artery
- Nerve: posterior interosseous nerve of the radial nerve, C6,7,8

### **Extensor carpi ulnaris**

- Origin:
  1. 1st head – lateral epicondyle via the CET (common extensor tendon)
  2. 2nd head – posterior body of ulna 3. antebrachial fascia
- Insertion: medial side of base of the 5th metacarpal • Action:
  1. extends the hand at the wrist
  2. ulnarly deviates the hand at the wrist
- Blood: posterior interosseous artery
- Nerve: posterior interosseous nerve of the radial nerve, C6,7,8

### ***Deep:***

#### **Supinator**

- Origin:
  1. lateral epicondyle of humerus 2. supinator crest of ulna 3. radial collateral ligament 4. annular ligament 5. antebrachial fascia
- Insertion: proximal portion of anteriorlateral surface of the radius
- Action: supinates the forearm • Blood: radial recurrent artery • Nerve: deep branch of the radial nerve, C6

#### **Abductor pollicis longus**

- Origin:
  1. posterior surfaces of ulna and radius
  2. interosseous membrane 3. antebrachial fascia
- Insertion: lateral aspect of base of 1st metacarpal
- Action:
  1. abducts the 1st metacarpal 2. assists to extend & rotate the thumb
  3. radially deviates the hand at the wrist 4. flexes the hand at the wrist
- Blood: posterior interosseous artery
- Nerve: posterior interosseous nerve of the radial nerve, C6,7,(C8)

#### **Extensor pollicis brevis**

- Origin:
  1. posterior surfaces of radius (below abductor pollicis longus)
  2. interosseous membrane 3. antebrachial fascia



• Insertion: base of proximal phalanx of thumb (often a slip inserts into extensor pollicis longus tendon) • Action:

1. extends the proximal phalanx and 1st metacarpal of the thumb
2. radially deviates the hand at the wrist

• Blood: posterior interosseous artery

• Nerve: posterior interosseous nerve of the radial nerve, C6,7,(C8)

### **Extensor pollicis longus**

• Origin:

1. posterior surface of ulna
2. interosseous membrane
3. antebrachial fascia

• Insertion: distal phalanx of thumb • Action:

1. extends distal phalanx of thumb 2. extends proximal phalanx of thumb 3. assists to extend the hand at the wrist (if fingers flexed)

• Blood: posterior interosseous artery

• Nerve: posterior interosseous nerve of the radial nerve, C6,7,8

### **Extensor indicis**

• Origin:

1. posterior surface of ulna (distal to extensor pollicis longus)
2. interosseous membrane
3. antebrachial fascia

• Insertion: base of middle and distal phalanx of the index finger

• Action:

1. extends the 2nd digit (McP & IP joints)
2. adducts the 2nd digit
3. assists to extend the hand at the wrist
4. stabilizes MCP joint for flexion of IP solely

• Blood: posterior interosseous artery

• Nerve: posterior interosseous nerve of the radial nerve, C6,7,8

## **Hand & Wrist Musculature**

### ***Thenar:***

#### **Abductor pollicis brevis**

• Origin:

1. distal border of flexor retinaculum
2. trapezium (may be variable)

• Insertion:

1. lateral aspect of base of proximal phalanx of the thumb 2. may also send a slip to the tendon of extensor pollicis longus

• Action:

1. abducts thumb (at the MCP joint) 2. participates to flex the thumb (at the MCP joint) 3. if attached to extensor pollicis longus, it might assist to extend the thumb

- Blood: superficial palmar branches of radial artery
- Nerve: recurrent branch of median nerve, C8,T1

### **Flexor pollicis brevis**

- Origin:
  - 1.superficial head:
    - a.distal border of flexor retinaculum b.trapezium
  - 2.deep head:
    - a.floor of carpal tunnel b.indirectly to scaphoid & trapezium
- Insertion:
  - 1.base of proximal phalanx of thumb
  - 2.can also attach to the lateral sesamoid bone at the McP joint
- Action: powerfully flexes the thumb (at the McP joint)
- Blood: superficial palmar branches of radial artery • Nerve:
  - 1.superficial head – recurrent branch of median nerve, C8,T1
  - 2.deep head – deep branch of ulnar nerve, C8,T1

### **Opponens pollicis**

- Origin:
  - 1.distal border of flexor retinaculum 2.trapezium
- Insertion: lateral aspect of the 1st metacarpal
- Action: opposes the thumb to the fingers
- Blood: superficial palmar branches of radial artery
- Nerve: recurrent branch of median nerve, C8,T1

### **Adductor pollicis**

- Origin:
  - 1.transverse head: 3rd metacarpal
  - 2.oblique head:
    - a.base of 1st, 2nd and 3rd metacarpals b.floor of carpal tunnel
- Insertion:
  - 1.medial aspect of the base of proximal phalanx
  - 2.medial sesamoid at McP
- Action:
  - 1.adducts the thumb 2.may assist to flex the thumb (at the McP joint)
- Blood: superficial palmar branches of radial artery
- Nerve: deep branch of ulnar nerve, C8,T1

### ***Hypothenar:***

#### **Palmaris brevis**

- Origin: medial margin of palmar aponeurosis
- Insertion:
  - 1.skin of ulnar border of palm
  - 2.may insert on the pisiform

- Action: tenses the skin on the ulnar side, which is used in a grip action
- Blood: superficial palmar branches of ulnar artery
- Nerve: superficial branch of ulnar nerve, C8, T1

### **Abductor digiti minimi**

- Origin: pisiform & tendon of flexor carpi ulnaris • Insertion:
  1. medial aspect of the base of proximal phalanx of the 5th digit
  2. may send a slip to the ulnar side of the dorsal expansion
- Action:
  1. abduct 5th digit (requires pisiform stabilized by FCU) 2. assists to flex the 5th digit (at McP) 3. may assist in extension of 5th digit (at IP due to slips to extensor digitorum)
- Blood: deep palmar branches of ulnar artery
- Nerve: deep branch of ulnar nerve, C8, T1

### **Flexor digiti minimi brevis**

- Origin:
  1. distal border of flexor retinaculum 2. hook of the hamate
- Insertion: medial aspect of the base of proximal phalanx
- Action: flexes the 5th digit (at the McP joint)
- Blood: deep palmar branches of ulnar artery
- Nerve: deep branch of ulnar nerve, C8, T1

### **Opponens digiti minimi**

- Origin:
  1. distal border of flexor retinaculum 2. hook of the hamate
- Insertion: medial aspect of the 5th metacarpal • Action:
  1. opposes the 5th digit with the thumb 2. assists to “cup” the palm
- Blood: deep palmar branches of ulnar artery
- Nerve: deep branch of ulnar nerve, C8, T1

### ***Middle group:***

#### **Palmar interossei**

- Origin: from the side of the metacarpal that faces the midline – to adduct them • Insertion:
  1. on the base of the proximal phalanx of the digit of origin (same side toward the midline) 2. extensor hood of the same digit(s)
- Action:
  1. adducts the fingers
  2. flexes the fingers (at the McP while IP joints are extended)
- Blood: palmar metacarpal artery of deep palmar arch
- Nerve: deep branch of ulnar nerve, C8, T1

## **Dorsal interossei**

- Origin: between each metacarpal • Insertion:
  1. directly distal to the origin on the base of the proximal phalanx closest to the midline (to abduct them.)
  2. extensor hood of the same digit(s)
- Action:
  1. abducts the fingers
  2. flexes the fingers (at the McP while IP joints are extended)
- Blood: palmar metacarpal artery of deep palmar arch
- Nerve: deep branch of ulnar nerve, C8, T1

## **Lumbricals**

- Origin:
  1. tendon of flexor digitorum profundus
  2. 1 & 2 have a single head of origin (from radial aspect of tendon)
  3. 3 & 4 have two heads of origin (each head from an adjacent tendon)
- Insertion: extensor hood of digits 2-5 • Action:
  1. flexes the fingers (at the McP joints)
  2. extend IPs
- Blood: palmar metacarpal artery of deep palmar arch
- Nerve:
  1. 1 & 2 – median nerve, C8, T1
  2. 3 & 4 – deep branch of ulnar nerve, C8, T1

## **Topography of the upper limb**

**Axillary fossa** is deepening between lateral surface of the chest and medial surface of the arm. It is bordered at the front by fold of skin (lower margin of the pectoral major level), from behind – by fold of skin (lower margin of the latissimus dorsi level).

**Axillary cavity** contains adipose tissue, vessels, lymphatic nodes, and nerves. It is bordered at the front by pectoral major and minor muscles; from behind – by latissimus dorsi, subscapular and major teres muscles; medially – by anterior serratus muscle; laterally – surgical neck of the humerus and biceps muscles.

There are three trigones in *anterior wall* of axillary cavity:

1. *claviculo-pectoral trigone* – bordered by lower margin of clavicle and upper margin of pectoral minor muscle;
2. *pectoral trigone* – bordered by upper and lower margin of pectoral minor muscle;
3. *subpectoral trigone* – bordered by lower margins of pectoral minor and pectoral major muscles.

There are two orifices in posterior wall of axillary cavity:

1. *Trilaterum foramen* – bordered by subscapular, teres major muscles and long head of triceps brachii muscle, circumflexa scapulae artery passes through it;

2. *Quadrilaterum foramen* placed laterally from trilaterum foramen and bordered by the same muscles and surgical neck of humerus, circumflexa humeri artery passes through it.

Fascia which covers deltoid muscle, passes into arm (*brachial fascia*). It forms sheathes for muscle, also *medial* and *lateral intermuscular septa* (partitions) of the arm that border anterior and posterior groups of muscles.

*Medial bicipitis sulcus* placed medially between biceps brachii muscle and brachial muscle. There are vessels and nervous bundle runs here. Laterally one can find – *lateral bicipitis sulcus*, where cephalic vein passes.

*Canal of radial nerve* positioned between sulcus in humerus and triceps brachii where radial nerve and deep brachial artery and vein pass.

Diamond-shaped *cubital fossa* located between arm and forearm on front surface. It bordered from below by brachioradialis muscle and pronator teres muscle. It bordered from above by brachial muscle.

### **Bursae of the Shoulder**

A “bursa” is a fluid-filled sac, lined with synovial membranes, that occurs near a joint. There are several bursae associated with the shoulder joint. The major ones include the “subscapular bursa,” located between the joint capsule and the tendon of the subscapularis muscle; the “subdeltoid bursa,” between the joint capsule and the deep surface of the deltoid muscle; the “subacromial bursa,” between the joint capsule and the under surface of the acromion process of the scapula (shoulder blade); and the “subcoracoid bursa,” between the joint capsule and the coracoid process of the scapula. Of these, the subscapular bursa usually is continuous with the synovial cavity of the joint cavity, and although the others do not communicate with the joint cavity, they may be connected to each other. All joints contain bursa, however, the shoulder has eight different bursae (the most of any joint in the body).

### **Fasciae of the upper limb**

Brachial **fascia** passes in forearm as *antebrachial fascia*, which forms sheathes for all muscle of forearm. In wrist it thickens and makes on anterior surface *retinaculum flexorum*.

Last attaches laterally to the radial carpal eminence that formed by tubercles of scaphoid and trapezium bones and medially – to ulnar carpal eminence that formed by pisiform bone and hamulus ossis hamati.

*Carpeal canal* disposed under retinaculum flexorum where tendons of muscles pass from forearm into wrist. *Retinaculum extensorum* placed

on back surface under which 6 osseofibrous canals dispose. There are tendons of extensor muscles:

1. in first canal (starting from the radial side) – tendons of Abductor pollicis longus and Extensor pollicis brevis pass;
2. in second canal – tendons of Extensor carpi radialis longus and Extensor carpi radialis brevis pass;
3. in third canal – tendon of Extensor pollicis longus passes;
4. in fourth canal – tendons of Extensor digitorum and Extensor indicis pass;
5. in fifth canal – tendon of Extensor digiti minimi passes;
6. in sixth canal – tendon of Extensor carpi ulnaris pass.

Tendons of flexor muscles that pass through carpal canal are covered by synovial membrane which form such **sheathes**:

- *common synovial vagina of flexors* – covers tendons of musculus flexor digitorum superficialis and profundus till middle of palm (in little finger it passes till nail phalanx);
- *synovial vagina of tendon for musculus flexor pollicis longus* – covers tendon of same name muscle;
- *synovial vaginae for tendons of musculus flexor digitorum superficialis and profundus (of II, III IV fingers)* – covers tendons of these muscles from base of proximal phalanx till top of the distal phalanx.

There are three grooves between anterior forearm muscles where vessels and nerves disposed:

- *Radial sulcus* – between brachioradial muscle and musculus flexor carpi radialis;
- *Median sulcus* – between musculus flexor carpi radialis and musculus flexor digitorum superficialis;
- *ulnar sulcus* – between musculus flexor carpi ulnaris and musculus flexor digitorum superficialis.

Antebrachial fascia passing in hand makes **fascia of manus** that has palmar and dorsal parts. Palmar part subdivided into *superficial sheet* and *deep sheet*. Deep sheet forms the sheathes for muscles of the hand. Superficial sheet makes up triangle-shaped *palmar aponeurosis*.

Musculature of lower limb **divides into muscles of the pelvic girdle and free limb.**

### **Pelvic (Gluteal) Musculature**

#### ***External group:***

## **Tensor fasciae latae**

- Origin:
  1. anterior aspect of iliac crest
  2. anterior superior iliac spine (ASIS)
- Insertion: anterior aspect of IT band, below greater trochanter
- Action:
  1. hip flexion
  2. medially rotate & abduct a flexed thigh
  3. tenses IT tract to support femur on the tibia during standing
- Blood:
  1. superior gluteal artery
  2. lateral femoral circumflex artery
- Nerve: superior gluteal nerve, L4,5,S1

## **Gluteus maximus**

- Origin:
  1. outer rim of ilium (medial aspect)
  2. dorsal surface of sacrum and coccyx
  3. sacrotuberous ligament
- Insertion:
  1. IT band (primary insertion)
  2. gluteal tuberosity of femur
- Action:
  1. powerful extensor of hip
  2. laterally rotates thigh
  3. upper fibers aid in abduction of thigh
  4. fibers of IT band stabilize a fully extended knee
- Blood:
  1. inferior gluteal artery (primary)
  2. superior gluteal artery
- Nerve: inferior gluteal nerve, L5,S1,2

## **Gluteus medius**

- Origin:
  1. outer aspect of ilium (between iliac crest and anterior and posterior gluteal lines)
  2. upper fascia (AKA gluteal aponeurosis)
- Insertion: superior aspect of greater trochanter
- Action:
  1. anterior and lateral fibers abduct and medially rotate the thigh
  2. posterior fibers may laterally rotate thigh
  3. stabilizes the pelvis and prevents free limb from sagging during gait
- Blood: superior gluteal artery
- Nerve: superior gluteal nerve, L4,5,S1

## **Gluteus minimus**

- Origin: outer aspect of ilium (between anterior and inferior gluteal lines)
- Insertion:

1.greater trochanter (anterior to medius)

2.articular capsule of hip joint

• Action:

1.abduct and medially rotate the thigh 2.stabilizes the pelvis and prevents free limb from sagging during gait

• Blood: superior gluteal artery • Nerve: superior gluteal nerve, L4,5,S1

### **Piriformis**

• Origin: pelvic surface of sacrum (anterior portion) • Insertion: medial surface of greater trochanter (through greater sciatic foramen) • Action:

1.lateral rotation of extended thigh 2.abducts a flexed thigh

• Blood:

1.superior gluteal artery 2.inferior gluteal artery

• Nerve: nerve to piriformis, S1,2

### **Superior gemellus**

• Origin: ischial spine • Insertion: medial aspect of greater trochanter via upper tendon of obturator internus • Action:

1.laterally rotates femur 2.abducts thigh when flexed

• Blood: inferior gluteal artery • Nerve: nerve to obturator internus, L5,S1,2

### **Inferior gemellus**

• Origin: ischial tuberosity • Insertion: medial aspect of greater trochanter via lower tendon of obturator internus • Action: laterally rotates femur • Blood: inferior gluteal artery • Nerve: nerve to quadratus femoris, L4,5,S1

### **Obturator externus**

• Origin:

1.medial surface of obturator foramen 2.external surface of obturator membrane

• Insertion: trochanteric fossa of femur • Action:

1.laterally rotates thigh

2.assists in flexion of hip joint

• Blood: obturator artery • Nerve: obturator nerve, L2,3,4

### **Quadratus femoris**

• Origin: lateral aspect of ischial tuberosity • Insertion: quadrate line (along posterior aspect of femur and intertrochanteric crest) • Action: laterally rotates femur • Blood: inferior gluteal artery • Nerve: nerve to quadratus femoris, L4,5,S1

### ***Muscles of internal group:***

#### **Obturator internus**



- Origin:
  1. internal aspect margins of obturator foramen
  2. obturator membrane
- Insertion: medial aspect of greater trochanter (through lesser sciatic foramen)
- Action:
  1. laterally rotates femur
  2. abducts thigh when flexed
- Blood: inferior gluteal artery
- Nerve: nerve to obturator internus, L5, S1, 2

Iliopsoas muscle = Psoas major and minor muscles + Iliacus

### **Psoas major and minor**

- Origin:
  1. transverse processes of L1-L5
  2. vertebral bodies of T12-L4 and the intervening intervertebral discs
- Insertion: iliopsoas tendon to the lesser trochanter of the femur
- Action:
  1. hip flexion
  2. lateral rotation
- Blood: muscular branches of medial femoral circumflex artery
- Nerve: ventral rami, L1, 2, 3

### **Iliacus**

- Origin: inner surface of upper iliac fossa
- Insertion: iliopsoas tendon to the lesser trochanter of the femur
- Action:
  1. powerful hip flexion
  2. lateral rotation
- Blood: muscular branches of medial femoral circumflex artery
- Nerve: femoral nerve, L3, 4

## **Posterior Thigh Musculature**

### **Semitendinosus**

- Origin: ischial tuberosity
- Insertion:
  1. medial aspect of tibial shaft
  2. contributes to the pes anserine
- Action:
  1. extends hip
  2. flexes knee
  3. medially rotates tibia
- Blood:
  1. perforating branches of profunda femoris
  2. inferior gluteal artery (to upper)
- Nerve: tibial nerve of sciatic bundle, L5, S1, 2

### **Semimembranosus**

- Origin: ischial tuberosity
- Insertion:
  1. posterior medial aspect of medial tibial condyle
  2. fibers join to form most of oblique popliteal ligament (& medial meniscus)

- Action:
  - 1.flexes knee 2.extends hip 3.medially rotates tibia 4.pulls medial meniscus posterior during flexion
- Blood:
  - 1.perforating branches of profunda femoris
  - 2.inferior gluteal artery (to upper)
- Nerve: tibial nerve of sciatic bundle, L5,S1,2

### **Biceps femoris**

- Origin:
  - 1.long head: ischial tuberosity 2.short head: lateral lip of linea aspera and the lateral intermuscular septum
- Insertion:
  - 1.head of fibula 2.maybe to the lateral tibial condyle
- Action:
  - 1.flexor at the knee (mainly short head) 2.laterally rotates thigh if flexed at the knee 3.extends hip (long head)
- Blood:
  - 1.perforating branches of profunda femoris
  - 2.inferior gluteal artery (to upper)
- Nerve:
  - 1.long head – tibial nerve, L5,S1,2
  - 2.short head – common peroneal nerve, L5,S1

Adductor magnus, posterior fibers are sometimes considered part of this group. Its information is listed below with the other thigh adductors.

### **Medial (Adductor) Thigh Musculature**

*Note:* The muscles in this group may also receive blood from obturator artery.

### **Pectineus**

- Origin:
  - 1.pectineal line of the pubis 2.superior pubic ramus
- Insertion:
  - the pectineal line of the femur
  - (just below the lesser trochanter on the posterior aspect of the femur)
- Action:
  - 1.flexes hip 2.adducts thigh 3.medially rotates thigh
- Blood: muscular branches of medial femoral circumflex artery
- Nerve:

- femoral nerve, L3,4 OR • obturator nerve, L2,3,4 OR • femoral L3,4 and accessory obturator L3,4

### **Adductor longus**

- Origin: anterior surface of pubis, just inferior to the pubic tubercle
- Insertion: medial lip of linea aspera on middle half of femur
- Action:
  - 1.adducts thigh
  - 2.flexes thigh
  - 3.may laterally rotate thigh at the hip
- Blood: muscular branches of femoral artery
- Nerve: obturator nerve, L2,3,4

### **Adductor brevis**

- Origin: body & inferior ramus of pubis • Insertion: superior portion of linea aspera • Action:

- 1.adducts thigh (major)
- 2.aids in flexion of thigh
- 3.may laterally rotate thigh at the hip

- Blood: muscular branches of femoral artery
- Nerve: obturator nerve, L2,3,4

### **Adductor magnus**

- Origin:
  - 1.anterior fibers: inferior pubic ramus
  - 2.oblique fibers: ischial ramus
  - 3.posterior fibers: ischial tuberosity
- Insertion:
  - 1.proximal 1/3 of linea aspera
  - 2.adductor tubercle
- Action:
  - 1.adducts the thigh
  - 2.posterior fibers also extend and laterally rotate thigh
- Blood:
  - 1.muscular branches of profunda femoris
- Nerve:
  - 1.anterior fibers: obturator nerve, L2,3,4
  - 2.posterior fibers: tibial nerve of sciatic bundle, L4,5

### **Gracilis**

- Origin: body of pubis & inferior pubic ramus • Insertion:
  - 1.medial surface of proximal tibia, inferior to tibial condyle
  - 2.contributes to the pez anserine
- Action:
  - 1.adducts thigh
  - 2.flexes knee
  - 3.medially rotates tibia
- Blood: obturator artery • Nerve: obturator nerve, L2,3,4

## ***Anterior Thigh Musculature***

### **Sartorius**

- Origin: anterior superior iliac spine (ASIS) • Insertion:
  1. upper medial surface of body of tibia
  2. contributes to pes anserine
- Action:
  1. flexes hip and knee
  2. laterally rotates thigh if flexed at the hip
- Blood:
  1. muscular branches of profunda femoris artery
  2. saphenous branch of descending genicular artery
- Nerve: branches of femoral nerve, L2,3

## **Quadriceps femoris consists of:**

### **1. Rectus femoris**

- Origin:
  1. anterior head: anterior inferior iliac spine (AIIS)
  2. posterior head: ilium just above the acetabulum
- Insertion:
  1. common quadriceps tendon into patella
  2. tibial tuberosity via patellar ligament
- Action:
  1. extends knee
  2. flexes hip
- Blood: lateral femoral circumflex artery
- Nerve: branches of femoral nerve, [L2],3,4

### **2. Vastus lateralis**

- Origin:
  1. greater trochanter
  2. lateral lip of linea aspera
  3. lateral intermuscular septum
- Insertion:
  1. common quadriceps tendon into patella
  2. tibial tuberosity via patellar ligament
- Action:
  1. extends knee
  2. can abnormally displace patella
- Blood: lateral femoral circumflex artery
- Nerve: branches of femoral nerve, [L2],3,4

### **3. Vastus intermedius**

- Origin: anterior lateral aspect of the femoral shaft
- Insertion:
  1. common quadriceps tendon into patella
  2. tibial tuberosity via patellar ligament

- Action: extends knee • Blood: lateral femoral circumflex artery
- Nerve: branches of femoral nerve, [L2],3,4

#### **4. Vastus medialis**

- Origin:
  1. intertrochanteric line of femur
  2. medial aspect of linea aspera
- Insertion:
  1. common quadriceps tendon into patella
  2. tibial tuberosity via patellar ligament
- Action: extends knee
- Blood:
  1. muscular branches of profunda femoris artery
  2. saphenous branch of descending genicular artery
- Nerve: branches of femoral nerve, [L2],3,4

### **Posterior Leg Musculature**

#### ***Superficial:***

Gastrocnemius m. + Soleus m. = Triceps surae

#### **Gastrocnemius**

- Origin:
  1. medial head: just above medial condyle of femur
  2. lateral head: just above lateral condyle of femur
- Insertion: calcaneus via lateral portion of calcaneal tendon • Action:
  1. plantarflex the ankle
  2. knee flexion (when not weight bearing)
  3. stabilizes ankle & knee when standing
- Blood:
  1. sural branches of popliteal artery
  2. muscular branches of peroneal artery
  3. posterior tibial artery
- Nerve: tibial nerve, S1,2

#### **Soleus**

- Origin:
  1. upper fibula
  2. soleal line of tibia
- Insertion: calcaneus via medial portion of calcaneal tendon
- Action: plantarflex the foot • Blood:
  1. sural branches of popliteal artery
  2. muscular branches of peroneal artery
  3. posterior tibial artery
- Nerve: tibial nerve, S1,2

#### **Plantaris**

- Origin: above the lateral head of gastrocnemius on femur • Insertion: calcaneus, medial to calcaneal tendon, or blending with the calcaneal tendon • Action: like a weak gastrocnemius • Blood:
  1. sural branches of popliteal artery
  2. muscular branches of peroneal artery 3. posterior tibial artery
- Nerve: tibial nerve, S1,2

### ***Deep:***

#### **Popliteus**

- Origin:
  1. lateral femoral condyle 2. arcuate popliteal ligament
  3. lateral meniscus 4. knee joint capsule
- Insertion: posterior tibial surface above the soleal line • Action:
  1. insertion fixed: laterally rotates femur on tibia & unlocks knee
  2. origin fixed: medially rotates tibia on femur & unlocks knee
- Blood: sural branches of popliteal artery
- Nerve: tibial nerve, L5, S1

#### **Flexor digitorum longus**

- Origin:
  1. posterior surface of tibia 2. crural fascia
- Insertion: plantar surface of bases of the 2-5th distal phalanges
- Action:
  1. primarily flexes 2nd – 5th toes 2. weak plantarflexor
  3. weak inversion & adduction of foot
- Blood:
  1. peroneal artery 2. posterior tibial artery
- Nerve: tibial nerve, L5, S1

#### **Tibialis posterior**

- Origin:
  1. posterior, proximal tibia 2. interosseous membrane
  3. medial surface of fibula
- Insertion:
  1. navicular tuberosity (principle) 2. all 3 cuneiforms (plantar surface)
  3. bases of 2nd-4th metatarsals 4. cuboid
  5. sustentaculum tali of calcaneus
- Action:
  1. stabilizes ankle 2. inversion & adduction of foot
  3. prevents hyperpronation while in gait 4. weak plantarflexion of ankle
- Blood:

- 1.peroneal artery
  - 2.posterior tibial artery
- Nerve: tibial nerve, L5,S1

### **Flexor hallucis longus**

- Origin:
  - 1.posterior, inferior 2/3 of fibula
  - 2.interosseous membrane
  - 3.crural fascia & posterior intermuscular septum
- Insertion: plantar surface of distal phalanx of hallux • Action:
  - 1.flexes big toe (hallux)
  - 2.weak plantarflexion of the foot
  - 3.weak inversion & adduction of foot
- Blood:
  - 1.peroneal artery
  - 2.posterior tibial artery
- Nerve: tibial nerve, L5,S1,2

### **Lateral Leg Musculature**

#### **Peroneus longus**

- Origin:
  - 1.head of the fibula
  - 2.proximal 2/3 of lateral fibula
  - 3.adjacent intermuscular septum
- Insertion:
  - 1.plantar surface of cuboid
  - 2.base of 1st & (2nd) metatarsal
  - 3.plantar surface of medial cuneiform
- Action:
  - 1.eversion & abduction of the foot
  - 2.weak plantarflexion of the foot at the transverse tarsal joint
- Blood: muscular branches of the peroneal artery
- Nerve: superficial peroneal nerve, L4,5,S1

#### **Peroneus brevis**

- Origin:
  - 1.distal 2/3 of lateral fibula
  - 2.posterior and anterior intermuscular septum
- Insertion: tuberosity on lateral aspect of base of 5th metatarsal
- Action:
  - 1.eversion & abduction of the foot
  - 2.weak plantarflexion of foot
- Blood: muscular branches of the peroneal artery
- Nerve: superficial peroneal nerve, L4,5,S1

### ***Anterior Leg Musculature***

### **Tibialis anterior**

- Origin:
  - 1.lateral tibial condyle
  - 2.proximal 2/3 of anteriolateral surface of tibia
  - 3.interosseous membrane
  - 4.anterior intermuscular septum & crural fascia
- Insertion:
  - 1.medial & plantar surface of base of 1st metatarsal
  - 2.medial & plantar surface of the cuneiform
- Action:
  - 1.strongest dorsiflexor
  - 2.inverts & adducts the foot
- Blood: anterior tibial artery • Nerve: deep peroneal nerve, L4,5,S1

### **Extensor hallucis longus**

- Origin:
  - 1.medial aspect of the fibula
  - 2.interosseous membrane
  - 3.crural fascia
- Insertion: dorsal surface of base of proximal and distal phalanx of hallux
- Action:
  - 1.extends distal phalanx of big toe
  - 2.weak dorsiflexor
  - 3.weak inversion & adduction
- Blood: anterior tibial artery • Nerve: deep peroneal nerve, L4,5,S1

### **Extensor digitorum longus**

- Origin:
  - 1.lateral condyle of the tibia
  - 2.upper anterior surface of fibula
  - 3.interosseous membrane
  - 4.crural fascia
- Insertion:
  - 1.dorsal surface of the bases of the middle & distal phalanxes of the 2nd-5th rays • (via 4 tendons and giving a fibrous expansion)
- Action:
  - 1.extends the lateral 4 toes
  - 2.weak dorsiflexor & everts foot
- Blood: anterior tibial artery • Nerve: deep peroneal nerve, L4,5,S1

### **Peroneus tertius**

- Origin:
  - 1.distal 1/3 of anterior fibula
  - 2.distal & lateral aspect of extensor digitorum
- Insertion: dorsal surface of base of 5th metatarsal
- Action:
  - 1.extends the 5th toe
  - 2.weak dorsiflexor & everts foot
- Blood: anterior tibial artery • Nerve: deep peroneal nerve, L4,5,S1

### **Foot Musculature**



### *Medial group*

#### **Abductor hallucis**

- Origin:
  - 1.medial process of calcaneal tuberosity
  - 2.flexor retinaculum
  - 3.plantar aponeurosis
  - 4.medial intermuscular septum
- Insertion: medial aspect of base of proximal phalanx of hallux
- Action:
  - 1.flexes the big toe (primary action)
  - 2.may assist in abduction of big toe
- Blood: medial plantar artery • Nerve: medial plantar nerve, L5,S1

#### **Flexor hallucis brevis**

- Origin:
  - 1.medial aspect of the cuboid
  - 2.lateral cuneiform
- Insertion:
  - 1.medial aspect of base of proximal phalanx of hallux
  - 2.lateral aspect of base of proximal phalanx of hallux
- Action: flexes hallux at MTP • Blood: medial plantar artery
- Nerve: medial plantar nerve, L5,S1

#### **Adductor hallucis**

- Origin:
  - 1.oblique head: base of 2nd-4th metatarsals & long plantar ligament
  - 2.transverse head: deep transverse metatarsal ligament & plantar ligaments at MTP joints
- Insertion: lateral aspect of base of proximal phalanx of hallux • Action:
  - 1.adduction of hallux at MTP
  - 2.flexes hallux at MTP
- Blood: lateral plantar artery • Nerve: lateral plantar nerve, S1,2

### *Middle group*

#### **Flexor digitorum brevis**

- Origin:
  - 1.medial process of calcaneal tuberosity
  - 2.plantar aponeurosis
- Insertion:
  - both sides of the bases of the middle phalanx of rays 2-5
  - (each of the 4 tendons splits forming tunnel for FDL)
- Action: flexes toes 2-5 • Blood: medial plantar artery
- Nerve: medial plantar nerve, L5,S1

#### **Quadratus plantae**

- Origin:
  - 1.medial head: medial calcaneus

- 2.lateral head: lateral calcaneus & long plantar ligament
- Insertion:
  - lateral margin of tendon of flexor digitorum longus (FDL)
  - may send slips into the distal tendons
- Action:
  - 1.assists FDL in flexing the distal phalanxes of 2nd-5th toes
  - 2.corrects FDL from pulling toes medially
- Blood: lateral plantar artery • Nerve: lateral plantar nerve, S1,2

### **Lumbricals**

- Origin: from tendons of FDL:
  - 1.1st: medial aspect of tendon to 2nd ray
  - 2.2nd-4th: two heads between the tendons in which they lie
- Insertion: extensor tendons of EDL on dorsal foot • Action:
  - 1.flex proximal phalanges at MTP
  - 2.extend middle & distal phalanges at IP
- Blood:
  - 1.1st: medial plantar artery 2.2nd-4th: lateral plantar artery
- Nerve:
  - 1.1st: medial plantar nerve, L5,S1
  - 2.2nd-4th: lateral plantar nerve, S1,2

### **Plantar interossei (3 muscles)**

- Origin: medial aspect of 3rd-5th metatarsals (each muscle has a single head) • Insertion: medial aspect of base of proximal phalanx of the same ray (of 3rd-5th rays) • Action:
  - 1.adduct toes 3-5 2.flex toes 3-5
- Blood: lateral plantar arch
- Nerve: lateral plantar nerve (deep branch), S1,2

### **Dorsal interossei (4 muscles)**

- Origin: from both metatarsals between which they lie • Insertion: base of proximal phalanx closest to the axis of the foot (2nd ray) • Action:
  - 1.abduct toes 2-4 2.flexes toes 2-4 at MTP
- Blood: lateral plantar arch
- Nerve: lateral plantar nerve (deep branch), S1,2

### ***Lateral group***

#### **Abductor digiti minimi**

- Origin:
  - 1.lateral & medial processes of the calcaneal tuberosity
  - 2.plantar aponeurosis 3.lateral intermuscular septum

- Insertion: lateral aspect of base of proximal phalanx of 5th ray
- Action:
  - 1.abducts 5th toe
  - 2.aids in flexing
- Blood: lateral plantar artery • Nerve: lateral plantar nerve, S1,2

### **Abductor ossis metatarsi quinti**

- Origin: from fibers of abductor digiti minimi • Insertion: into the 5th metatarsal • Action: abducts the 5th ray • Blood: lateral plantar artery
- Nerve: lateral plantar nerve, S1,2

### **Flexor digiti minimi brevis**

- Origin:
  - 1.base of 5th metatarsal
  - 2.digital sheath of peroneus longus
- Insertion: lateral aspect of base of proximal phalanx of 5th ray
- Action: flexes the 5th toe at MTP • Blood: lateral plantar artery
- Nerve: lateral plantar nerve, S1,2

### **Opponens digiti minimi brevis**

- Action: opposes the digiti minimi
- Blood: lateral plantar artery • Nerve: lateral plantar nerve, S1,2

## ***Dorsal foot muscles***

### **Extensor hallucis brevis**

- Origin:
  - 1.upper anterolateral calcaneus
  - 2.inferior extensor retinaculum
- Insertion: base of proximal phalanx of hallux • Action: extends hallux • Blood: dorsalis pedis artery • Nerve: deep peroneal nerve, L4,5

### **Extensor digitorum brevis**

- Origin:
  - 1.upper anterolateral calcaneus
  - 2.inferior extensor retinaculum
- Insertion: middle & distal phalanges of 2nd-4th rays (via EDL)
- Action: extends 2nd-4th rays • Blood: dorsalis pedis artery
- Nerve: deep peroneal nerve, L4,5

## **Topographic features of of the lower limb**

Piriform muscle passing through the major ischiadic foramen does not fill it fully, so as result *suprapiriform foramen* and *infrapiriform foramen* appear.

Internal and external obturatorius muscles close obturatum foramen and make up *obturatorius canal*.

There is a space between inguinal ligament and iliac bone. It divided into two orifices *lacuna vasorum* (medially) and *lacuna musculorum* (laterally) by iliopectineal arch that attached to iliopectineal eminence. Lacuna vasorum contains femoral artery and vein; lacuna musculorum carries iliopsoas muscle and femoral nerve.

*Femoral annulus* (positioned in lacuna vasorum) during passing of the femoral hernia convert into *deep annulus of femoral canal*. It bordered laterally by femoral vein, medially – *lacunar ligament*, anteriorly – *inguinal ligament* and from behind – by *pectinal ligament*.

**Pelvic fascia** is continuation of endoabdominal fascia and part of fasciae that cover iliacus and iliopsoas muscles (*iliac fascia*). Pelvic fascia passes into thigh and forms *fascia lata femoris*. This fascia makes up sheathes for femoral muscles also *lateral intermuscular septa* and *medial intermuscular septa* that separate anterior group of femoral muscles from medial and posterior groups.

**Fascia lata femoris** has superficial lamina and profundus lamina. *Profundus lamina* of fascia lata femoris extends along the thigh and its most dense part forms tendon of musculus tensor fasciae latae which also called **iliotibial tract**. *Superficial lamina* of fascia lata lays in femoral trigone and terminates below by *falciform margin* that has *superior cornu* and *inferior cornu*. Superior cornu inosculates with inguinal ligament, inferior cornu – with deep sheet of fascia lata femoris. **Hiatus saphaenus** is formed under falciform margin that covered by *cribriform fascia* (thinnest part of fascia lata). While femoral hernia happened hiatus saphaenus convert into *external annulus of femoral canal*.

**Femoral canal does not exist at norm (!)**, it can appear only during forming the femoral hernia (pathology). Canal has three walls:

- *lateral wall* – femoral vein;
- *anterior wall* – superficial lamina of fasciae latae, inguinal ligament and superior cornu of the falciform margin;
- *posterior wall* – deep lamina of fasciae latae.

While femoral canal made up *femoral annulus* is its deep ring and hernia can exit under skin through the *hiatus saphaenus* (deep ring).

Femoral artery and vein passing through the lacuna vasorum run in *iliopectineus sulcus* (between iliacus and pectineus muscles). Then femoral vessels positioned in *anterior femoral sulcus* which disposed between adductor magnus medially and medial vastus muscle – laterally. On anterior surface of thigh they can notice *femoral trigone*, bordered by inguinal ligament above, medially – adductor longus muscle and laterally – sartorius

muscle. Femoral trigone by its lower angle passes into *adductorius canal* (Hunter's canal), that disposed between adductor magnus medially, vastus medialis laterally and fibrous laminae between these muscles. Adductorius canal opens below by hiatus into popliteal fossa. Saphaenus nerve also as descendent genu artery and vein pass through *anterior* hiatus.

*Popliteal fossa* formed on back surface where thigh passes into leg. It has a diamond shape, bordered above by biceps femoris muscle, semitendinous and semimembranous muscles – medially. Popliteal fossa bordered below by lateral and medial heads of gastrocnemius muscle, its floor is popliteal surface of femoral bone and rear surface of knee joint. Here *cruro-popliteal canal* (Hruber's canal) originates and passes downward in leg between superficial and deep posterior muscles of the leg. *Inferior musculofibular canal* branches off from this canal. It is bordered by fibula and flexor hallucis longus muscle. *Superior musculofibular canal* is independent which disposed between lateral surface of fibulae and musculus fibularis longus.

Fascia lata femoris passes into leg as *crural fascia*, which forms sheathes for muscles of the leg. *Anterior intermuscular septa cruris* and *posterior intermuscular septa cruris* spring from it that separate lateral group leg muscles from the anterior and posterior groups. When crural fascia transites on foot some fibrous stripes form:

- 1) superior retinaculum musculorum extensorum pedis
- 2) inferior retinaculum musculorum extensorum pedis
- 3) superior retinaculum musculorum fibulorum
- 4) inferior retinaculum musculorum fibulorum
- 5) *retinaculum musculorum flexorum pedis*

*Retinaculum musculorum flexorum pedis* covers three osseofibrous canals for tendons of deep posterior crural muscles and fibrous canal for vessels and nerves. Under *retinaculum musculorum extensorum pedis* *three osseofibrous canals* for tendons of anterior crural muscles and one *fibrous canal* for vessels and nerves. *Superior retinaculum musculorum fibulorum* covers one osseofibrous canal for tendons of peroneus longus and brevis muscles. *Inferior* one contains two osseofibrous canals for separate tendons of peroneal muscles. Tendons of muscles passing under *retinaculum* covered by synovial membrane which forms their *synovial vaginae* of tendons.

Fascia cruris passes into foot, forming *dorsal fascia pedis* and *plantar fascia*. Plantar fascia has superficial lamina and deep lamina. Profundus lamina forms synovial vaginae for plantar muscles, also lateral

intermuscular septa and medial intermuscular septa, that separate middle group of muscles from medial and lateral groups. Superficial lamina of plantar fasciae forms ***plantar aponeurosis***, which strengthens the vault of foot. There are *medial plantar sulcus* between flexor digitorum brevis and abductor hallucis and *lateral plantar sulcus* between flexor digitorum brevis and abductor digiti minimi where plantar vessels and nerves pass.

## SPLANCHNOLOGY

**SPLANCHNOLOGY** is doctrine about viscera, which disposed in thoracic, abdominal and pelvic cavities, also in head and neck. Internal organs may be divided into digestive, respiratory, urinary and genital systems and endocrine glands.

## DIGESTIVE SYSTEM

### ***Overview***

The digestive system is a group of organs that work like wrecking equipment to break down the chemical components of food, through the use of digestive juices, into tiny nutrients which can be absorbed to generate energy for the body. Digestion begins in the mouth with the teeth, which grind the food into small particles; the tongue, a powerful muscle which detects “good” and “bad” flavours in food and manipulates the food between the teeth for chewing, and saliva, a watery fluid which lubricates chewing and swallowing and begins the process of digestion. The digestive system begins in the mouth, continues in the pharynx (throat) and oesophagus and into the “gut” region: the stomach, small and large intestines, the rectum and the anus. Food is chewed, pulped and mixed with saliva to become a soft mass which will easily travel down the oesophagus. The tongue traps the food and forces it into the throat, which is a mass of muscles and tissues which transports food into the gut system for final processing and distribution. The liver and the pancreas also secrete digestive juices that break down food as it passes through the digestive ducts. Not all that we eat can be digested, so the waste must be disposed of in an efficient way. It may not be a savoury ending for the food or drink we thought was so delicious in the mouth, but it is just as important for our health.

**Oral cavity** is bordered up by *palate*, which separates the oral cavity from the nasal cavities and the nasal part of the pharynx or nasopharynx; in front and laterally – by *cheeks*, from below – by *oral diaphragm* (formed by mylohyoid muscle). The cavity of the mouth is placed at the commencement of the digestive tube it is a nearly oval-shaped cavity, which consists of two parts: an outer, smaller portion, the *vestibule*, and an inner, larger part, the *proper mouth cavity*. Both portions communicate each other through the space behind last molars and through the fissure between upper and lower teeth. **The vestibule** is the slit like space between the lips, cheeks, the teeth and the gingivae. The vestibule communicates with the exterior through the orifice of the mouth – the opening, through which food and other substances pass into the oral cavity. Duct of parotid salivary gland opens into vestibule.

**Upper and lower lips** (*labia*) formed by orbicularis oris muscle covered externally by skin and internally by mucous membrane and surround the mouth are the entrance to the oral cavity. Both lips unite laterally by *labial commissure*. Around the oral vestibule and between the mucous membrane and the orbicularis oris muscle are located labial salivary glands. The ducts of these small glands open into the vestibule. The upper and lower lips are attached to the gingivae in the median plane by raised folds of mucous membrane, called the *superior* and *inferior labial frenula*. The upper lip has a median vertical groove called the *philtrum*. Intermediate portion *red area* located between the skin and the mucous membrane.

**Cheeks** have a muscular component – buccinator muscle. Superficial to the fascia covering this muscle is the buccal *fat pad* – Bisha body. It gives the cheeks their rounded contour, particularly in infants for sucking the milk. The lips and cheeks function as a unit (for example – during blowing, eating, sucking, and kissing). They act as an oral sphincter in pushing food from the vestibule to the oral cavity proper. Mucous membrane of the cheeks contains small buccal salivary glands.

**Palate** consists of two regions: 1. the anterior two-thirds or bony part – the hard palate. 2. the mobile posterior one-third or fibromuscular part – the soft palate. The **hard palate** formed by palatine processes of the maxillae and the horizontal plates of the palatine bones covered by mucous membrane, which contains small salivary glands. Posteriorly the hard palate is continuous with the soft palate. The **soft palate** contains a membranous aponeurosis and is a movable, fibromuscular fold that is attached to the posterior edge of the hard palate. The soft palate or *velum palatinum* extends

posterior inferiorly to a curved free margin from which hangs a conical process – the *uvula*. It separates the nasopharynx superiorly from the oropharynx inferiorly. Laterally the soft palate is continuous with the wall of the pharynx and is joined to the tongue and pharynx by the *palatoglossal* and *palatopharyngeal arches*, between which locate the *palatine tonsil*. Deep to the palatal mucosa are mucous glands. The soft palate is formed by 5 muscles:

1. *Tensor veli palatini muscle* – stretches velum palatine and widens aperture of auditory tube;
2. *Levator veli palatini muscle* – lifts soft palatine;
3. *Uvulae muscle* – lifts and shortens the uvula;
4. *Palatoglossus muscle* – lowers the velum palatinum, narrows the fauces and lifts the lingual root;
5. *Palatopharyngeus muscle* – narrows the fauces and lifts the pharynx.

The **tongue** is situated partly in the mouth and partly in the oropharynx. It consists of three parts: apex, body and root. Also tongue has *dorsum* (upper surface), *inferior surface*, *margin* and *median sulcus*. The dorsum of the tongue carries V-shaped *sulcus terminalis* with *foramen cecum* at the apex of this sulcus. *Sulcus terminalis* divide dorsum linguae into anterior presulcal and posterior postsulcal parts. There is *lingual tonsil* on the mucous membrane of root.

*Lingual frenulum* attaches anterior presulcal portion to the floor of the mouth. *Fimbriate plicae* pass laterally from frenulum. *Sublingual plica* runs laterally and backward from frenulum base, also it carries *sublingual caruncle*. Ducts of *submandibular* and *sublingual glands* open there. The mucous membrane on the oral part of the tongue carries numerous of the papillae:

- The **filiform** papillae and **conic** papillae – contain afferent nerve endings that are sensitive to touch.
- The **fungiform** papillae – small and mushroom-shaped. They usually appear as pink or red spots. Contain taste receptors located in the taste buds.
- The **vallate** papillae – are the largest papillae (1 to 2 mm in diameter). They lie just anterior to the sulcus terminalis and carry taste buds.
- The **foliate** papillae – are small lateral folds of the lingual margins. They contain taste receptors.

There are four extrinsic and four intrinsic muscles of tongue.

**Extrinsic** group contains four muscles:



1. THE GENIOGLOSSUS MUSCLE arises by a short tendon from the mental spine of the mandible. *Insertion:* enters the tongue inferiorly and its fibers attach to the entire dorsum of the tongue. *Actions:* depresses the tongue and its posterior part protrudes it.

2. THE HYOGLOSSUS MUSCLE arises from the body and greater horn of the hyoid bone. *Insertion:* the side and inferior aspect of the tongue. *Actions:* depresses the tongue, pulling its sides inferiorly.

3. THE STYLOGLOSSUS MUSCLE *originates from* the anterior border of the styloid process near its tip and from the stylohyoid ligament. *Insertion:* the side and inferior aspect of the tongue. *Actions:* lifting the tongue and curls its sides to create a trough during swallowing.

4. THE PALATOGLOSSUS MUSCLE *starts from* the palatine aponeurosis of the soft palate. *Insertion:* the side and the lateral part of the tongue. *Actions:* elevates the posterior part of the tongue.

The *intrinsic muscles* are mainly concerned with altering the shape of the tongue, making it broad or narrow. Their fibers run in three directions.

1. THE SUPERIOR LONGITUDINAL MUSCLE forms a thin layer deep to the mucous membrane on the dorsum of the tongue, running from its apex to its root. *Origin:* the submucous fibrous layer and the lingual septum. *Insertion:* mainly into the mucous membrane. *Actions:* curls the tip and sides of the tongue superiorly, making the dorsum of the tongue concave.

2. THE INFERIOR LONGITUDINAL MUSCLE consists of a narrow band close to the interior surface of the tongue. *Actions:* curls the tip of the tongue inferiorly, making the dorsum of the tongue convex.

3. THE TRANSVERSE MUSCLE lies deep to the superior longitudinal muscle. *Origin:* the fibrous lingual septum. *Insertion:* submucous fibrous tissue. *Actions:* narrows and increases the height of the tongue.

4. VERTICAL MUSCLE originates in dorsum of the tongue. *Insertion:* site of the tongue. *Actions:* flattens and broadens the tongue; acting with the transverse muscle, it increases the length of the tongue.

**The teeth** may be divided into deciduous (primary) teeth in childhood age and permanent teeth in adult. Each tooth consists of three parts: crown, neck and root. The **crown** has 5 surfaces: *lingual*, *vestibular (labial or buccal)*, *contact (proximal and distal)*, *occlusal*. The **neck** is the part of the tooth between the crown and the root. The **root** is fixed in the alveolar socket by a fibrous periodontal ligament (gomphosis).

Tooth is composed of *dentin* that is covered by *enamel* over the crown – and *cementum* over the root. The *pulp cavity* contains connective

tissue, blood vessels, and nerves. The last pass through the *root canal* and the *apical foramen*. The roots of the teeth fit into sockets called *dental alveoli* in the alveolar process of the mandible and maxillae. Each socket is lined with *periodontal membrane*.

### Types of Teeth

**Medial** and **lateral incisors** – have a single root and chisel-shaped crown. Action: they cut off portions of food.

**Canine** – has a single root, conical crown. Action: holding and bite the food.

**Premolar** – has a single root, sometimes upper tooth has bifurcated root. Crown carries two tubercles. Action: crushing the food.

**Molar** – upper teeth have three roots, lower teeth have two roots. Crown carries 3-5 tubercles on occlusal surface. Action: grinding the food.

*Formula* of the deciduous (milk) teeth is 2102. Formula of the permanent teeth is 2123. It means that child before 6 years of age in each side of upper and lower jaw own 2 incisors, 1 canine, no premolar and 2 molars. Permanent teeth include 2 incisors, 1 canine, 2 premolars and 3 molars.

Age terms of eruption of deciduous teeth and permanent teeth:

Type of tooth	<b>Deciduous</b>	<b>Permanent</b>
Incisors	6–9 months	7–9 years
Canines	16–20 months	10–13 years
First Premolar	-	10–12 years
Second Premolar	-	11–15 years
First Molar	12–15 months	6–7 years
Second Molar	20–24 months	13–16 years
Third Molar (“wisdom tooth”)	-	18–30 years

Order of cutting of milk teeth:

- Incisors;
- First molars;
- Canines;
- Second molars.

Child should have 20 teeth till end of second year of age.

Order of eruption of permanent teeth:

- first inferior molars;
- Medial incisors and first superior molars;
- Lateral incisors;
- First premolars;

- Canines;
- Second premolars;
- Second molars;
- Third molars (called “wisdom tooth”, present not in all person).

There are 32 permanent teeth. Mutual arrangement of superior and inferior dental arches during closing the mouth called *bite*. There are the physiological and pathologic bites.

The **gingivae** are composed of fibrous tissue that is covered with mucous membrane. They are firmly attached to the margins of the alveolar processes (tooth sockets) of the jaws and to the necks of the teeth.

**Salivary glands** may be subdivided into small and large. Small one (labial, buccal, palatine and lingual) situated in mucous membrane of mouth cavity.

**Parotid gland** is situated in retromandibular fossa: front and lower from auricle, laterally from ramus mandibulae and posterior margin of masseter muscle. This is – compound alveolar gland, which produces serous secret. *Parotid duct* opens on the cheeks into vestibule of mouth cavity opposite the second superior molar. Parotid gland has superficial part and deep part also can be additional parotid gland, which disposes on surface of masticator muscle closely to parotid duct.

**Submandibular gland** lies in submandibular triangle, it is compound alveolar-tubular gland, and produces mixed secret. Submandibular duct (Vartona) opens on *sublingual papilla*.

**Sublingual gland** lies in the floor of the mouth between the mandible and the genioglossus muscle. This is compound alveolar-tubular gland, it produces mucous secret. *Greater sublingual duct* opens on *sublingual papilla* near submandibular duct (sometimes the ducts open together as one). *Lesser sublingual ducts* open along *sublingual fold*.

**PHARYNX** extends from skull base to level of C6 vertebra. The pharynx is located posterior to the nasal and oral cavities and the larynx and is the common route for air and food (conducts food to the oesophagus and air to the larynx and lungs). Its cavity subdivides into nasal part, oral part and laryngeal part.

*Nasopharynx* is respiratory part; it communicates by *choanae* with nasal cavity. Nasopharynx extends to the bodies of C2 vertebrae. Lateral walls contain the *pharyngeal orifice of auditory tube*, which communicate a pharynx with tympanic cavity. These foramens are limited behind and

from above by *torus tubarius*. Between last and velum one can find pair agglomeration of lymphoid tissue – **tubal tonsil. Pharyngeal (adenoid) tonsil** disposed on border of *pharyngeal fornix* and posterior wall. Submucous layer of nasal part is absent; instead it there is *fibrous membrane*, which does not allow walls to close the cavity of nasopharynx.

*Oropharynx* communicates with mouth cavity by *fauceus*, which is limited by velum palatine, root of tongue and palatine-pharyngeal arches. There are *median glossoepiglottic fold* and *lateral (pair) glossoepiglottic folds*. Posteriorly the oropharynx is related to the bodies of C2 to C4 vertebrae.

*Laryngopharynx* contains the *entrance* into larynx communicates with laryngeal cavity. It is related to the bodies of C4 to C6 vertebrae. *Piriform recesses* are situated on sides from entrance into larynx. Laryngopharynx continues with the oesophagus.

Pharyngeal wall consists of three layers: mucous membrane, muscular and connective tissue membrane (adventitia). Submucous stratum absent, instead of it is pharyngeo-basillar fascia, which is attached to the skull.

*Peripharyngeal space* round the pharynx and may be divided into *retropharyngeal space* (communicates with posterior mediastinum), *lateropharyngeal space* and *parapharyngeal space*.

Muscular membrane is built from longitudinal and circular striped fibres. Longitudinal muscles include:

- *Stylopharyngeus muscle* elevates the pharynx and larynx and expands the sides of the pharynx thereby aiding in pulling the pharyngeal wall over a bolus of food during swallowing;
- *Palatopharyngeus muscle* elevates pharynx and larynx during swallowing and speaking. It also stretches the palatopharyngeal arch;
- *Salpingopharyngeus muscle* elevates the pharynx and larynx and opens the pharyngeal orifice of the auditory tube during swallowing.

Circular muscles include:

- Superior constrictor muscle;
- Middle constrictor muscle;
- Inferior constrictor muscle.

Constrictor muscles contracting from up to down, push a bolus of food into oesophagus and act as a sphincter, preventing air from entering to the oesophagus.

The **OESOPHAGUS** is about 25-30 cm of length tube, which extends from the pharynx to the stomach. Oesophagus has *cervical part, thoracic*

part and *abdominal* part. Topography: thoracic portion positioned in superior and posterior mediastinum. Oesophagus is related to the bodies of C6 to Th 11 vertebrae, also to trachea in cervical part and behind aorta in mediastinum.

Oesophageal wall consists of *mucous membrane*, *submucous stratum*, *muscular membrane* and external connective tissue *adventitia*. Submucous stratum is well developed, that why mucous membrane forms the *longitudinal folds*. Submucous stratum contains the numerous of oesophageal glands. Muscular membrane consists of internal *circular layer* and *external longitudinal layer*. In superior third a muscular membrane is formed by striped muscles, in middle part gradually replaces by smooth muscles, and inferiorly has only the smooth muscles. Abdominal part of oesophagus is covered by peritoneum.

Oesophagus has 3 anatomic constrictions.

- *pharyngeoesophageal constriction* is in place of transition from pharynx into oesophagus, on level of the C7 – 7<sup>th</sup> cervical vertebra;
- constriction of thoracic part is a place, where left principal bronchi, presses an oesophagus is on level of the 5<sup>th</sup> thoracic vertebrae;
- *phrenic* constriction is a place, where an oesophagus passes through the lumbar part of the diaphragm on level of the 9<sup>th</sup> – 10<sup>th</sup> thoracic vertebrae.

Physiological constrictions (2):

- *aortic* constriction is a place, where aorta bends and adjoins to oesophagus on level of the Th4 of thoracic vertebra;
- *abdominal* (cardiac) constriction is in place of entry into cardiac portion of stomach – on level of the Th11 thoracic vertebra.

## THE STOMACH

The main function of the stomach is to process and transport of the food. After feeding, the contractile activity of the stomach helps to mix, grind and eventually evacuate small portions of chyme into the small bowel, while the rest of the chyme is mixed and ground.

Anatomically the J-shaped stomach can be divided into some major regions: *cardia* with *cardiac ostium*, *fundus* or *fornix*, *corpus* and *pylorus*. Last contains *antrum*, *pyloric canal* and *pyloric ostium*. Externally stomach has *anterior* and *posterior facies*, which meet each other in *greater* and *lesser curvaturae*. Lesser curvature orients to the right and upward and carries *angular incisura*.

### Topography of the Stomach

- Holotomy: Stomach is disposed in left hypochondriac and proper epigastric areas;

- Skeletotomy: Stomach is related to the bodies of Th11 to L1 vertebrae. Cardiac ostium is disposed on level of the Th11 on the left from backbone, and pyloric ostium – on level of the Th12-L1 to the right side; stomach fundus reaches the 5th intercostal space on left medioclavicular line;

- Syntopy: the diaphragm, left liver lobe and anterior abdominal wall adjoin to anterior stomach wall. Posterior stomach surface adjoins to spleen, pancreas, and left kidney with left adrenal gland and transversal colon.

- Stomach is covered by *peritoneum* from all sides (intraperitoneally).

The stomach wall, like the wall of most other parts of the digestive canal, consists of three layers: the mucosa (the innermost), the muscularis and the serosal – visceral sheet of peritoneum (the outermost). The ***mucosal*** layer itself can be divided into three layers: the mucosa (the epithelial lining of the gastric cavity), the muscularis mucosae (low density smooth muscle cells) and the submucosal layer (consisting of connective tissue interlaced with plexi of the enteric nervous system). Mucous membrane contains the *gastric fields*, which carry the *gastric pits*, where the ducts of gastric glands open. Lesser curvaturae carries group of longitudinal folds. Mucous membrane forms in area of pyloric ostium pyloric valve, which regulates transition of bolus of food into duodenum.

The second gastric layer, the ***muscularis***, can also be divided into three layers: the longitudinal (the most superficial), the circular and the oblique. The thickness of the circular layer increases in the antrum and especially in the *pyloric sphincter*, which controls the rate of discharge of stomach contents into the duodenum. The longitudinal layer of the muscularis can be separated into two different categories: a longitudinal layer that is common with the oesophagus and ends in the corpus, and a longitudinal layer that originates in the corpus and spreads into the duodenum. The oblique layer of the muscularis is clearly seen in the fundus and near the lesser curvature of the corpus, but the oblique fibers disappear distally (towards the antrum). The outermost main layer is the *serosa*. Double layer of peritoneum forms *hepatogastric*, *gastrophrenic*, *gastrocolic* and *gastrolial ligaments*.

BOWEL can be subdivided into small intestine and large intestine. Small intestine consists of duodenum (portion without mesentery), jejunum and ileum (mesenteric portion). Large intestine includes cecum and colon

(ascending colon, transverse colon, descending colon, sigmoid colon) and rectum with anal channel.

**SMALL INTESTINE.** Topography: holotopy – small intestine lies in abdominal cavity and occupies epigastrium, mesogastrium and partly hypogastrium (pubic region). Skeletotopy – small intestine extends from the level of Th12 vertebral body till area of right iliac fossa. Syntopy – large intestine, duodenum, pancreas, liver, ductus choledochus, right kidney lie around coils of small intestine.

Horseshoe-shaped **DUODENUM** projected in umbilical area. The duodenum was given its name because it is usually 12 fingerbreadths long (about 25 cm–30 cm). It subdivides into *superior part* (ampoule on level of the Th 12–L1 vertebrae), *descending* (on the level of L 1-3 vertebrae), *horizontal part* (on level of L 3 vertebra) and *ascending part* (on the level of L 2-3 vertebrae). Transition of superior part into downward is called *superior flexura* of duodenum, transition of descending into horizontal part – *inferior flexura* of duodenum; transition of duodenum into jejunum generates *duodenojejunal flexura*, which fixed by *suspensorius muscle* of duodenum to ht posterior abdominal wall (ligament of Treitz).

Duodenum adjoins above to quadrate lobe of *liver* and *gallbladder*, in inferiorly – to right *kidney* with *adrenal gland* and by internal surface girds head of *pancreas*. Duodenum is covered by peritoneum from one side (retroperineal position). Hepatoduodenal ligament passes from liver to intestine.

Structure of duodenal wall:

- external membrane (*fibrous* and in front – *anterior serous* / peritoneum/);
- middle membrane – *muscular*, which consists of external longitudinal and internal circular fibres;
- internal membrane – *mucous membrane* with well developed submucous stratum. There are circular folds in all duodenal portiotns, medial wall of descending part contains *longitudinal fold* of duodenum, which carries *major papilla* (ampoule of ductus choledochus and pancreatic duct opens here) and *minor papilla* of duodenum, where accessories duct of pancreas opens.

The **JEJUNUM** occupies initial 2/5 part of mesenteric small intestine and has a structure typical for gastric-intestinal tract. The wall consists of: Serous membrane, muscular membrane, formed by longitudinal layer (stratum longitudinale) and circular layer (stratum circulare), and mucous membrane (tunica mucosa). Last forms the numerous of circular folds.

Mucous membrane carries a numerous of specific finger-like processes that project from the surface of the mucosa into the lumen. They are fingerlike projections consisting of a core of reticular tissue covered by a surface epithelium. The connective tissue core contains numerous blood capillaries forming a plexus. The endothelium lining the blood capillaries is fenestrated thus allowing rapid absorption of nutrients into the blood. They are responsible for absorption of amino acids and carbohydrates, present in digested food. Some villi contain a central lymphatic vessel and called a lacteal (for absorption of fat). *Solitary lymphatic follicles* represent lymphoid apparatus of mucous membrane of the jejunum.

The **ILEUM** occupies 3/5 terminal portion of small intestine and has a structure, analogic to jejunum. Lymphoid apparatus of mucous membrane of the ileum is represented by *aggregated lymphatic follicles* (Payer's patches). An ileal diverticulum (Meckel's *diverticulum*) is one of the most common malformations of the digestive tract. It occurs in 1 to 2% of people. This blind sac or fingerlike pouch is the remnant of the proximal part of the embryonic yolk stalk, jt is of clinical significance because it sometimes becomes inflamed and may cause symptoms that appendicitis.

Serous membrane /Peritoneum/ cover Jejunum and Ileum completely, and forms for them **mesentery** which contains blood and lymphatic vessels, nodes, nerves that supply the bowel also adipose tissue.

**LARGE INTESTINE** extends from the end of the ileum to the anus. It is about 1.5 meters long, being one-fifth of the whole extent of the intestinal canal. It owns the special signs, which distinguish it from small intestine: **1) teniae colli** – thickened bands of longitudinal muscle. There are *tenia libera*, *omental tenia* and *mesocolic tenia*. Large intestine has **2) epiploic appendices** located along teniae. Externally positioned sacculations between the teniae – **3) intestinal haustrae** that relate to spaces between *semilunar folds* on internal surface.

The **Cecum** is situated in right iliac fossa, projected on right inguinal region. Cecum covered by peritoneum fully (intraperitoneal position) and does not have own mesentery. In place of gathering of three teniae ostium of worm-shaped 8-cm in length blind tube **vermiform appendix** disposes, which has own *mesentery*. Transition of ileum into cecum is *ileocolic junction*. *Superior labium* and *inferior labium* of this orifice communicate by *frenulum*, they form *ileocolic valve*, which serves for closing of ileocolic ostium and prevents return the chyme into ileum.



The **Ascending colon** is situated in right lateral abdominal area, covered by peritoneum from three sides (mesoperitoneal position), does not have an own mesentery. Transition into transverse colon generates a *right flexure of colon*, which adjoins to right lobe of the liver that is why called as hepatic flexure of colon.

The **Transverse colon** passes in abdominal cavity from the right to the left, so mobile portion of bowel because has *mesentery* (intraperitoneal position). Transition into descending colon forms *left colic flexura*, which adjoins to spleen (splenic flexura).

The **Descending colon** positioned in left lateral abdominal region, covered by peritoneum from three sides (mesoperitoneal position), without mesentery.

S-shaped **Sigmoid colon** contained in left iliac fossa; covered by peritoneum from all sides (intraperitoneally) and has a *mesentery*.

The **Rectum** is continuous above with the sigmoid colon, while below it ends in the anal canal. It forms two *flexurae* in sagittal plane: superior sacral flexura, responses concave anterior surface of sacrum and inferior anorectal flexura or perineal flexura, that is situated on transition of rectum into anal canal in pelvic perineal diaphragm. Also rectum has lateral flexurae in frontal plane. Upper broadened part of rectum called as the *rectal ampulla*. External layer of rectum wall is connective tissue – adventitia and serous peritoneum; middle layer is muscularis, which has the longitudinal and circular fibres; mucous membrane forms the *transverse folds* of rectum (*plicae transversae recti* – superior, middle and inferior).

The **Anal Canal** is terminal portion of the large intestine, begins at the level of the apex of the prostate, is directed downward and backward, and ends at the **anus**. *External sphincter muscle* of anus (*musculus sphincter ani externus*) lies under skin. It formed by striated (voluntary controlled) muscles of perineum. *Internal sphincter* of anus (*m. sphincter ani internus*) positioned deeper. It is formed by continuation of the circular muscular layer of the intestine and built by smooth muscular fibres (involuntary). Above the external and the internal sphincter muscles lies the *puborectal muscle* (part of *levator ani muscle*) is important muscle of the sphincter. Part of the *pubococcygeal* muscle also takes part in anal closure. The muscles are under permanent tension except during the act of defecation.

Mucous membrane of the anal canal forms 8-10 permanent longitudinal folds *columne anales*, between which are *anal sinuses*, which end below in small valve-like folds, termed *anal valves*. They join together

the lower ends of the rectal columns. Submucous stratum in this area contains developed venous plexus *hemorrhoidal plexus*.

The rectum is covered by peritoneum above on its anterior surface and sides; below, on its anterior aspect only; the anal canal is entirely devoid of any serous covering.

The **Liver**, the largest gland in the body, also performs important exocrine and metabolic functions:

- The secretion of bile.
- The protective role by detoxifying substances.
- The storehouse for various substances.
- Metabolising the products of digestion.
- The synthesis of proteins.
- The metabolism of carbohydrates and the regulation of blood glucose.
- The metabolism of fats and the regulation of blood lipids.
- The conjugation of substances.
- The transformation of substances.
- The production of carbohydrates from proteins.
- The haemopoietic function – especially during foetal life the liver is a centre for haemopoiesis and new-born.
- The production of thrombolytic agents.
- The synthesis of procoagulants.

Topography of the liver. Holotopy: Liver occupies right hypochondriac region, proper epigastric region and small part of left hypochondriac region. Skeletotopy: The upper edge of the liver projects in right 10th intercostal space (middle axillar line). Than it lifts to level of 4th rib (middle clavicular line) and passes across the sternum a bit upper from xiphoid process, terminates in left 5th intercostal space (between middle clavicular line and parasternal lines). The lower edge of the liver passes along the costal arch from right 10th intercostal space (middle axillar line). Than it crosses cartilage of right 9th rib and runs in epigastrium 1,5 cm lower from xiphoid process to cartilage of left 8th rib and meets the upper margin.

We distinguish the convex *diaphragmatic* surface of the liver and lower *visceral* surface. Visceral surface adjoins to the organs, which form on surface of the liver suitable ‘tracks’: *renal, adrenal, gastric, duodenal, oesophageal* and *colic impressions*. Diaphragmatic surface carries *cardiac impression*.

Liver is almost entirely covered with peritoneum except posteriorly positioned ‘area nuda’. The superior surface is attached to the diaphragm and anterior abdominal wall by a fold of peritoneum, the *falciform ligament*, in the free margin of which is a rounded cord, the *ligamentum teres*

(obliterated umbilical vein). The liver is connected to the lower surface of the diaphragm by the *coronal ligament* and the *right and left triangular ligaments*. The falciform ligament conventionally separates greater **right lobe** of liver and lesser **left lobe** of liver.

The *porta hepatis*, the entrance into the liver forms a cross-connection between the sagittal grooves which together are shaped like an H. Visceral surface carries furrows: *right sagittal sulcus* and *left sagittal sulcus*, which communicate by transversal sulcus (is called '*porta hepatis*'). Left sagittal sulcus anteriorly contain *fissure of teres ligament*, where umbilical vein in foetus passes. It obliterates in adult and forms *teres liver ligament*. Posterior portion of left sagittal sulcus is formed by *fissura of venous ligament* (obliterated venous duct of Arantii). Right sagittal sulcus anteriorly contains *fossa of gall bladder*, and behind – *sulcus of inferior vena cava*. Vena portae, proper hepatic artery and nerves enter through the *porta hepatis* into liver, common hepatic duct and lymphatic vessels leave the parenchyma in this place. Sagittal and transversal sulcuses limit the *quadrate lobe*, positioned ventrally and *caudate lobe*, disposed dorsally. Caudate lobe carries *papillary* and *caudate processes*.

The liver is held together by a tense connective tissue capsule Glisson's capsule. At the porta it separates the *lobules* of liver. The lobules form the chief mass of the hepatic substance. Branches of portal vein, hepatic artery and biliary duct form a *hepatic triad* are situated in stratums between liver lobules.

Unlike all other organs a liver obtains arterial blood from proper hepatic **artery** and venous – from portal **vein**. Entering into liver porta, a portal vein and hepatic artery disintegrate into right and left *lobar*, *segmental* and *lobular* veins and arteries, which pass along *interlobular bile duct*. Capillaries from these vessels joining together form **sinusoid capillaries** that receive mixed blood and empty into a *central vein*, which occupies the centre of the lobule. Central vein drains into *hepatic veins*, which leave the liver to end in the *inferior vena cava*. This system is called as wonderful venous liver net.

Hepatic cells 'hepatocytes' excrete the bile, which get into *bile canaliculi*. Last pass to periphery empty into *interlobular ductuli* that form *right hepatic duct* and *left hepatic duct* (from right and left hepatic lobes). *Common hepatic duct*, which originated in porta, passes in hepatoduodenal ligament, meets the *cystic duct* and forms *ductus choledochus*. It flows together with *pancreatic duct* and forms common *hepalopancreatic*

*ampulla*, which opens on *major duodenal papilla*. The ampulla may itself be closed by its own sphincter muscle, the *sphincter ampullae (Oddi)*.

The **GALLBLADDER** is a pear-shaped, thin-walled bag, which collects up to 30-50 ml bile. We distinguish *fundus*, *body* and *neck* of gallbladder, which continues into *cystic duct*. The gallbladder lies in a fossa in the liver to which it is attached by connective tissue and covered by peritoneum from below (mesoperitoneal position). The lumen of the neck of the gallbladder and of its connections with the cystic duct is incompletely subdivided by spiral fold of mucosa, known as the *spiral fold* (Heisler's valve).

The **PANCREAS** is the most important intestinal gland. The pancreas is shaped like a horizontal wedge with its thin end on the left. The *head* is the thickest part, fills into the duodenal loop to the right of the spine. The horizontal *body* continues into *tail*. The *pancreatic duct* runs right through the length of the gland. It receives short, vertical tributaries from the *lobules* and has its own *sphincter muscle* of pancreatic duct. The pancreatic duct ends together with the *common bile duct* on the *major duodenal papilla*. If present, the *accessory pancreatic duct* ends above the bile duct on the *minor duodenal papilla*.

Topography of the pancreas. Pancreas lies in upper abdominal region behind the peritoneum (retroperitoneal position) at the level of the from 1<sup>st</sup> to 3<sup>d</sup> lumbar vertebrae. Along the upper margin of the pancreas runs the splenic artery. The right kidney and adrenal gland adjoin to body of pancreas. Anterior surface of gland touches the stomach, posterior surface – inferior vena cava and aorta. Tail adjoins to splenic hilus.

Endocrine part of pancreas is represented by *islets of Langerhans*. They produce *insulin* and *glucagon* that regulate metabolism of carbohydrates, regulate a sugar contents in organism. Attached to insufficient production of these hormonal disease sugar diabetes arises.

The **SPLEEN** lies in epigastrium and belongs to secondary lymphatic organs and is a big lymphatic node. Spleen is disposed in left hypochondriac region on the level of 9<sup>th</sup> -11<sup>th</sup> ribs. Spleen has *inferior margin* and *superior margin*, *anterior extremity* and *posterior extremity*. It has a *diaphragmatic surface* (superior) and *visceral surface* (inferior). To the last adjoin stomach (*facies gastrica*), left kidney with suprarenal gland (*facies renalis*), left colic flexure (*facies colica*) and tail of pancreas (*facies pancreatica*). Place

on visceral surface, where vessels and nerves enter and leave, is called as **splenic hilus**. Spleen is covered by peritoneum from all sides (lies intraperitoneally).

Spleen is covered by *fibrous capsule*, from which numerous small fibrous bands, *trabeculae* are given off in all directions into parenchyma, these uniting, and constitute the framework of the spleen. Parenchyma consists of splenic pulp, which has a *white pulp* and *red pulp* and its structure described in detail in histology course.

THE **PERITONEUM** is serous membrane that covers the walls of abdominal cavity and viscera in abdomen and pelvis. It may be subdivided into *parietal* peritoneum and *visceral* peritoneum. Transition of parietal peritoneum into visceral peritoneum realizes by derivatives: *ligament*, *mesentery* and *omentum*. If organ covered by peritoneum from all sides, such position is called intraperitoneal; if from three sides – mesoperitoneal position; if only one side – extraperitoneal or retroperitoneal.

**Abdominal cavity** is limited:

- above – by diaphragm
- anteriorly and laterally – by muscles, fasciae, skin
- behind – by lumbar and sacral portions of backbone and lumbar muscles
- from below – by bones, ligaments and muscles of pelvis.

Abdominal cavity contains the organs of digestive and urogenital systems and spleen.

**Peritoneal cavity** is complex of fissure between abdominal organs and walls lined by parietal and visceral sheets that contain serous liquid. It can be subdivided into superior storey and inferior storey, also cavity of lesser pelvis.

Superior storey of peritoneal cavity positioned between diaphragm and level of mesocolon of transverse colon. It contains:

- *hepatic bursa* surrounds right hepatic lobe and gallbladder;
- *pregastric bursa* accommodates left hepatic lobe and anterior wall of stomach;
- *omental bursa* is situated behind lesser omentum and it is in touch with posterior stomach surface.

**Lesser omentum** is formed by double peritoneal sheet that forms of *hepatogastric ligament* and *hepatoduodenal ligament*. Lesser omentum carries common bile duct, portal vein and proper hepatic artery (DVA).

Hepatic bursa communicates with omental bursa by the medium of *epiploic foramen* (of Winslow). Last limited from above by caudate lobe of the liver, from below – by superior part of duodenum, anteriorly – hepatoduodenal ligament, behind – by parietal sheet of peritoneum.

**Greater omentum** develops from 4 peritoneal sheets, which continue from *gastrocolic ligament* and, freely hanging down, covers the abdominal organs in front. The *gastrocolic ligament* connects the transverse colon with the greater curvature of the stomach.

Inferior floor of peritoneal cavity extends from mesocolon of transverse colon to entrance into lesser pelvis.

Root of small intestine mesentery divides the inferior storey into *right* and *left mesenteric sinuses*. They accommodate the loops of small intestine. Right mesenteric sinus is bordered by mesenteric root and ascending colon. In place, where ileum continues into cecum *superior* and *inferior ileocecal recesses* are situated. One can see *retrocecal recess* behind cecum. *Right paracolic sulcus* runs between ascending colon and parietal peritoneum of lateral abdominal wall. Mesenteric root, descending colon and sigmoid colon border *left mesenteric sinus*. *Superior* and *inferior duodenal recesses* are positioned in area of duodenojejunal junction. Mesocolon of sigmoid forms *intersigmoidal recess*. *Left paracolic sulcus* runs between descending colon and parietal peritoneum of left abdominal wall.

Parietal sheet of peritoneum covering back surface of anterior abdominal form plicae (folds) and fossae. The *median umbilical fold* contains the remnant of the embryonic urachus; the *medial umbilical folds* carry obliterated umbilical arteries; *lateral umbilical folds* contain inferior epigastric arteries. *Supravesical fossae* positioned between median and medial umbilical folds. *Medial umbilical fossae* located between medial and lateral umbilical folds. *Lateral umbilical fossae* located laterally from lateral umbilical folds. *Medial and lateral umbilical fossae* can be projected into superficial inguinal ring and deep inguinal ring.

Cavity of lesser pelvis

Peritoneal cavity in the male pelvis contains rectovesical *excavation* (pouch). Peritoneum in the female between uterus and urinary bladder form *vesicouterine excavation*. Behind the uterus peritoneum descends into the *rectouterine pouch* (pouch of Douglas), which is the lowest point of the peritoneal cavity. That is why some liquid from all peritoneal cavity can collect here during some pathology. The entrance into the rectouterine

pouch is narrowed by the *rectouterine folds*, in which the rectouterine muscles run.

## RESPIRATORY SYSTEM

**RESPIRATORY SYSTEM** subdivides into superior respiratory tracts (nasal cavity and pharynx) and inferior respiratory tracts (larynx, trachea, bronchi, lungs).

Nasal cavity consists of bony and cartilaginous parts. Cartilaginous part is built from:

- *lateral nasal cartilage*;
- *major nasal alar cartilage*;
- *minor alar nasal cartilages*;
- *cartilage of nasal septum*.

Thank to presence of nasal cartilages, *nostrils* are open and dissevered one from another. Dorsum nasi passes into nasal tip and laterally – into alae of nose.

Nasal cavity subdivides on respiratory part and olfactory part. *Superior nasal meatus* contains *olfactory area*, and middle nasal meatus and inferior nasal meatus are respiratory. *Superior nasal meatus* passes between upper and middle nasal conchae and communicates with sphenoid sinus through sphenothmoid recess. Posterior ethmoid cells open into superior nasal meatus

*Middle nasal meatus* runs between middle and lower nasal conchae and communicates with frontal (through ethmoid infundibulum) and maxillary (Haymory) sinus (through semilunar hiatus), and with anterior and middle ethmoid cells. *Inferior nasal meatus* passes between lower nasal concha and bony palate; nasolacrimal canal opens in it.

Air flies from nasal cavity, also through the paranasal sinuses, where it gets warm and cleans, is gets into pharynx, and then into larynx.

The **LARYNX** is situated in anterior neck area on level IV-VI cervical vertebrae. At the front infrahyoid muscles of neck cover it. Vessels and nervous bundles and lobes of thyroid gland lie from sides of larynx. Laryngeal part of pharynx adjoins behind it.

Larynx skeleton consists of pair and odd cartilages.

**Odd** cartilages:

- **Thyroid** cartilage, which consists of right and left plates (*lamina dextra et sinistra*), and also has superior horns and inferior horns; the plates converge forming *laryngeal prominence* (Adam's apple);

- **Cricoid** cartilage which has anteriorly arch behind – plate of cricoid cartilage;

- **Epiglottis** cartilage.

*Paired* cartilages:

- **Arytenoid** cartilage, which has a base and apex, muscular process and vocal process. These cartilage lie on plate of cricoid cartilage;

- **Corniculate** cartilage lies in aryepiglottic fold on top of arytenoid cartilages;

- **Cuneiform** cartilage lies in aryepiglottic fold front of corniculate cartilages.

In larynx they distinguish such articulations:

- *Cricoid-thyroid joint* is between inferior cornu of thyroid cartilage and arch of cricoid cartilage; in this joint movement is possible around transversal axis;

- *Cricoid-arytenoid joint* is situated between base of arytenoid cartilages and plate of cricoid cartilage. Arytenoid cartilage can rotate slide to meet one another.

Ligaments of the larynx:

- Thyro-hyoid membrane, which hangs larynx to hyoid bone;

- Crico-thyroid ligament;

- Thyro-epiglottic ligament;

- Hyoepiglottic ligament;

- Vestibular ligaments, which are situated over vocal ligaments.

Fibroelastic membrane the larynx:

- *Elastic cone* contains in its superior margin vocal ligament;

- *Quadrangular membrane*, which is situated over elastic cone and in its inferior margin contains vestibular ligament.

Fibroelastic membranes together with laryngeal cartilages form a laryngeal skeleton.

The laryngeal Muscles subdivide on muscles that narrow/broaden the glottis, muscles that change tension of vocal ligament.

Constrictors of the glottis:

- lateral cricoarytenoid muscle;

- thyroarytenoid muscle;

- transverse arytenoid muscle;

- oblique arytenoid muscles.



Muscles-dilators of the glottis

- *thyro-arytenoid muscle* has thyro-epiglottic part. Action: it raises the epiglottis and broadens an entrance into larynx and vestibule.

- *posterior cricoid-arytenoid muscle*.

Muscles changing tension of vocal ligament:

- *crico-thyroid muscle* stretches a vocal ligament.

- *vocal muscle* is situated in thickness of vocal fold and changes an tension degree of vocal cords.

*Laryngeal cavity* has aditus laryngis [entrance], vestibule, interventricular space, glottis and infraglottic cavity.

Larynx has true *vocal folds* and *glottis*. Larynx begins by entrance into larynx, which is limited at the front, by epiglottis, behind – by arytenoid cartilages, and laterally – by arytenoepiglottic folds, where cuneiform and corniculate tubercles are situated (places of the same name cartilages). *Glottis* is a most narrow place in laryngeal cavity; it is situated between right and left vocal plicae. *Laryngeal ventricle* is fissure disposed between vocal and vestibular plicae.

*Infraglottic cavity* is inferior broadened part of larynx, which continues into trachea.

The **TRACHEA** is a tube, which consists of 16-20 *semicircular cartilages*, joint each other by *annular ligaments*. Last built by connective tissue with smooth muscular fibers. Behind semi-rings communicate by each other by *membranous tracheal wall*. Trachea (windpipe) extends from VI cervical to V thoracic vertebra, where it ramifies on two *principal bronchi*. This place is *tracheal bifurcation*. Trachea has cervical part and thoracic part. *Cervical part* at the front covered by infrahyoid muscles and isthmus of thyroid gland that accords to the second-third tracheal ring. Esophagus (gullet) passes behind the trachea. *Thoracic part* of trachea is situated in superior mediastinum.

PRINCIPAL BRONCHI are generated from the bifurcation of trachea and have similar structure as trachea. *Right principal bronchus* is wider than left and it is continuation of trachea by its direction. It consists of 6-8 cartilaginous semirings. *Left principal bronchus* is longer and narrower and passes with angle from trachea than right. It consists of 9-12 cartilaginous semi-ring. The principal bronchi are the bronchi of first order, the bronchial tree starts from them. The extraneous things, especially in children, more frequently get into right principal bronchus.

The **LUNGS** are the pair parenchymatic organs, which occupy larger part of thoracic cavity. Each lung has a pulmonal *base* and *apex*; *costal*

*surface, diaphragmatic surface, interlobar surface and medial surface.* Medial surface subdivides into posterior (vertebral) surface and anterior (mediastinal) surface. They distinguish *anterior margin* and *inferior margin* on lungs. There is *pulmonal hilus* on mediastinal surface through which pulmonary artery, bronchi and nerves, enter into the lung, lymphatic vessels and pulmonary veins leave the lungs. All these elements, which enter and exit from lung gates, form a *pulmonary root*. Arrangement of vessels and bronchus in left pulmonary root: from above downwards: pulmonary artery, bronchus and vein (ABV). Arrangement of vessels and bronchus in right pulmonary root (from above downwards): bronchus, pulmonary artery, and vein (BAV). On lateral surface of lungs *oblique fissura* passes, which subdivides each lung into **superior** lobe and **inferior** lobe. Right lung, except oblique fissure, has a *horizontal fissure* passes on level of the IV ribs, which separates **middle** and **inferior** lobes of the right lung. Left lung is more narrow and longer than right one and in area of anterior margin it has cardiac notch of left lung, limited from below by *uvula*. The principal bronchi, turning into lung gates, subdivide into bronchi of second order, which ventilate lung lobes (lobar bronchi). There are 2 lobar bronchi in left lung, and 3 – in right lung. The lobar bronchi subdivide into bronchi of third order, which ventilate lung area, dissociated from neighboring by stratum of connective tissue, which is called as lung *segment*. That's why these bronchi are called as by segmental bronchi. According to San Paulo nomenclature in superior lobe of **right lung** situated 3 segments, in middle – 2, and in inferior 5 segments; in right lung they count 10 segments. In superior lobe of **left lung** count 4 (or 5) segments, and in inferior lobe – 6 (or 5) segments. So, in left lung counts also 10 segments.

Segmental bronchi dichotomically (each on two) divides by bronchi of following orders, while do not pass as far as bronchi, which ventilate lung area, that has a volume  $1\text{mm}^3$ . This area is called by **pulmonary lobule** and bronchi, which ventilate it, are called lobular bronchi. Lesser bronchi contain more connective tissue in their wall and less cartilaginous tissue. From each lobular bronchus 16-18 terminal bronchiole start, their wall does not contain cartilaginous tissue. **Bronchial tree** includes branching of the bronchi starting from the principal bronchi and finishing by terminal bronchioli. Next branching of the bronchial tubes they call **acynus** – morpho-functional lung unit.

*Acynus* contains 14-16 respiratory bronchioli, which are ramification of one terminal bronchioli and they have *alveoli* in the wall. Each respiratory bronchi forms to 1500 *alveolar ductuli*, which terminate in

*alveolar sacculae*. One pulmonary lobule contains 16-18 acynuses. The acynus is covered by network of vessels. Gas-exchange between external environment and blood takes place here.

Parenchyma of the lungs and walls of thoracic cavity covered by serous membrane named **pleura**. Sheet of pleurae which covers the lung called **visceral**, and one which covers inner walls of thoracic cavity named **parietal**. Parietal pleura pass into visceral one in place of *pulmonal ligament* which lies in frontal plane. Parietal pleura divided into some portions: *costal* portion, *diaphragmatic*, *mediastinal* portion and has a *cupola* of pleurae.

Narrow fissure **pleural cavity** contains some serous liquid situated between parietal and visceral pleurae. In areas, where one part of parietal pleurae continues into other, *recesses* form, into which lung deepens during taking a deep breath. They distinguish a costodiaphragmatic recess (largest), diaphragmaticomediastinal recess, *vertebromediastinal* recess and *costomediastinal* recess.

The **MEDIASTINUM** is complex of organs, which is situated between two pleural sacs. Mediastinum is limited – at front by sternum, behind by thoracic part of backbone, from sides – by right and left mediastinal pleurae. Its superior boundary is superior foramen of thoracic cavity, and inferior – diaphragm. Conventionally horizontal plane, carrying out from joint of manubrium sterni and corpus sterni to cartilage between IV-V thoracic vertebrae, divides mediastinum into *superior mediastinum* and *inferior mediastinum*.

In **superior mediastinum** thymus gland, superior cava vein, aortal arch, part of trachea, superior part of thoracic esophageal portion, suitable parts of thoracic lymphatic duct, sympathetic trunks, vagus and phrenic nerves are situated.

**Inferior mediastinum** into its turn subdivides into anterior mediastinum, middle mediastinum and posterior mediastinum. Anterior mediastinum is situated between body by sternum and anterior wall of pericardium. Internal thoracic arteries and veins, lymphatic nodes and vessels are situated here. On middle mediastinum heart, covered by pericardium, phrenic nerves and inner pericardial portions of big vessels are located. Posterior mediastinum is situated between posterior pericardial wall and backbone. Thoracic part of aorta, azygos and hemiazygos veins, sympathetic trunks, splanchnic nerves, vagus nerves, esophagus, thoracic duct, lymphatic nodes passes here.

In surgery mediastinum is subdivided by frontal plane, carrying out through trachea and lung root, into anterior mediastinum and posterior mediastinum. In *anterior mediastinum* heart, ascending aorta, aortal arch, superior vena cava, trachea, lung root elements, phrenic nerves and thymus gland are placed. In *posterior mediastinum* esophagus, descending aorta, inferior vena cava, azygos and hemiazygos veins, splanchnic nerves, sympathetic trunk, thoracic lymphatic duct and vagus nerves are situated.

**BOUNDARIES of LUNGS and PLEURAE.** The *superior border* of lung and pleura (pleura cupola) coincide and situated on 2-3 cm above from clavicle, or on 4-5 cm above from first rib. *Posterior lung boundary* path coincides with posterior pleural border, it passes along paravertebral line from I to XI thoracic vertebrae.

Anterior lung boundary path also coincides with by anterior pleural border. It passes from top of the lung to sternoclavicular joint, passes over middle the manubrium sterni, sternal body from II to IV costal cartilage. Anterior boundary of left lung deviates here to the left, passes on parasternal line till VI rib, where continues into inferior border. Anterior boundary path of right lung passes along the border of left lung, but gradually deviates to the right and on level of the VI costal cartilage on right parasternal line continues into inferior border. Inferior boundary path of right lung is situated 1-2 cm above from inferior border of suitable pleura and passes

- on medioclavicular line – at level of the VI ribs,
- on anterior axillar line – on level of the VII ribs,
- on middle axillar line – on level of the VIII ribs,
- on posterior axillar line – on level of the IX ribs,
- on scapular line – on level of the X ribs,
- on paravertebral line – on level of the XI heads of rib.

Inferior border of right pleura lies 1 cm beneath from lung border. Note that a left lung and pleura inferior boundary path is situated 1-2 cm beneath, than right.

## URINARY SYSTEM

**URINARY SYSTEM** includes pair organ – kidney (organ producing urine) and organs, which store up and bring out urine (ureters, urinary bladder and urethra).

Two **KIDNEYS** are pair parenchymatic organs, which positioned in abdominal cavity behind peritoneum (retroperitoneal position) in right and left *lumbar regions*. Kidney is projected on front abdominal wall in epigastric, lateral and umbilical regions. Right kidney extends from Th 12 vertebra till L 3 lumbar vertebra, left one – from Th 11 vertebra till L 2 lumbar vertebra.

*Posterior surface* of each kidney in superior part adjoins to diaphragm, and in middle and inferior – to muscular bed, which is formed by muscle: psoas major, quadratus lumborum and transverse abdominis. To *anterior surface of left kidney* adrenal gland adjoins above, to superolateral part – spleen, to middle portion – stomach and pancreas, inferiorly – medially is loops of small intestine, and superolaterally – colon. To *anterior surface of right kidney* suprarenal gland adjoins above, to middle part – liver, to medial margin – duodenum, to inferiomedial – loops of small intestine and to inferiolateral – large intestine.

Each kidney has *superior extremity* and *inferior extremity*, *anterior surface* and *posterior surface*, *medial margin* (concave) and *lateral margin* (convex). On medial margin are situated the **renal hilus**, where artery, nerves enter, and vein, lymphatic and **renal pelvis** exit. The renal hilus gets into kidneys, forming a **renal sinus**, filled by *adipose tissue*, also major renal calices and minor renal calices and initial part of renal pelvis are present there.

To parenchyma of the kidney a fibrous capsule adjoins. Outside from last a fatty capsule is situated, which noticeable better near posterior surface of kidney. More outer from adipose capsule renal fascia disposed, which consists of *anterior sheet* and *posterior sheet*. They fused together by superior edges and laterally. From renal fascia stratum of connective tissue draw to fibrous capsule kidney, which fix a kidney. *Peritoneum* adjoins to anterior sheet of renal fascia. Kidneys are fixed by abdominal pressure, renal fascia, muscular bed, renal vessels and nerves, which form a renal leg.

Renal parenchyma consists of **cortex** (superficially) and **medulla** (deep location). In medulla they distinguish 7-10 *renal pyramids*, each from which has a *base* of renal pyramids and a top (*apex*). Last terminates in *renal papilla* where *cribriform area* disposed. The stratum of cortical matter, which form the *renal columns*, lie between pyramids. Cortical

matter consists of **convoluted part**, between which the stratum of medulla are contained. They have a name medullar rays (**radiata part**). Each renal pyramid forms **renal lobe**, and one convoluted part and one radiata part form **renal lobule** in cortex. From top of renal pyramid urine gets into minor renal calices (7-8 in number), from them urine flow into 2-3 major calices, then it moves into renal pelvis, which continues into ureter.

**BLOOD SUPPLYING** of KIDNEYS. Kidney supplied by renal artery, which ramifies in hilus area into anterior branch and posterior branch. Last divide by segmental arteries, and segmental branches – into interlobar arteries, which ramify on border of cortex and medulla into arcuate arteries. Arcuate arteries give off the radial cortical (interlobular) arteries in cortical matter. They give beginning for numerous of afferent vasa, which disintegrate into arterial capillaries and form a **renal glomerulus**. From renal glomerulus moves away efferent vasa, which disintegrates into secondary arterial capillaries, that enshrouds the **tubules of nephron**. Such system of blood supplying, when arterial vessels have double disintegration into capillaries called as renal **miracle arterial rete**. Venous capillaries form in cortical matter stellate venulae, which fall into arcuate veins. Arcuate veins continue into interlobar veins, last form a renal vein, which empties in inferior vena cava.

**FORMING and TRANSPORTATION of URINE within the KIDNEY.** Primary urine arises by filtration blood plasma in **nephron capsule**, which envelops each renal glomerulus. Capsule of renal glomerulus together with glomerulus form a **renal corpuscle**, which is situated in convoluted part of cortex. **Proximal canalicule** of nephron passes from renal corpuscle, which continues into nephron loop (**ansa of Henle**). Last continues into **distal part** of nephron **canalicule** which falling into **collecting duct**. All of above counted urinary tubules braid by thick net of secondary arterial capillaries and by reabsorption secondary urine here is formed. The elements, where urine is formed, compose **function and structural kidney unit – nephron**.

After nephron urine streams into straight **colligens (collecting) tubules**, which terminate by **pappillar foramens** on top of renal pyramid. Last open on **cribriform area** into **minor renal calices**. From small renal calices urine flows into **major renal calices**, which join together and form a **renal pelvis**, last continues into ureter.

**THE URETERS** are pair organ length 25-30 cm, which lies retroperitoneally. Ureter has **abdominal part, pelvic part** and **intramural**

*part*. Last lies in the wall of urinary bladder and opens on its fundus by foramen. Ureters wall consists of external membrane, muscular membrane and mucous membrane. Muscular membrane has external circular and internal longitudinal layers.

Ureter has follow narrow places:

- at transition of renal pelvis into ureter;
- at transition of abdominal part into pelvic part;
- at transition of ureters into urinary bladder.

THE **URINARY BLADDER** lies in cavity of lesser pelvis behind pubic symphysis. It has an *apex*, *body* and *fundus*, which is directed down and posterior. Inferior part forms a *neck*, which continues into urethra. Empty urinary bladder lies extraperitoneally. Full bladder covered by peritoneum anteriorly, laterally and posteriorly – mesoperitoneal position. Fundus of the bladder in male adjoins from below to prostate gland, seminal vesicles and ampoule of ductus deferens, and behind – to ampoule of rectum. In female urinary bladder behind adjoins to vagina and uterus.

Wall of urinary bladder is formed by mucous membrane and well developed submucous stratum, thanks it mucous membrane forms the numerous folds. Between orifices of ureters and internal urethral ostium submucous base absent, so there are no folds here. This place called as triangle of bladder. It is limited above interureteric fold of mucous membrane. Middle membrane of urinary bladder is a muscular membrane, where muscles are arranged in three layers: internal and external longitudinal and middle – circular. The muscular layers form in area of the body muscle-*detrussor* of bladder, and a circular layer most developed in area of internal urethral ostium, forms an internal urethral muscle-*sphincter* (involuntary).

Female **URETHRA** is a tube by length 3-6 cm, which is situated behind pubic symphysis and its *external ostium* opens into vestibule of vagina. Anteriorly and above this foramen covered by striped muscle external urethral sphincter (arbitrary), that belongs to perineal muscles. It has an *internal urethral ostium*, intramural part, external urethral ostium. Muscular membrane of female urethra has a circular layer, which forms internal urethral sphincter, and longitudinal layer.

Structure of masculine urethra will be considered in part of masculine genital organs.

## MALE GENITAL SYSTEM

**MASCULINE GENITAL** subdivide into internal male sexual organs (testicles, epididymis, spermatic cord, ductus deferens, seminal vesicles, prostate gland and bulbourethral gland) and external genital organs (scrotum and penis). Masculine urethra is not only for passing of urine also for passing of sperm.

THE **Testicle** is a pair parenchymatic organ, which is situated in scrotum and produces sperm and masculine sexual hormones. Each testicle has *superior extremity* and *inferior extremity*, *medial surface* and *lateral surface*, *anterior margin* and *posterior margin*.

Testicle is covered by *tunica albuginea* which on posterior margin to get in testicle parenchyma and forms testicle *mediastinum*. Last gives off *septula testis*, which subdivide organ into 150-200 *lobules*. In each lobule the *tubuli seminiferi contorti* are situated (1-2), where masculine sexual cells – spermatozoon produced. Tubuli seminiferi contorti continue into *tubuli seminiferi recti* [straight], and last run into *rete testis* in mediastinum. *Efferent ductuli* (15 – 20) pass from testicle rete transfixing albuginea membrane, continue into head of epididymis and form there the lobules of epididymis. Then spermatozoon runs sufficiently rolled *duct of epididymis*, which reaches into length 2 m. Duct of epididymis passes down to its tail, where continues into ductus deferens.

THE **Epididymis** adjoins to posterior testicle margin. There are *head of epididymis*, *body* and *tail* of epididymis. *Sinus of epididymis* is situated between testicle and body of epididymis.

THE **Ductus deferens** has *scrotal part*, *funicular part*, *inguinal part* and *pelvic part*. It enters to composition of *spermatic cord*, which passes in inguinal canal to internal ring. Here ductus deferens separates from seminal funiculus, then it runs under fundus of urinary bladder. Pelvic part joins with *excretorial duct* of seminal vesicles, forming ampoule of ductus deferens. Attaching ducts generate *ejaculatory duct* (length 2 cm), which passes over prostata and opens into prostatic part of urethra on top of seminal tubercle.

THE **Spermatic cord** is a formation, which consists of arteries and testicle veins, arteries and veins of ductus deferens, pampiniform venous plexus, cremaster muscle, vaginal processes, nerves, lymphatic vessels and ductus deferens.

THE **Prostate** is a musculo-secretory organ, for shape reminds the chestnut, has a *base* of prostate, which adjoins to urinary bladder, and *top* of prostate, which is contact with urogenital diaphragm. It has an *anterior surface* and *posterior surface*, *right* and *left lobes of prostate* and *isthmus* of



prostate, that envelops a urethra. Prostate gland consists of 36 alveolar-tubular glandules, which produce prostate juice and open by numerous ductuli into prostate part of urethra on base of seminal tubercle. Muscular apparatus contributes to extrusion of secret from prostate gland during ejaculation and is as additional (involuntary) urethral sphincter, which withholds the urine in bladder. Gland in old age atrophies and its mass diminishes.

The **Seminal vesicles** produces a seminal liquid, it communicate with ductus deferens. Seminal liquid together with secret of prostate composes part of sperm.

The **Bulbourethral gland** is a pair alveolar-tubular gland, which is situated in thickness of urogenital diaphragm. It has a duct of bulbourethral gland, which passes over bulb of penis and opens into spongy part of masculine urethra. Gland produces a secret, which protects mucous membrane of the urethra from irritation by urine.

The **Scrotum** is external organ, muscular and fascial sac which contains testicles and epididymis. Scrotal septum separates right and left halves. Scrotum is physiological thermostat, which keep temperature of testis at lower level then temperature of body (necessary for normal spermatogenesis).

Scrotal wall contains 7 membranes, which cover a testicle and derive from layers of anterior abdominal wall, namely:

1. *Skin* – has scrotal raphe, numerous folds, pigmented, with hair and contains specific sweat and sebaceous glands.

2. Under skin is situated a *tunica dartos*, which derives from hypodermic adipose tissue and grows together with skin.

3. *External seminal fascia* derives from superficial fascia of anterior abdominal wall.

4. *Cremasteric fascia* derives from proper abdominal fascia.

5. *Musculus cremaster* derives from internal oblique abdominis and transversal abdominal muscles.

6. *Internal seminal fascia* derives from transversal fascia of abdominal wall.

7. *Vaginal tunica* is serous membrane (derives from peritoneum) and consists of visceral plate and parietal plate. Last grows together with albuginea membrane and continues on epididymis. There is furrow-shaped space between both plates is a *vaginal cavity*, which is filled by small amount of serous liquid.

The **Penis** serves removal of the urine and ejaculation. It has a *radix*, *corpus* and *head*. Skin which covers the penis in base of head forms the fold – *preputium*. Last thank to *frenulum* connects with skin of head. Penis

formed by two *cavernous bodies* and *spongy body*. All bodies of penis covered by *tunica albuginea*. Spongy body contains male urethra.

**Masculine urethra** is a tube of length 16-22 cm, in which there distinguish *prostatic part*, *membranous part* and *spongy part*. On its tract a urethra makes a superior (fixed) bend and inferior (free) bend.

Prostatic part passes through the prostate. In this part on the urethral wall is situated *seminal colliculus*, on top of which *prostatic utricle* is disposed. Ejaculatory duct opens at last and prostatic ductuli opens on tubercle base. Intermediate (membranous) part of urethra shorter, it passes through urogenital diaphragm. Described two parts have to fixed position within pelvis and perineum. Spongy part of urethra lies in spongy body of penis and opens by *external urethral ostium* on head top.

Male urethra has following constrictions: external urethral ostium on head of penis; membranous part of urethra; internal urethral ostium. Also a urethra has such expansions: all prostatic part; expansion in bulb of penis; scaphoid fossa in head of penis.

## FEMALE GENITAL SYSTEM

**FEMALE GENITAL ORGANS** subdivide on

- *internal* female sexual organs:  
Ovaries, uterine tubes, uterus and vagina
- *external* female genital organs:

Pudendal area with labia pudenda majora and labia pudenda minora, vestibule of vagina, clitoris and mons pubis.

The **Ovary** is a pair organ, is situated in cavity of lesser pelvis. It has *medial surface* and *lateral surface*, *free margin* and *mesenteric margin*, *uterine extremity* and *tubary extremity*. Ovary is situated in peritoneal cavity, it is covered by embryonic epithelium (not by peritoneum). Ovary attaches to uterus by **proper ovarian ligament**, and to pelvis walls – by the medium of **suspensory ovarian ligament**. Ovaric mesentery approaches to anterior margin, through which the vessels and nerves get into *ovary hilus*. Ovary parenchyma consists of cortex and medulla. Ovule ripens in cortex, where primary *folliculi* are situated, which then transforms into Graaf vesicle. After that as vesicle blows up, an oocyte gets out from the ovary and gets into uterine tube. Vesicle becomes as *corpus luteum* [yellow body].

If there is not fecundation, then corpus luteum transform into *corpus albicans*. In case of fecundation corpus luteum grows up and turns into *corpus luteum verum*, which functions during pregnancy.

The **Uterine tube** is a pair organ is situated in area of superior margin of *ligamentum latum uteri*. Length of each tube is 8-18 cm. There are 4 parts:

- uterine part runs in wall of uterus and opens into uterine cavity by uterine ostium;
- isthmus of uterine tube lies closely to uterus;
- ampulla of uterine tube is greater part of uterine tube;
- infundibulum of uterine tube – is broadened part, which opens by *abdominal foramen* of uterine tube into abdominal (peritoneal) cavity and covered by *fimbria*, one of which – *ovarie fimbria* is longer than other.

Uterine tube is covered from all sides by peritoneum and has its own *mesentery*. Tube has also *muscular membrane* (longitudinal and circular layers) and *mucous membrane*. Fecundation realizes in uterine tube normally, than fertilized ovule passes into uterus.

The **Uterus** is an odd hollow organ, pear-shaped object, which is situated in cavity of lesser pelvis. It has a *fundus*, *body* and *neck* of uterus, which opens into vagina by *uterine ostium*, limited by *anterior labium* and *posterior labium*. Uterine neck divided into *supravaginal portion* and *vaginal portion*. Uterine body has vesical surface (anterior) and intestinal surface (posterior). Place of transition body of uterus into neck is called as isthmus. Anterior uterus surface adjoins to urinary bladder, and posterior – to rectum. Attached to empty urinary bladder body of uterus is tilted forward. Such position is called *anteversio*. Attached to full urinary bladder a fundus and uterus body displaces posteriorly – this is *retroversio*. Also between body and uterus neck is formed a angle, open forward. Such position is called *anteflexio*.

Triangle-shaped cavity of uterus above communicate with uterine tubes, and vagina through the cervical canal and *ostium uteri*.

Wall of uterus consists of three layers:

- mucous membrane (*endometrium*), submucous stratum is absent, so there is no folds on internal surface of uterus;
- muscular membrane (*myometrium*) is formed by smooth muscle and consists of internal, middle and external layers;
- serous membrane (*perimetrium*) is a peritoneum, which covers an uterus from all sides, except part of front surface and lateral margins and supravaginal portion of neck (mesoperitoneal position). Serous membrane

forms **ligamentum uteri latum**, which forms mesentery of uterus, mesentery of ovary and mesentery of uterine tube. Between sheets of ligamentum latum uteri the vessels, nerves, adipose tissue (parametrium) and ligamentum teres uteri are contained. **Ligamentum teres** [round] uteri passes through the inguinal canal to pubis. Also uterus is fixed to pelvic walls by **cardinal ligament**.

The **Vagina** is a tube of 7-9 cm in length that communicates uterine cavity with external genital organs. Upper portion of vaginae envelopes the uterine neck forming vaginal *fornix*. Vagina has anterior and posterior walls and opens by orifice into vestibule. Fold of mucous membrane – *hymen*, closes this orifice in virgins. After defloration remainders of hymen called *caruncle*. Internal mucous membrane contains *columna rugarum* that located along the walls of vagine. Middle coat of vagina – muscular, external one – connective tissue.

### **Female pudenda area**

The *major pudenda labia* limit a *pudenda rima*. Right and left major pudenda labia communicate by each other by the by means of *anterior labial comissura* and *posterior comissura*.

Minor pudental labia are the skin folds without adipose tissue, they lie medially from major pudenda labia. Anterior margin of minor pudental labia bifurcates and forms *prerutium* of clitoris and *frenulum* of clitoris.

The **Clitoris** is by length 2-3 cm, is analogue of cavernous bodies of penis and consists of *head*, *body* and *legs of clitoris*. The legs of clitoris attach to inferior rami of pubic bone.

The Vestibule vaginae are a fissure between minor pudental labia. External urethral ostium, vaginal foramen and ducts of minor and major (Bartolini) vestibular glands open here. Bulbus vestibuli vagina consists of cavernous tissue, which is situated on sides from inferior vaginal end (analogue of sponges body of penis).

## **PERINEUM**

The **PERINEUM** in narrow aspect is the soft tissues situated between anus and external genital. In wide understanding a perineum is a complex of soft tissues, which closes the pelvic outlet.

Perineum is diamond-shaped area, which is limited by coccyx behind, by inferior margin of pubic symphysis anteriorly and by sciatic tuber – laterally. Perineum subdivides by line between right and left sciatic tubers into anterior *urogenital triangle* and posterior *anal triangle*. Anterior triangle lies in oblique frontal plane and urethra passes through it in males, and in female – a vagina and urethra. Posterior triangle lies in horizontal plane, is called by *pelvic or anal triangle* and terminal portion of rectum passes through it.

The *perineal muscles* subdivide into superficial and deep groups.

**Superficial muscles** of urogenital triangle:

- *superficial transversal perineal muscle*, which fixes a perineum;
- *bulbo-spongiosus muscle*, which compresses an entrance into vagina into female, and into males presses out sperm or urine;
- *ischiocavernous muscle*, which assists erections of penis or clitoris.

**Superficial muscles** of pelvic triangle

- *external muscle-sphincter ani*, which consists of striped fibres (voluntary).

Deep muscles of perineum form urogenital and pelvic diaphragm.

**Deep muscles** of urogenital triangle:

- *deep transversal perineal muscle*, which fixes a perineum;
- *sphincter urethrae* formed by circular striped (voluntary) fibres;

**Deep muscles** of pelvic triangle

- *levator ani muscle*;
- *coccygeal muscle*.

**Fasciae** of pelvic area:

Pelvic fascia is continuation of iliac fascia and has a parietal sheet and visceral sheet. *Parietal pelvic fascia* covers levator ani muscle and internal obturatorius muscle. *Visceral pelvic fascia* invests the rectum and other organs. Part of parietal pelvic fasciae, which covers a levator ani muscle above is called *superior fascia of pelvic diaphragm*. *Inferior fascia of pelvic diaphragm* covers the levator ani muscle below. *Membranous layer* limits below external sphincter ani and ischioanal fossa.

Pelvic diaphragm = Deep muscles + Superior fascia + Inferior fascia

The **ischioanal [ischioarectal] fossa** around the wall of the anal canal are large fascia-lined, wedge-shaped space between the skin of anal region

and the pelvic diaphragm. It contains *adiposal body* and *pudendal canal* (*Alcock's*) with nerves and vessels.

### **The urogenital triangle**

*Superior fascia of urogenital diaphragm* is continuation of pelvic fascia and covers from above deep muscles.

A thin and tough sheet, the **perineal membrane** (*inferior fascia of urogenital diaphragm*) stretches between the two sides of the pubic arch and covers below the anterior part of the pelvic outlet. The perineal membrane located between the superficial and deep muscles. The **perineal body** is a fibromuscular mass located in the midpoint between the anal canal and perineal membrane.

Urogenital diaphragm = Deep muscles + Superior fascia + Inferior fascia

*Superficial perineal fascia* (investing fascia) intimately invests superficial muscles of urogenital triangle. Anteriorly it is fused to the *suspensory ligament* of the penis.

*Subcutaneous membranous layer (stratum)* passes superior to the labia majora (in female) and in males continuous with the dartos fascia in scrotum.

**Superficial perineal pouch** (compartment) is the potential space between superficial investing fascia and perineal membrane. In males superficial perineal pouch contains: root of the penis with associated superficial muscles, pudendal vessels and nerves. In females superficial perineal pouch contains: crura of the clitoris and bulb of vestibule, associated with them superficial muscles, pudendal vessels and nerves, greater vestibular glands.

**Deep perineal pouch** (space) is not an enclosed compartment; it is open superiorly. This pouch is bounded below by the **perineal membrane**. In males deep perineal pouch contains: membranous part of urethra, external urethral sphincter muscle, bulbourethral glands, deep transverse perineal muscles, related nerves and vessels. In females the deep perineal pouch contains the: proximal part of urethra, external urethral sphincter muscle, deep transverse perineal muscles, related nerves and vessels.

## **ENDOCRINE SYSTEM**

**ENDOCRINE GLANDS** do not have the ducts, their secret gets immediately into blood. They have prettily abundant blood supplying, and their secret has special chemical and physiological activity. Endocrine system for origin subdivides into glands with endodermal, mesodermal or ektodermal origin.

Glands of *endodermal* origin subdivide into bronchiogenic group (thyroid, parathyroid and thymus glands) and glands developed from epithelium of intestinal tube (endocrine part of pancreas).

Glands of *mesodermal* origin (interrenal system) include interstitial cells of sexual glands and cortex of adrenal glands.

Glands of *ectoderm* group include hypophysis (neurogenic group) and medulla of suprarenal glands and paraganglia.

The **Thyroid gland** is situated in anterior neck area on level of the IV-VI cervical vertebrae and consists of right and left *lobes* communicated by *isthmus*, which continues upward by *pyramidal* portion. Thyroid gland is built by parenchyma, which subdivides into lobuli by septa. Follicles are situated in lobules, which contain hormones of thyroid gland: thyroxine, triiodothyronin, calcitonin. They influence on all types of metabolism.

The **Parathyroid gland** has pair superior parathyroid gland and inferior parathyroid gland that situated on back surface of thyroid gland. Accessory parathyroid glands can be present. Parathyroid gland excretes parathyroid hormone that regulates metabolism of phosphorus and calcium.

The **Thymus** is a central organ of immune system, which is situated in anterior mediastinum on level of the 4th ribs behind manubrium sterni. Behind thymus pericardium is situated. Thymus gland consists of lobes – right and left, which have the lobule that built by cortex and medulla of thymus gland. In medulla T-lymphocyte matter acquire that peculiarities which contribute to protective function.

#### **Endocrine part of sexual glands (testicle and ovary)**

Interstitial (Leidig) cells are situated in parenchyma of testicle. They excrete *testosteron*, which influences on development of secondary sexual signs. Corpus luteum positioned in ovaric parenchyma produces a *progesteron* (it prepares a mucous membrane of the uterus membrane to embryo fixation, detains development of new follicles and stimulates development of mammary glands during pregnancy). Follicular epithelium excretes *estrogen*, which contributes to development of primary female sexual signs (ovary and uterus) also development of secondary female sexual signs, as growth of mammary gland, hair according female type cetera and assists the regulation of menses.

**Endocrine part of pancreas** is represented by *islets of Langerhans*. They produce *insulin* and *glucagon*, that regulate metabolism of carbohydrates, regulative a sugar contents in organism. Attached to insufficient production of these hormonal disease sugar diabetes arises.

The **Adrenal gland** is a pair endocrine gland, which lies on superior extremity of right and left kidneys on level of the Th 11 – Th 12 vertebrae. Each adrenal gland has triangle shape and has anterior surface, posterior surface and renal surface and superior margin and medial margin, and also has the hilus and consists of cortex and medulla matter. Cortex produces mineralocorticoids (aldosterone), glucocorticoids and androgens. Medulla of adrenal glands produces adrenalin and noradrenalin.

The **Paraganglia** are small agglomerations of chromaffin cells, placed closely near abdominal aorta (aortic paraganglia) or in thickness of sympathetic trunk (sympathetic paraganglion). Paraganglia has a function, analogic to function of medulla suprarenal gland.

The neurogenic endocrine glands (hypophysis, epiphysis gland) described in chapter “Central nervous system”.

## CIRCULATORY SYSTEM

The **HEART** is a hollow muscular organ, which is situated in thoracic cavity in middle mediastinum. It has a heart *apex*, which is directed down to the left and heart *base*. Heart has a *sternocostal* (anterior) surface, *diaphragmatic* (posterior) surface, right/left *pulmonary surfaces*. *Coronal sulcus* passes on diaphragmatic and partially on sternocostal surfaces, which marks the border between ventricles and atriums. *Anterior interventricular sulcus* and *posterior interventricular sulcus* pass from coronal sulcus downward and project borders between right and left ventricles. On heart base right and left *auricles* are situated, which envelop the great vessels. On heart base at the anterior from right ventricle *pulmonary trunk* passes, which subdivides into two pulmonary arteries. *Aorta* passes behind pulmonary trunk; behind from aorta from right side *superior vena cava* and *inferior vena cava*, and to the left four *pulmonary veins*.

Heart cavity subdivides on right and left **atriums** and right and left **ventricles**. Left chambers of heart are arterial and in adult do not communicate with right venous half of heart. Two blood circles exist.

Big circle or *systemic circulation* of the blood starts in left ventricle by aorta and terminates in right atrium by vena cava superior and inferior.



Systemic circulation of the blood provides by arterial blood all of organs and tissues.

The small circle or *pulmonary circulation* of the blood begins by pulmonary trunk from right ventricle and terminates in left atrium by 4 pulmonary veins. Venous blood flows in arteries of pulmonary circulation and arterial (oxygenated) blood – in veins.

**Right atrium** consists of own atrium and *right auricle*.

Internal wall is smooth, but in auricle *pectinate muscles* are situated. Right atrium receives the superior and inferior venae cavae, which open by *foramen of inferior vena cava* and *foramen of superior vena cava*. *Intervenous tubercle* is situated between these foramens. Broadened posterior area, where two venae cavae fall is called as *sinus venae cavae*. Right atrium is separated from left by *interatrial septum*, where *oval fossa* is situated. It is limited by *limbus* of oval fossa. Atrium communicates by right ventricle through the *right atrioventricular ostium*. Foramen of *coronal sinus* situated between last and foramen of inferior vena cava. Alongside are contained foramens of *venarum minimarum*.

**Right ventricle** consists of own ventricle and *conus arteriosus* – superior part, which continues through the *ostium of pulmonary trunk* into pulmonary trunk. The right and left ventricles are separated by *interventricular septum*, which has muscular part (greater) and membranous part (lesser). On internal surface of right ventricle are situated the *trabeculi carneae*, which carry cone-shaped *anterior, posterior* and *septal pappillar muscles*. From top of these muscles *chordae tendineae* start and terminate at cusps of right atrioventricular valve.

*Right atrioventricular ostium* closes by **right atrioventricular (tricuspidal) valve**, which consists of *anterior cusp, posterior cusp* and *septal cusp* edges of which attach to *chordae tendineae*. During contraction of atria blood stream presses the cusps to the wall of ventricle. During contraction of ventricles free edges of cusps close up but do not pull out because they are kept by chordae tendineae from ventricle. *Ostium of pulmonary trunk* closes by **valve of pulmonary trunk**, which consists of *right, left and anterior semilunar valvulae*, which have on superior margin the *nodules* of semilunar valvulae. Nodules assist to compact closing up. Between each semilunar valvula and pulmonary trunk wall *sinuses of pulmonary trunk* are situated.

**Left atrium** has an irregular cube shape; anterior wall forms a *left auricle*. Internal wall surfaces of left atrium is smooth and only in auricle area *pectinate muscles* are situated. The *ostia of 4 pulmonary veins* open

into left atrium. Left atrium communicates with left ventricle by the means of *left atrioventricular ostium*. *Oval fossa* makes a mark poorly on *interatrial septum*.

**Left ventricle** is the largest heart chamber, its wall forms larger part of diaphragmatic surface. Internal surface contains the *trabeculi carneae*, which attach *anterior papillary muscle* and *posterior papillary muscle*. The tops of these muscles by means of *chordae tendineae* hold the *cusps of mitral valve*.

*Left atrioventricular ostium* closes by **left atrioventricular (bicuspidal) valve [valva mitralis]**, which consists of *anterior cusp* and *posterior cusp* edges of which attach to *chordae tendineae*. From left ventricle aorta starts. *Aortic ostium* closes by **aortic valve**, which consists of *right, left and posterior semilunar valvulae*, which have on superior margin the *nodules* of semilunar valvulae. Between each semilunar valvula and aorta walls are situated *aortic sinuses*.

**Wall of heart** consists of internal layer – endocardium, muscular layer – myocardium and external layer – epicardium.

**Endocardium** covers heart cavity from within. Its double sheets forms aortic and pulmonary trunk valves, cusps of right and left atrioventricular valves.

**Myocardium** (middle layer) is formed by muscular tissue, which consists of cardiomyocytes. Muscular fibers of atria and ventricles start from fibrous tissue, which enters to composition of soft **heart skeleton**. Last includes *right and left fibrous rings*, that are situated around right and left atrioventricular ostia, *right fibrous triangle* and *left fibrous triangle*, that are situated around valva of aorta and valva of pulmonary trunk, and membranous part of interventricular septum.

**Myocardium of atria** consists of two layers: superficial, which is common for both of atria and consists of *circulation fibres*, and deep layer, which consists of *longitudinal bundles* and is separate each from other.

**Myocardium of ventricles** consists of three layers: external, middle and internal. *External (oblique) layer* originates from fibrous annuli, continues downward till apex cordis where forms **vortex cordis** and passes into *internal layer* of opposite side with *longitudinal fibres*. So, external and internal layers are common for both ventricles and *middle (circular) layer* separate for each ventricle.

External heart membrane **epicardium** is *visceral sheet* of serous pericardium. Epicardium covers a heart, initial departments of aorta and pulmonary trunk, and also terminal departments of venae cavae and

pulmonary veins. Visceral sheet passes into parietal sheet of serous pericardium on these vessels.

**Conducting heart system** consists of atypical muscular fibers, which have ability to carry impulses from nerves of heart to myocardium of atria and ventricles. Centre of conducting heart system includes two ganglia:

1. *Sinoatrial ganglion* (Keith and Flack) disposed in wall of right atrium between foramen of superior vena cava and right auricle. This ganglion gives off the branches to myocardium of atria and directs a heart contraction rhythm.

2. *Atrioventricular ganglion* (Tawara) lies in thickness of inferior department of interatrial septum. This ganglion continues in *atrioventricular fascicle* (His) which communicates myocardium of atria and ventricles. Fascicle subdivides on *right leg* and *left leg* in muscular part of interventricular septum, the terminal branches of which (Purkinje fibres) terminate in ventricles myocardium.

**Blood supplying of the heart** realizes by means of *right coronal artery* and *left coronal artery*, which take their beginning from *aorta bulbos* in suitable *sinuses*. *Right coronal artery* passes to the right under right auricle, lies into coronal sulcus and passes on posterior interventricular sulcus, where anastomose with circumflex branch of left coronal artery. Branches of right coronal artery supply wall of right ventricle and atrium, back portion of interventricular septum, papillary muscles of right ventricle and ganglia of conducting heart system. *Left coronal artery* passes under left auricle where divides into two branches: *anterior interventricular branch* and *circumflex branch*. Last rounds a heart in coronal sulcus and passes on posterior surface where anastomoses with right coronal artery, forming *circular arterial anastomose* of arterial heart vessels. *Anterior interventricular branch* passes on same name heart sulcus to the apex, where anastomoses with terminal portion of right coronal artery, forming *longitudinal arterial heart anastomose*. Left coronal artery supplies wall of left ventricle, anterior wall of right ventricle, wall of left atrium and larger half of interventricular septum.

**Venous system of the heart** carries largest part of deoxygenated blood into coronal sinus. Some veins empty in it:

- *greater cardiac vein [vena cordis magna]*, which passes in anterior interventricular sulcus and coronal sulcus;
- *lesser cardiac vein [vena cordis parva]*, which passes in right part of coronal sulcus;

- *middle cardiac vein* [*vena cordis media*] passes in posterior interventricular sulcus;
- *posterior vein of left ventricle*;
- *oblique vein of left atrium*.

There are *venae minimae* (Tebezia) and *anterior venae*, positioned in myocardium of right atrium.

**Innervation of the Heart.** *Sympathetic* fibers pass from sympathetic trunk and form the superior, middle and inferior cervical cardiac nerves. Also thoracic department of sympathetic trunk gives off the thoracic cardiac sympathetic nerves. They fasten cardiac contractions and add their amplitude, broaden the coronal vessels. The *parasympathetic* fibers pass in composition of superior, inferior and thoracic cardiac branches of vagus nerve. They slow a rhythm of cardiac contractions, reduce their amplitude and narrow luman of coronal arteries. The *sensory* fibers from heart wall receptor pass in composition of cardiac nerves and cardiac branches to spinal cord and brain.

The heart nerves form *superficial extraorgan cardiac plexus* and *deep extraorgan cardiac plexus*. The branches of extraorgan cardiac plexus continue into one *intraorgan cardiac plexus*, which conventionally subdivides on subepicardial plexus, intramuscular plexus and subendocardial plexus. Subepicardial plexus is reach developed.

**Topography of the heart.** Heart is situated in thoracic cavity; two thirds are disposed to the left from middle line and one third on the right side. From sides a heart is covered by pleural sacs, and lesser its front surface adjoins to sternum and costal cartilages.

*Superior heart border* passes on line, which connects upper margins of third costal cartilages. *Right heart boundary path* passes from III right costal superior margin to V right costal cartilage. *Inferior heart border* passes on line, which passes from right V right costal cartilage to apex cordis. *Apex cordis* projects into left V intercostal space 1-1,5 cm medially from medioclavicular line. *Left heart boundary path* lies through superior margin of left III costal cartilage to apex cordis. **Palpitation sound** of *bicuspidal valve* is listened in apex cordis area. *Aortic valve* is listened into second intercostal space to the right from sternum. *Valve of pulmonary trunk* – into II intercostal space to the left from sternum. *Right atrioventricular (tricuspidal) valve* is listened by base xyphoid process of sternum to the right (joint of IV costal cartilage with sternum).

Heart is enveloped by **pericardium**, which consists of fibrous and serous portions. *Fibrous pericardium* near base of big vessels passes into

their external membrane. *Serous pericardium* has parietal lamina that covers fibrous pericardium from within and visceral lamina that covers surface of the heart and is known as *epicardium*. Parietal lamina passes into visceral lamina closely the base of heart. There is space like fissure between two laminae – *pericardial cavity* with small amount of serous liquid that prevents friction during palpitation. There are two deepening in pericardial cavity: transverse sinus and oblique sinus. *Transverse sinus* is bordered in front by aorta and pulmonary trunk, behind by superior vena cava. *Oblique pericardial sinus* is situated on the diaphragmatic surface between pulmonary veins on the left and inferior vena cava on the right.

## ARTERIAL SYSTEM

**AORTA** is the largest arterial vessel of systemic circulation. It subdivides on ascending part of aorta, aortic arch and descending part of aorta, which has thoracic and abdominal portions of aorta.

**Ascending part of aorta** leaves the left ventricle behind left margin of sternum on level III intercostal space. In initial part it has expansion *aortic bulb*, in which three aortic *sinuses* are contained. Ascending part of aorta lies behind and a little to the right from pulmonary trunk, rises up and to level of second right costal cartilage passes into arc.

The **Arch of the Aorta** turns posteriorly to the left from second costal cartilage to left side of fourth thoracic vertebral body, where passes into descending aorta. Between concave aortic arch surface and pulmonary trunk on beginning of left pulmonary artery is situated obliterated Botalli duct – *arterial ligament*. From convex aortic arch surface starts to from the right to the left: brachiocephalic trunk, left common carotid and left subclavian artery.

**Descending aorta** has *thoracic part of aorta*, which passes in posterior mediastinum and lies to the left from bodies of thoracic vertebrae and *abdominal part of aorta*, which starts on level of XII thoracic vertebra, passes through *aortic hiatus* of diaphragm, and extends to level of IV lumbar vertebra. *Abdominal part of aorta* is disposed front of anterior surface of lumbar vertebrae to the left from midline. Here abdominal aorta gives off the pair parietal branches, pair and odd visceral branches and finishes in bifurcation, dividing into two common iliac arteries.

### **Branches of aortic arch**

**Brachiocephalic trunk** begins from aortic arch on level of right II costal cartilage. It passes upward and to the right of and on level of right sterno-clavicular joint divides into two terminal branches – right common carotid and right subclavian arteries.

**Common carotid artery** passes behind sternocleidomastoid muscle upward on front of transverse processes of cervical vertebrae and does not give off any branches. On the level of upper edge of thyroid cartilage common carotid artery divides into external carotid artery and internal carotid artery. This place called *bifurcation* of carotid artery. There are *carotid sinus* and *carotid glomus* here.

**External carotid artery** starts from common carotid artery in carotid triangle on level of superior margin of thyroid cartilage. On level of mandibular neck this artery divides by its two terminal branches. On its extent external carotid artery gives off branches of anterior, posterior, medial and terminal groups.

Follow arteries belong to **anterior group**:

1. **superior thyroid artery** supplies thyroid gland and gives off a *superior laryngeal artery*, which supplies muscles and mucous membrane of the larynx;

2. **lingual artery** supplies sublingual salivary gland and gives off *dorsal branches* and *deep lingual artery*, which supplies muscles and mucous membrane of the tongue;

3. **facial artery** in submandibular triangle gives off the branches to submandibular salivary glands, *ascending palatine artery* to velum and *tonsillar branch* to palatine tonsils. Bending over margin of mandible in front of masseter muscle, it gives off on face *superior labial artery* and *inferior labial artery*. By terminal branch of facial artery is *angular artery*, which passes to medial eye angle and anastomoses with *dorsal nasal artery* from system of internal carotid artery (ophthalmic artery).

**Posterior group** includes:

1. *sternocleidomastoid* branch passes to same named muscle and can start from superior thyroid artery, or from occipital artery;

2. *occipital artery* supplies posterior skin occipital region;

3. *posterior auricular artery* supplies outer and middle ear (by *posterior tympanic artery*).

Ascending pharyngeal artery belong to **medial group**. It supplies pharynx, deep neck muscles, cerebral dura mater (*posterior meningeal artery*) and tympanic cavity (by *inferior tympanic artery* through fossula petrosa).

Follow arteries belong to **terminal branches**:

**1) Superficial temporal artery**, which is continuation of external carotid artery, passes in front of auricle into temporal area and on level of supraorbital margin of frontal bone subdivides into *frontal branch* and *parietal branch*, which feed muscles and skin in frontal and parietal area. On this course superficial temporal artery gives off the branches for parotid salivary gland (*r. parotideus*), zygomaticoorbital artery, for facial muscles (*a. transversa faciei*), for auricle (*rr. auriculares anteriores*) and for temporal muscle (*a. temporalis media*);

**2) Maxillary artery** is a largest branch of external carotid artery. According to topography in it one can pick out a mandibular portion, pterygoid portion and pterygopalatine portion.

a) The first **mandibular portion** gives off branches to temporo-mandibular joint

- *deep auricular artery* supplies external ear also tympanic membrane
- *anterior tympanic artery* supplies the tympanic cavity
- *middle meningeal artery* passes through spinous foramen into skull and feeds dura mater

- *inferior alveolar artery* runs into mandibular canal supplies teeth and gingivae of lower jaw and continue as *mental artery* in mental region.

b) The **second portion of maxillary artery** gives off the branches to masticator and buccal muscles (*masseteric, deep temporal arteries, pterygoid branches, and buccal artery*).

c) The **third portion of maxillary artery** gives off :

- *Posterior superior alveolar arteries* pass through alveolar canals of maxilla, supply teeth of upper jaw: molars and premolars with parodont

- *infraorbital artery* runs through inferior orbital fissura and infraorbital canal, gives off *anterior* and *middle superior alveolar arteries* that supply maxilla, upper teeth and gingivae, face muscles

- *sphenopalatine artery* to mucous membrane of the nasal cavity

- *descending palatine artery* (for palatine)

- *major and minores palatine arteries* (for palatine)

**Internal carotid artery** disposes at first laterally and behind then medially from external carotid artery, passes vertically upward [cervical portion] and get into external foramen of carotid canal (temporal pyramid). Passing in carotid canal [petrosal portion], it gives off the *caroticotympanic arteries* for tympanic cavity. After passing out from the internal foramen of canal internal carotid artery lies into carotid sulcus of sphenoid bone, passes through the cavernous sinus [cavernous portion of artery], on level of optic canal gives off an *ophthalmic artery* and divides into branches:

*anterior cerebral artery and middle cerebral artery, posterior communicating artery.*

**Ophthalmic artery** together with the optic nerve passes into orbit. The terminal branches of ophthalmic artery are *medial palpebral artery* and *dorsal nasi artery*, which anastomoses with *angular artery* from of external carotid artery. Also Ophthalmic artery gives off branches:

- *Conjunctival arteries*
- *Lacrimal arteries, Muscular rami* supply glands and other auxiliary apparatus of eye.
- *Arteria centralis retinae, Anterior ciliary arteries, Long and Short posterior ciliary arteries* supply eyeball
- *Ethmoid arteries* for mucous membrane of the nose and paranasal sinuses.

**Anterior cerebral artery** supplies medial surface of frontal, parietal and partly occipital lobes of brain, it anastomoses with same artery of contrary side by the medium of *anterior communicating artery*.

**Middle cerebral artery** is a largest branch of internal carotid artery, supplies superolateral hemispheres surface of cerebrum and insula.

**Anterior choroid artery** gets into inferior horn of lateral ventricle, and then – into third ventricle, and forms choroid plexus.

*Posterior communicating artery* connects internal carotid artery with posterior cerebral one.

Left **Subclavian artery** starts from aortic arch and right one – from the brachiocephalic trunk. It leaves thoracic cavity through the *superior aperture*, rounds a pleura cupola and gets into interscalenus space. Then artery lies under clavicle into same name sulcus of first rib and runs into axillary cavity, where has a name axillary artery. Subclavian artery conventionally subdivides into three portions: before interscalenus space, in interscalenus space and after interscalenus space.

Before interscalenus space subclavian artery gives off the following branches:

**Vertebral artery** is a largest branch of subclavian artery, passes in foramens of transversal processes of cervical vertebrae, transfixes a atlanto-occipital membrane and dura mater encephali and through occipital foramen magnum gets into skull cavity. Behind pons this right and left artery flows together and forms *basillar artery*. Vertebral artery gives off *anterior spinal artery* and *posterior spinal artery*, and *posterior inferior cerebellar artery*. From basillar artery start: *anterior inferior cerebellar artery, labyrinthic artery, pontini arteries* and *artery mesencephalic*.



Vertebral artery together with anterior spinal arteries forms around medulla oblongata **circle of Zakharchenka**.

Basillar artery on level of anterior margin pons ramifies on two *posterior cerebral arteries*, which supply occipital lobes of cerebrum. Posterior cerebral arteries connect by *posterior communicating artery* with *internal carotid artery*. Also thank to *anterior communicating* and *cerebral arteries* **arterial circle of brain (circle of Willis)** forms.

**Internal thoracic artery** begins from inferior surface of subclavian artery and passes along I-VII cartilages of ribs near sternum, where disintegrates on two terminal branches are *musculo-phrenic artery* and *superior epigastric artery*. Internal thoracic artery gives off *rami* for *thymus*, *bronchi*, *pericardium* and *sternum*. Also from this artery moves away *rami mammarii*, *tracheal rami*, *anterior intercostal branches*, which supply intercostal muscles. *Superior epigastric artery* gets into sheath of rectus abdominal muscle, supplies this muscle and anastomoses with inferior epigastric artery on navel level.

**Thyro-cervical trunk** is has length 1-2 cm and subdivides into four branches: *inferior thyroid artery*, (supplies thyroid gland, cervical esophagus department, cervical trachea portion and *inferior laryngeal artery* reaches mucous membrane of the to larynx), *ascending cervical artery* (to neck muscles), *superficial cervical artery* (to trapezius, rhomboid and other neck muscles) and *suprascapular artery* (for supraspinatus and infraspinatus muscles).

*In interscalenus space* subclavian artery gives off *costo-cervical trunk*, which ramifies into *deep cervical artery*, which supplies semispinalis capitis and cervicis muscles and *suprema intercostal artery*, which ramifies into I and II intercostal spaces, supplying intercostal muscles.

*After interscalenus space* subclavian artery gives off *transverse colli artery*, which continues into *dorsal scapulae artery*. They supply rhomboid, levator scapulae and shoulder girdle muscles.

**Axillary artery** is immediate continuation of subclavian artery. It passes in depth of armpit and covered by trunks of brachial plexus. According to topography of anterior wall of axillary cavity, axillary artery subdivide into three portions: in clavipectoral triangle, pectoral triangle and subpectoral triangle.

In *clavipectoral triangle* axillar artery gives off:

- superior thoracic artery, which ramifies in intercostal I-II intercostal muscles;

- thoracoacromial artery, which supplies acromial process, acromioclavicular joint, subclavius muscle, deltoid muscle, major and minor pectoral muscles.

In *pectoral triangle* from axillar artery moves away

- *lateral thoracic artery*, which supplies anterior serratus muscle and gives off the *branches to mammary gland*.

In *subpectoral triangle* axillar artery gives off:

- *anterior circumflex humeri artery* – passes in front of surgical neck of humerus supplies shoulder joint and deltoid muscle;

- *posterior circumflex humeri artery* – passes through quadrilaterum foramen and, anastomosing with previous artery, supplies shoulder joint and muscles, that are situated around it;

- *subscapular artery*, which divides into *thoracodorsal artery* (supplies latissimus dorsi muscle and teres major muscle) and *circumflex scapulae artery* (passes through trilateral foramen and supplies muscles of back scapular surface ).

**Brachial artery** is immediate continuation of axillary artery and, starting to on level of inferior margin of major pectoral muscle, passes in medial biceps brachii sulcus, and in cubital fossa subdivides into its terminal branches are radial and ulnar.

Brachial artery gives off:

- *deep brachial artery* – takes beginning from upper third of brachial artery, passes along the radial nerve in radial canal, where gives off the branches to posterior brachial muscles group and to deltoid muscle. Deep brachial artery ramifies into *middle collateral artery*, which anastomoses with recurrent interossea artery, and *radial collateral artery*, which anastomoses with radial recurrent artery;

- *superior ulnar collateral artery* starts from brachial artery beneath deep brachial artery and passes to posteromedial surface of elbow joint, where anastomoses with posterior branch of ulnar recurrent artery;

- *inferior ulnar collateral artery* starts from brachial artery in inferior its third, passes to anteromedial surface of elbow joint, where anastomoses with anterior branch of ulnar recurrent artery.

All named above collateral arteries, anastomosing with recurrent arteries, take part in forming of **arterial cubital rete**, from which blood supplies joint and muscles around it.

Arteries of forearm and hand. Forearm and hand originate from terminal branches of brachial artery – radial and ulnar arteries.

**Radial artery** lies in radial antebrachial sulcus and, rounding a styloid process of radius bone, passes on dorsal surface of hand, and then through the first interosseous space gets on palm, where its terminal portion, anastomosing with deep palmar branch from ulnar artery, makes *deep palmar arc*. Last gives off palmar metacarpeal arteries which anastomose with branches of *superficial palmar arch* – common palmar digital arteries.

**Radial artery** gives off follow branches:

- *radial recurrent artery*, which anastomoses with radial collateral artery;
- *superficial palmar branch*, which anastomoses with terminal portion of ulnar artery, and *muscular branches*, which supply forearm muscles;
- *dorsal carpal branch* and *palmar carpal branch* take hand in formation of dorsal carpal rete and palmar carpal rete;
- *first dorsal metacarpeal artery* gives branches into three *dorsal digital arteries*, which feed dorsal surface of I and II fingers;
- *principal artery of pollex*, which ramifies on three *proper palmar digital arteries* to I finger and radial side of palmar surface of II finger. From dorsal carpal net four dorsal metacarpeal arteries start, each from which subdivides into two dorsal digital arteries. Last supply dorsal surfaces II-V of fingers.

**Ulnar artery** lies into ulnar antebrachial sulcus and through the carpal canal gets on palm, where its terminal portion anastomoses with superficial palmar branch from radial artery and forms *superficial palmar arc*.

Ulnar artery gives off:

- *ulnar recurrent artery*, which subdivides into *anterior branch* and *posterior branch*. They anastomose with collateral brachial arteries *inferior* and *superior* and take hand in formation of *cubital articulate net* (rete articulare cubiti);
- *common interossea artery*, which divides into *anterior interossea artery* and *posterior interossea artery*. These arteries supply deep forearm muscles and take hand in formation of wrist nets. *Recurrent interossea artery* moves away from posterior interossea artery, then anastomoses with media collateral artery, and is take part in forming of *cubital articulate net* (rete articulare cubiti);
- *dorsal carpal branch* and *palmar carpal branch* take hand in formation of dorsal carpal rete and palmar carpal rete;
- *deep palmar branch*, which anastomoses with terminal portion of radial artery and takes hand in formation of *deep palmar arc*.

From *superficial palmar arch* three *common palmar digital arteries* move away, which ramify each on two *proper palmar digital arteries*.

From *deep palmar arch* 4 *palmar metacarpeal arteries* move away, which fall into *common palmar digital arteries* and into principal artery of pollex in area of their division into proper palmar digital arteries.

### Branches of **thoracic aorta**

Parietal branches and visceral branches there distinguish in thoracic part of aorta.

Follow arteries belong to parietal branches of thoracic part of aorta:

- *superior phrenic arteries* are pair, pass to lumbar part of diaphragm;
- *posterior intercostal arteries* are 10 pairs in number, which pass in III-XI intercostal spaces and supply intercostal muscles, ribs, skin, breasts. Lower posterior intercostal arteries supply also muscles of anterior abdominal wall. X posterior intercostal artery is situated under posterior margin of XII rib and has a name of *subcostal artery*. From each posterior intercostal artery move away the sprigs to muscles and posterior skin, to membranes of spinal cord and *lateral and medial cutanei* branches to breasts skin and abdominal, sprigs to mammary gland.

Follow arteries belong to visceral branches of thoracic part of aorta:

- *bronchial branches* – to trachea, bronchi and lung;
- *esophageal branches* to esophagus;
- *pericardial branches* to posterior part of pericardium;
- *mediastinal branches* supply connective tissue and lymphatic nodes in posterior mediastinum.

### Branches of **ABDOMINAL AORTA**

They subdivide into parietal and visceral. The Visceral branches into its turn subdivide into pair and odd.

### **ARTERIES OF PELVIS**

<i>Visceral branches</i>		<i>Region of supplying</i>
Paire branches	a. suprarenales medii	Suprarenal glands
	a. renalis	Kidney, Suprarenal glands
	a. testicularis or a. ovarica	Testis or Ovary
<b>1. Truncus coeliacus Th – XII</b>		
Unpair branches	1. a. <b>Gastrica sinistra</b>	Lesser curvature of stomach
	rr. Oesophageales	Oesophagus (abdominal part)
	2. a. <b>hepatica communis</b>	Dexter et sinister lobes of the liver
	a. hepatica propria (rr. Dexter et sinister)	
	a. cystica	Gallblader
	a. gastroduodenalis	
	a. gastroepiploica dextra	Greater curvature of stomach, greater omentum
	aa. pancreatoduodenales superiores	Pancreas, Duodenum
	3. A. <b>lienalis (splenic)</b>	Lien
	a. gastricae breves	Fundus of stomach
	rr. pancreatici	Pancreas
a. gastroepiploica sinistra	Greater curvature of stomach, greater omentum	
<b>2. A. mesenterica superior Th-XII – L-I</b>		
aa. pancreatoduodenales inferiores	Pancreas, Duodenum	
aa. jejunaes	Jejunum	
aa. ilei	Ileum	
a. ileocolicaaa: (a. Caecales, a. Appendicularis)		
a. colica dextra	Ascending colon	
a. colica media	Transverse colon	
<b>3. A. mesenterica inferior L-III</b>		
a. colica sinistra	Descending colon	
aa. sigmoideae	Sigmoid colon	
a. rectalis superior	Rectal ampulla	

## ARTERIES OF PELVIS

On level IV of lumbar vertebra abdominal aorta divides into two **common iliac arteries** – *aorta bifurcation*.

Common iliac artery passes downward into lesser pelvis and on level of sacro-iliac joint divides into *external iliac artery* and *internal iliac artery*:

Arteries of pelvis: **a. iliaca communis** (*starts on the level of L<sub>IV</sub>*)

<b>A. ILIACA INTERNA</b> ( <i>level of the sacroiliac joint</i> )			
<i>Arteries</i>	<i>Topographical features</i>	<i>Their twigs</i>	<i>They supply</i>
a. iliolumbalis		r. lumbalis, r.spinalis	Psoas, quadratus lumborum
		r. iliacus	Iliacus
aa. sacrales laterales		r.spinalis	Membranes of the spinal cord
a. Glutea superior	<b>Suprapiriform foramen</b>		Gluteal muscles
Umbilical artery	<i>forms medial umbilical ligament</i>	aa. Vesicales superiores	Muscles of the anterior abdominal wall, urinary bladder
		rr. Ureterici	Ureter
		a. Ductus deference	Ductus deference
aa. Vesicales inferiores		urinary bladder, seminal vesicles, prostate or vagina	
a. uterina		r. Tubarius	Uterus, Uterine tubes
		r. Ovaricus	Ovary
a. rectalis media			Rectum
a. pudenda interna	<b><i>Passes through Infrapiriform foramen,</i></b>	a. rectalis inferior	Rectum
	<i>Lesser sciatic foramen</i>	a. bulbi (vestibuli or penis)	Bulb (vestibule or penis)
	<i>In ischiorectal fossa and perineum</i>	aa. profunda and dorsalis (penis, clitoridis)	Penis, Clitoris
a. obturatoria	r. Pubicus + r. Obturatorius (from art. epigastrica inferior) = "corona mortis"		Muscles of the thigh and pelvis, hip joint
a. Glutea inferior	Infrapiriform foramen	a. comitans n. ischiadici	Gluteus maximus
<b>A. ILIACA EXTERNA</b>			
a. epigastrica inferior	<i>forms lateral umbilical ligament</i>	a. cremasterica a. Lig. Teretis uteri	Rectus abdominis, funiculus seminalis, Lig. Teres uteri
a. circumflexa ilium profunda			Abdominal wall muscles

under inguinal ligament through lacuna vasorum laterally from femoral vein. Then femoral artery runs downward in iliopectineal sulcus and anterior femoral sulcus. It enters into adductor canal and exits from canal in popliteal fossa where continues into popliteal artery.

**Femoral** artery gives off:

- *superficial epigastric artery* passes on anterior abdominal wall and supplies a inferior portion of external oblique muscle aponeurosis and skin;

- *superficial circumflexa iliac artery* passes laterally and ramifies in muscles and skin near superior anterior iliac spina;

- *deep femoral artery* gives off *medial circumflex femoral artery* and *lateral circumflexa artery*, three *perforating arteries*, that supply posterior group of thigh muscles;

- *descending genu artery* begins from femoral artery in adductor canal, passes through the tendinous hiatus of this canal and passes down together with saphenus nerve to knee-joint, where takes hand in formation of articulate knee net (rete articulare genus).

**Popliteal artery** is continuation of femoral artery, passes in advance of tibial nerve and popliteal vein and on level of inferior margin of popliteal muscle divides into anterior tibial artery and posterior tibial artery.

Popliteal artery gives off the following branches:

- superior medial and lateral genu arteries;

- middle genu artery;

- inferior medial and lateral genu arteries.

All these arteries participate in feeding of knee-joint and muscles around it.

**Posterior tibial artery** continues from popliteal artery, passes in cruropopliteal canal, under musculus soleus, behind medial malleolus, passes in separate fibrous canal under flexors tendom retinaculum on sole, where subdivides into medial plantar artery and lateral plantar artery.

Branches of posterior tibial artery:

- *fibular artery* passes in inferior musculofibular channel, supplies peroneal muscles and behind lateral malleolus divides into lateral maleolar branches and calcaneal branches;

- *medial malleolar branches* take hand in formation of medial maleolar rete;

- *muscular branches* supply deep and superficial muscles of posterior group in shin;

- *fibular circumflexa branch* runs laterally from beginning of tibial artery and rounding a head of fibula joins to articulate knee net;

- **lateral plantar artery** is a terminal branch of posterior tibial artery, lies in lateral plantar sulcus, passes medially and, anastomosing with deep plantar branch (from dorsal pedis artery), forms plantar arc. Lateral plantar artery gives off four plantar metatarsal arteries, which continue into common plantar digital arteries. Last subdivide into two proper plantar digital arteries, which supply skin of both sides of each finger on sole;

- **medial plantar artery** is second terminal branches of posterior tibial artery (has a deep branch and superficial branch), lies into medial plantar sulcus and supplies muscles of medial plantar group, anastomosing with first dorsal metatarsal artery.

**Anterior tibial artery** begins from popliteal artery in popliteal fossa, runs at cruropopliteal canal and makes perforating in superior portion of interossea membrane. Artery lies on anterior surface of interossea membrane between muscles of anterior shin group and, passing under retinaculum of extensor muscles, continues on foot under name of dorsal pedis artery.

**Anterior tibial artery** gives off the following branches:

- *posterior recurrent tibial artery* takes hand in formation of articulate knee net;

- *anterior recurrent tibial artery* takes hand in formation of articulate knee net;

- *muscular branches* supply anterior shin muscles group;

- *anterior medial maleolar artery* takes hand in formation medial maleolar net;

- **dorsal pedis artery** – continuation of anterior tibial artery, directs to first interossea space of metatarsus, where subdivides into *first dorsal metatarsal artery* and *deep plantar artery*. First dorsal metatarsal artery subdivides into three *dorsal digital arteries*, which pass on both sides of dorsal surface of halux and medial side of second finger. *Deep plantar branch* passes through first intermetatarsal space on sole and, anastomosing with plantar arc. Dorsal pedis artery gives off also the *lateral tarsal artery* and *medial tarsal artery* to lateral and pedis margins medial and *arcuate artery*, from which the *dorsal metatarsal arteries I-IV* start. Each from these arteries subdivides into two *dorsal digital arteries*, which supply dorsal surfaces of neighbouring fingers.

## VENOUS SYSTEM



## SYSTEM OF SUPERIOR VENA CAVA

**Superior vena cava** is generated by reason of confluence of right and left brachiocephalic veins behind joint of cartilage of first right rib with sternum. Superior vena cava on level of third right cartilage empties into right atrium. Azygos vein empties into superior vena cava from right side.

**Brachiocephalic veins** form by the confluence of subclavian vein, internal jugular and sometimes External jugular vein. This place is called as *venous angle*, where thoracic lymphatic duct empties (left side), and right lymphatic duct (right side). *Inferior thyroid veins* from thyroid plexus, *inferior laryngeal vein* and *thymic vein*, *pericardial veins* from pericardium, *bronchic veins* and *esophageal veins* from esophagus fall into brachiocephalic veins.

**Azygos vein** continues into thoracic cavity from *right ascending lumbar vein*. Azygos vein receives *posterior intercostal veins*, *esophageal veins*, *bronchic veins*, *pericardial veins* and *mediastinal veins*, also *hemizygos vein*.

**Internal jugular vein** is a largest vessel, which drainage blood from area of head and neck. Internal jugular vein originates from *sigmoid sinus* of dura mater encephali, where it begins on level of jugular foramen by superior bulb and lies behind internal carotid artery and vagus nerve. Internal jugular bulb is situated near the confluence with subclavian vein.

Internal jugular has the following extracranial influxes:

- *pharyngeal veins*;
- *lingual vein*;
- *superior thyroid vein*;
- *facial vein*, which receives retromandibular vein
- *retromandibular vein* empties into facial vein, or into internal jugular vein.

Follow vessels belong to intracranial tributaries of internal jugular vein:

- *venous sinuses* of dura mater encephali and veins of brain;
- *diploic veins* from skull bones;
- *meningeal veins* are from cranial dura mater;
- *superior ophthalmic vein* and *inferior ophthalmic vein* is from sight organ;
- *labyrinthic veins* – from internal ear;
- *emissary veins* from intracranial veins and sinuses of dura mater and communicate with extracranial veins.

**External jugular vein** is generated by the confluence of *occipital vein* and *posterior auricular vein*, which accompany same name arteries. External

jugular vein receives *anterior jugular vein*, which collect blood from anterior neck area and, anastomosing each other, form *jugular venous arc*.

**Subclavian vein** continues from *axillary vein*, lies in same name sulcus of first rib and collects blood from thoracic veins and *dorsal scapular vein*.

**Veins of upper limb** are subdivided into superficial and deep. They are communicated by numerous anastomoses and have valves.

**Superficial veins** are developed richer than deep one.

**Cephalic vein** starts from radial part of *dorsal venous hand net*. From dorsal hand surface it passes on anterior surface of radial margin across forearm, lies into lateral biceps brachii sulcus, then into sulcus between deltoid and major pectoral muscles and empties under clavicle into *axillary vein*.

**Basilica vein** collects blood from ulnar part of *dorsal venous hand net*, lies on ulnar side of anterior forearm surface, passes on medial biceps brachii sulcus and empties into one of *brachial veins*.

**Intermediate cubiti vein** passes obliquely in area of cubital fossa from cephalic to basilica veins.

**The Deep veins of upper limb** are double, they start from superficial palmar venous arch and deep palmar venous arch then accompanies same name arteries and.

**Axillar vein** is odd, it accompanies same name artery and continues into subclavian vein.

## SYSTEM OF INFERIOR VENA CAVA

**Inferior vena cava** starts on level IV-V lumbar vertebrae by the confluence of left common iliac vein and right common iliac vein, to the right and beneath from bifurcation of aorta. It passes through special foramen in centrum tendineum of diaphragm into mediastinum and empties into right atrium.

There are parietal and visceral influxes of inferior vena cava.

**Parietal tributaries** of inferior vena cava:

- *lumbar veins* are 3-4 pairs, which collect blood from areas according with ramification of lumbar arteries, they anastomose by *right* and *left ascending lumbar veins*;

- *inferior phrenic veins* collect blood from areas according with ramification same name arteries.

Follow veins are the **visceral tributaries** of inferior vena cava:

Follow veins are the **visceral tributaries** of inferior vena cava:

- in male – *right testicular vein* starts from posterior testicle margin.

Testicular vein forms *pampiniform plexus* which enters to composition of spermatic cord. *Left testicular vein* (also left ovarian vein in female) empties by right angle into *left renal vein*;

- in female – *right ovarian vein* begins from ovary hilus;

• *renal veins*, pair, pass from kidney hilus and, anastomosing with lumbar veins, empty into inferior vena cava between lumbar vertebrae first and second;

• *right suprarenal vein*, exits from hilus of adrenal gland. *Left suprarenal vein* falls into left renal vein;

• *hepatic veins* (3-4) veins fall into inferior vena cava in area of same name sulcus in liver.

**Vena portae hepatis** is situated in thickness of hepatoduodenal ligament between ductus choledochus and proper hepatic artery (formula of their position DVA – from right to left). It originates behind head of pancreas by the confluence of **superior, inferior mesenteric veins** and **splenic vein**. It collects venous blood from odd organs of abdominal cavity, except liver. Vena portae receives *cystic vein*, *right and left gastric veins* and *prepyloric vein* closely to liver hilus. *Paraumbilical veins* fall into portal vein in liver hilus.

There are cava-caval and porto-caval anastomoses between systems of portal vein, superior and inferior vena cavae.

### Anastomoses between the superior and inferior venae cavae systems

System	Veins	Veins	Position of anastomose
V. cava superior and v. cava inferior	v. epigastrica superior (tributary of the internal thoracic vein) and v. thoracoepigastrica (tributary of the subclavian vein)	v. epigastrica inferior (tributary of the external iliac vein) and v. Epigastrica superficialis (tributary of the femoral vein)	In anterior abdominal wall round the navel
V. cava superior and v. cava inferior	vv. azygos and hemiazygos	vv. lumbales	On posterior abdominal wall
V. cava superior and v. cava inferior	Rr. spinales (tributary of the vv. Intercostales posteriores)	Rr. spinales (tributary of the vv. Lumbales)	Form internal and external vertebral plexus

## Anastomoses between the superior and inferior venae cavae and portal vein systems

### VEINS OF PELVIS AND LOWER LIMB

The *common iliac veins* arose on level of sacroiliac joint by the confluence of internal iliac vein and external iliac vein.

**Internal iliac vein** has parietal and visceral influxes according to ramification of same name arteries.

*Visceral tributaries* of internal iliac vein form from such venous plexuses:

- sacral venous plexus;
- vesical venous plexus;
- rectal venous plexus.

**External iliac vein** is continuation of *femoral vein* and receives blood from all veins of lower limb. *Inferior epigastric vein* and *deep circumflexa ilei vein* empties into external iliac vein under inguinal ligament.

The veins of lower limb subdivide into superficial and deep. Deep veins are double and accompany same name artery (only a popliteal vein and femoral vein are odd).

Follow veins belong to *superficial veins* of lower limb:

**1. Vena saphena magna** has numerous valves, starts in front of medial malleolus, where receives influxes from plantar surface of foot,

passes along *saphenus nerve* on medial leg surface upward, than on medial surface on thigh to saphaenus hiatus, where transfixes cribriform fascia and empties into *femoral vein*. Vena saphena magna has the numerous subcutaneous tributaries from anteromedial surface of leg, thigh and external genitals.

**2. Vena saphena parva** has the numerous valves and collects blood from *dorsal venous arch of foot*, passes behind lateral malleolus, lies into sulcus between lateral and medial heads of gastrocnemius muscle and in popliteal fossa empties into *popliteal vein*.

Follow vessels belong to **deep veins** of lower limb:

- femoral vein;
- deep femoral vein;
- popliteal vein;
- anterior tibial veins;
- posterior tibial veins;
- fibular veins.

## CIRCULATION OF THE FOETUS

Circulatory system of the foetus has a row of peculiarities that differ from adult one:

- arterial blood reaches the foetus through *umbilical vein* from **placenta**;
- exclusive of umbilical vein, a blood in vessels is mixed;
- *venous (Aranti) duct* functions between umbilical and inferior vena cava by veins;
- blood from inferior vena cava gets from right atrium through the *ovale foramen* into left atrium;
- pulmonary circulation does not function;
- *arterial (Botalova) duct* functions between aortic arch and pulmonary trunk, through the which blood from pulmonary blood circle passes in systemic circulation;
- more oxygenated blood supplies head, neck, upper limbs and superior part of torso. Inferior part of trunk and lower limbs supplied by mixed blood, which is insufficiently saturated by oxygen, that's why these body portions of foetus fall behind in development in compare of head and upper part of torso.

After birth breath starts and pulmonary circulation begins to function. Umbilical vessels overgrow in 6-7 days, Botali duct – in 9-10 days and oval foramen in interatrial wall – in 30 days after birth.

## LYMPHATIC SYSTEM

Lymphatic system subdivides into primary lymphatic organs (*marrow* medulla ossium and thymus), secondary lymphatic organs (spleen, lymphatic pharyngeal ring, lymphatic nodes). Beside lymphatic organs, a lymphatic system has close vessel system and is part of vascular system. Lymph is a liquid, like a blood plasma it brings out the metabolic products from tissues.

**Function** of lymphatic system:

- taking of lymph from tissues to venous channel (drainage);
- lymphopoetic (marrow, thymic gland, lymphatic nodes);
- immune
- barrier (neutralizing foreign elements which got to organism).

Malignant cells spread (metastasis) by lymphatic channels.

Lymphatic system the following attributes, which make it *like* a venous system:

- vessels have the valves;
- lymph flows from tissues to heart.

Characteristics which *differ* lymphatic system from venous one:

- lymphatic nodes are situated on course of lymphatic channels;
- lymphatic system is tubular vessel system, which is close on one hand, and second – open into venous flow.

Lymphatic vessels *are absent* in central nervous system, spleen parenchyma, skin epithelium, cartilage, cornea, lens, placenta, hypophysis, and internal ear.

Vessel portion of lymphatic system consists of: 1) capillary networks which collect the lymph in the various organs and tissues; 2) vessels, 3) trunks, 4) ducts on which ways 5) nodes are located.

The **Capillaries** have the lateral recesses and form close net. In volumetric organs (kidneys, liver) they have three dimensions structure. In flat walls of hollow organs they are disposed in plane. Their wall consists of one layer of endothelial cells.

The **Vessels** subdivide into intraorganic and extraorganic, which subdivide into deep and superficial. Vessels have the valves, their wall consists of following layers: 1) endotelial (internal membrane); 2) muscular; 3) external membrane.

The **Lymphatic nodes** dispose on course of lymphatic vessels. They are organs of lymphopoesis and formation of antibodies, in pursuance the role of lymphoreticular filter.

Follow nodes are distinguished:

1. *regional* are the that carry a lymph from some body area or organ;
2. nodes have a name of accompany vessels;
3. *superficial* nodes;
4. *deep* nodes are situated under fascia;
5. *visceral* nodes are situated in body cavities;
6. *parietal* nodes are situated in walls of body cavities.

Each ganglion is covered outer by fibrous envelope – *capsule*, from which a frame-work of processes (*trabeculae*) proceeds inward. On node surface carries the concave place – *hilus*, where arteries and nerves enter into node, and the veins and efferent lymphatic vessels leave the interior. Node is built from *stroma* and *parenchyma*. Stroma of node consists of reticular tissue, where blood cells (mainly lymphocytes) disposed in loops. Cortex and medulla represent node parenchyma. *Medullar sinuses* are situated in lymphoid tissue, they are disposed between trabeculae and by bands of medulla, where lymph flows. The *afferent vessels* carry lymph into node and sinuses, *efferent vessels* commences from interior and transport lymph to the next lymphatic nodes, trunks and ducts.

#### **Lymphatic Trunks:**

1) *subclavian trunk* (right and left); 2) *jugular trunk* (right and left); 3) *broncho-mediastinal trunk* (right and left). They collect lymph from suitable half of head, neck, upper limbs, left or right half of thoracic cavity. These trunks fall into right venous angle or into left venous angle are these venous angles which are formed by subclavian vein and internal jugular vein. 4) *lumbar trunk* (right and left) collects lymph from lower limbs.

#### **Lymphatic Ducts:**

**Thoracic duct** forms in abdominal cavity on level of XII thoracic – II lumbar vertebrae by the confluence of *right and left lumbar lymphatic trunks*. There is triangular dilatation, the *cisterna chyli* or cistern of thoracic duct in this spot. Duct has abdominal part, thoracic part, cervical part and arch of thoracic duct. Last rounds a pleura cupola and ends by opening into the angle of junction of the left subclavian vein with the left internal jugular vein. In thoracic cavity a thoracic duct is situated in posterior mediastinum. It collects lymph from both lower limbs, abdominal, pelvic and left half of thoracic cavities.

**Right lymphatic duct** is short, by length 10-12 mm, which is formed by confluence of *right subclavian trunk*, *jugular trunk* and *broncho-mediastinal trunk* and runs into *right venous angle*. This duct transports

lymph from right half of head, neck, right upper limb, right half of thoracic cavity. Frequently this duct can be absent, then the trunks independently fall into right venous angle or into terminal portion of thoracic duct.

## LYMPHATIC VESSELS AND REGIONAL LYMPHATIC NODES

### The Lymphatics of the Lower Extremity

The superficial and deep vessels are distinguished in lower limb. The superficial vessels are situated over superficial fascia and deep vessels positioned closely to deep blood vessels. *Popliteal* nodes and *inguinal* nodes are distinguished in lower limb. Last one subdivide into deep inguinal nodes and superficial inguinal nodes. Superficial inguinal nodes dispose along inguinal ligament and lie on superficial sheet of fascia lata femoris. Their efferent vessels pass to external iliac nodes, which accompany same name artery.

The superficial vessels of lower limb formed from capillary skin networks and subcutaneous cellular tissue and form *medial*, *lateral* and *posterior* vessel groups.

*Medial group* of superficial vessels formed in skin of I, II and III fingers, medial part of foot and medial surface of shin. These vessels run along vena saphena magna and empty into superficial inguinal nodes.

*Lateral group* of superficial vessels of lower limb formed laterally in area of fingers in dorsal foot surface and lateral surface of shin. These vessels beneath knee join to medial group.

*Posterior group* of superficial vessels of lower limb starts in skin of heel and plantar surface of lateral foot margin, passes along the vena saphaena parva and runs into popliteal lymphatic nodes.

Deep vessels of lower limb drainage muscles, joints, synovial sheaths, bones, nerves, accompany deep arteries and veins and empty into deep inguinal nodes.

### The Lymphatics of the Pelvis

In pelvic area differ the visceral and parietal lymphatic nodes.

The **visceral** lymphatic nodes dispose near pelvic organs and they are: *paravesical*, *prevesical* and *retrovesical nodes*, *lateral vesical nodes*, *paraauterine nodes*, *paravaginal nodes* and *pararectal* or *anorectal nodes*. The efferent vessels from these nodes pass into **iliac nodes**, mainly to



**common iliac nodes** and to *retroaortic nodes*. Lymph flows from ovaries into **lumbar nodes**.

The **parietal** lymphatic nodes disposed along the course of big vessels *common iliac nodes; internal iliac nodes*, which unite *gluteal* and *sacral nodes*. *External iliac nodes* join *obturator nodes*. The efferent vessels from these nodes pass first into **common iliac nodes**, then into retroaortic nodes, and from them – into **lumbar lymphatic nodes**.

### The Lymphatics of the Abdomen

In abdominal cavity, as and in pelvis, lymphatic nodes may be divided into two sets, parietal and visceral.

The **Visceral lymphatic nodes** dispose along the course of big vessels come away from abdominal aorta, they receive lymph from all internal abdominal organs: *coeliac nodes, right/left gastric nodes, lymphatic unculus of cardia, right/left gastroepiploic nodes, pyloric nodes, pancreatic nodes, splenic nodes, pancreatoduodenal nodes, hepatic nodes, superior mesenteric nodes* and *inferior mesenteric nodes*. The lymphatic vessels of the small intestine receive the special designation of *lacteals* or *chyliferous* vessels; they differ in no respect from the lymphatic vessels generally excepting that during the process of digestion they contain a milk-white fluid, the chyle. The lymphatic vessels and nodes of the small intestine positioned in mesentery and empty into *intestinal trunk*. The vessels take away lymph from these nodes, pass to **lumbar nodes**. Efferent vessels of last form the lumbar trunks, which flowing together form a **thoracic duct**.

The **parietal** lymphatic nodes disposed around aortae and inferior vene cava – *right/left* and *intermediate lumbar nodes, lateral aortic nodes, preaortic nodes, retroaortic nodes, lateral caval nodes, precaval nodes, retrocaval nodes, inferior phrenic nodes* and *inferior epigastric nodes*.

Lymphatic vessels of superior half of abdominal wall pass upward to the **axillar** lymphatic nodes. The vessels of inferior half of abdominal wall pass downward to **inguinal** lymphatic nodes.

### The Lymphatic Vessels of the Thorax

Lymphatic nodes of the thorax may be divided into two sets, parietal and visceral. There distinguish the following **parietal** nodes of thorax:

**1. Parasternal** nodes collect lymph from pericardium, pleura, anterior thoracic wall, diaphragmatic surface of liver, mammary gland.

The vessels from these nodes carry lymph into right and left *venous angles*.

**2. Intercostal** nodes empty lymph into *thoracic duct*, and from superior nodes – into *deep lateral jugular* lymphatic nodes.

**3. Superior phrenic** nodes carry lymph into parasternal nodes, nodes *inferior tracheobronchic* and into *bronchopulmonary* nodes.

**4. Prepericardial** nodes transport lymph into parasternal nodes, nodes *inferior tracheobronchic* and into *bronchopulmonary* nodes.

**5. Prevertebral** nodes are disposed between backbone and esophagus.

**6. Paramammary** nodes are disposed laterally from breasts and drain them.

The *visceral* lymph nodes include the following groups:

- 1. paraesophageal** nodes
- 2. paratracheal** nodes
- 3. tracheobronchic** nodes
- 4. bronchopulmonary** nodes

All foregoing visceral nodes of thorax according old anatomic nomenclature, belong to *anterior* and, especially, *posterior mediastinal lymphatic nodes* (nodi lymphatici mediastinales anteriores et posteriores). Left half of thoracic cavity is drained to *thoracic duct*, right half – into right *lymphatic duct*.

## The Lymphatics of the Head, Face, and Neck

Lymph from head and neck gathers into *right* and *left jugular lymphatic trunks*, which pass on each side near internal jugular vein and fall: right – into right lymphatic duct or into right venous angle and left – into thoracic duct or immediately into left venous angle. Before duct lymph passes through regional lymphatic nodes.

Lymph from head runs into nodes positioned on boundary between head and neck. They include the following: 1) *occipital* nodes, 2) *mastoid* nodes, 3) *superficial parotid* nodes, 4) *deep parotid* nodes, 5) *submandibular* nodes, 6) *facial* nodes, 7) *submental*. Efferent vessels from these nodes extend in *deep cervical nodes*.

There are two groups of lymphatic nodes on neck – *anterior* cervical nodes and *lateral* cervical nodes, which subdivide into *superficial* and *deep*. Anterior deep lymphatic nodes: *prelaryngeal* nodes, *thyroid* nodes,

*pretracheal* nodes, *paratracheal* nodes. The superficial lateral nodes lie along external jugular vein, and deep – along internal jugular vein.

## THE LYMPHATICS OF THE UPPER EXTREMITY

Lymphatic nodes of upper limb may be divided into two sets, *superficial* and *deep*.

The ***superficial*** vessels and nodes of upper limb pass along the course of vena basilica and vena cephalica and compose lateral, medial and middle groups. *Lateral group* of superficial vessels carries lymph from skin of I-III fingers, lateral forearm surface and arm to axillar lymphatic nodes. *Medial group* of superficial vessels carries lymph from IV-V fingers, hand, medial forearm side and brachium to cubital and axillar lymphatic nodes. *Middle group* carries lymph from palmar forearm surface to cubital fossa and here part of vessels joins to lateral grand, and part to medial group. The superficial lymphatic nodes accompany the superficial hand veins. They collect lymph from skin and subcutaneous tissue. From them lymph passes to ***cubital nodes*** and ***axillar nodes***.

***Deep*** vessels and nodes of upper limb accompany the deep big vessels and carry lymph into deep nodes and superficial nodes, and from here – into *cubital nodes* and *axillar lymphatic nodes*. Axillar nodes receive the vessels from upper limb, thoracic wall, and mammary gland. The efferent vessels from axillar nodes form a ***subclavian trunk*** (left and right).

***Lymphatic annulus of pharynx*** belongs to secondary lymphatic organs and consists of *lingual tonsil*, *palatine tonsil*, *pharyngeal tonsil* and *tubarius tonsil*. They have tonsillar cryptae and tonsillar fossulae and lymphatic nodules. These tonsils are described in part “pharynx”. Tonsils are agglomerations of lymphoid tissue, which is disposed in area of entrance to pharynx and nasopharynx. They are placed around initial portions of high respiratory and digestive paths (*lymphoepithelial ring of Pyrohov-Valdeyer*).

The ***Lymphatic follicles of gastrointestinal tract*** are agglomeration lymphoid tissue in mucous membrane of the stomach (the gastric lymphatic follicles), small intestine (*solitary lymphatic follicles* and *aggregate lymphatic follicles* – *Payer patches*), large intestine (*solitary lymphatic follicles* and *aggregate lymphatic follicles of vermiform processes*). The largest amount of Payer patches is situated in distal portion of iliac bowel. T-lymphocytes migrate freely from lymphatic follicles through epithelium of mucous membrane into intestinal shaft of light.

The **SPLEEN** belongs to secondary lymphatic organs and is a big lymphatic node. Spleen is disposed in left hypochondriac on the level of 9-11 ribs. Spleen has *inferior margin* and *superior margin*, *anterior extremity* and *posterior extremity*. It has a *diaphragmatic surface* (superior) and *visceral surface* (inferior). To the last adjoin stomach (*facies gastrica*), left kidney with suprarenal gland (*facies renalis*), left colic flexure (*facies colica*) and tail of pancreas (*facies pancreatica*). Place on visceral surface, where vessels and nerves enter and leave, is called as **splenic hilus**. Spleen is covered by peritoneum from all sides (lies intraperitoneally).

Spleen is covered by *fibrous capsule*, from which numerous small fibrous bands, *trabeculae* are given off in all directions into parenchyma, these uniting, and constitute the framework of the spleen. Parenchyma consists of splenic pulp, which has a *white pulp* and *red pulp* and its structure described in detail in histology course.

## ORGANS OF IMMUNE SYSTEM AND HAEMOPOESIS

**Immune system** unites organs and tissues, which provide defense from genetically foreign cells or matters, that got from out or are generated inside the organism, providing constancy of internal organism environment. Organs of immune system may be divided into central and peripheral part.

To *central organs* of immune system belong **thymus** gland and **red marrow**.

To *peripheral organs of immune system* unite organs are not enveloped in capsule (*tonsils*, *lymphoid follicles*, that are situated in walls of hollow organs of digestive and respiratory systems and *lymphocytes*, which are situated in blood, lymph, connective and epithelial tissue) and capsulated organs (*lymphatic nodes* and *spleen*).

**Thymus** is placed in front part of superior mediastinum and consists of lobes, more frequent two. Outside this gland is tunicate by *fibrous capsule* that gives off *septa*, which split up *lobes* on *lobules*. They comprise reticular cells with lymphocytes between them (called as ‘thymocytes’). The lobules of gland have a *cortex* and *medulla thymi*. Can be accessories lobules of thymus. Basic function of thymus maturation and supporting of effector cells (killer) and regulatory cells (helper and suppressor) T-lymphocytes populations. Also thymus takes part into regulation of neuromuscular transmission, phosphoric-calcium metabolism, carbohydrate and peptide metabolism, interaction with other endocrine glands (that’s why one can be consider thymus gland as a endocrine organ).

**Red marrow** is sole haemopoetic organ in adult and central organ of immune system. Stem cells are generated in it, they are like lymphocytes because their morphology and during cell-fission give beginning to all formal blood elements, also including cells providing immunity – to leukocytes and lymphocytes. Red marrow in adult is situated in cells of spongy matter of flat and short bones, in epiphysis of long tubular bones. *Yellow marrow* is situated in diaphysis of long tubular bones. Largest amount of red marrow is situated into epiphysis of femoral and tibiae bones.

## NERVOUS SYSTEM

Nervous system may be divided into two parts, **central** and **peripheral**, also somatic and autonomic. The **central nervous system** consists of the **brain** [encephalon], contained within the cranium, and the **medulla spinalis** or **spinal cord**, lodged in the vertebral canal. The **peripheral nervous system** consists of a series of cranial and spinal nerves. Autonomic nervous system has a parasympathetic and sympathetic parts.

### SPINAL CORD

Spinal cord is located in vertebral canal and extends inferiorly from the position of the foramen magnum of the occipital bone to the level of the first-second lumbar vertebra. The terminal portion of the spinal cord is called the **conus medullaris** and **filum terminale** extends inferiorly from it to the level second coccyx vertebrae. The **cervical enlargement** is located at the level of 6<sup>th</sup> cervical vertebrae, and the **lumbosacral enlargement** at the level of 12<sup>th</sup> thoracic vertebrae. The **Central Canal** (*canalis centralis*) runs throughout the entire length of the medulla spinalis. It is continued upward and opens into the fourth ventricle of the brain. In the lower part of the conus medullaris it exhibits a fusiform dilatation, the **terminal ventricle**.

The **anterior median fissure** (*fissura mediana anterior*) and right and left anterolateral sulcuses located on anterior surface of the spinal cord. **Posterior median sulcus** (*sulcus medianus posterior*) and also right and left **posterolateral sulcus** located on back surface of the spinal cord.

Each spinal nerve is attached to the medulla spinalis by two roots, an **anterior** or **ventral** (motor and sympathetic fibers), and a **posterior** or

**dorsal**, the being characterized by the presence of a ganglion, the **spinal ganglion** (with sensory pseudounipolar cells). After emerging from the intervertebral foramen, each spinal nerve gives off a small **meningeal branch** which supplies the dura mater, and an anterior or **ventral, posterior** or **dorsal divisions**, also white and gray communicating branches for nearest sympathetic ganglion (in thoracic-lumbar part).

Spinal cord consists of the **gray substance** that is surrounded by the **white substance**. Posterior median sulcus passes to the gray substance and divides by the white substance into two parts. Anterior median fissure does not pass to the gray substance so it is white commissura that connect anterior symmetrical regions of the white matter.

The gray substance is largely composed of nervous cell bodies. The gray substance consists of anterior, posterior and lateral columns (only in thoracic-lumbar portion) also central intermediate zone round central canal. In transverse section columns are looking as horns, so they differ anterior, posterior and lateral horns.

Anterior horns contain motor cells that arranged in 5 motor nuclei (nucleus anterior [medial and lateral], central nucleus and posterior [medial and lateral] nuclei). Their axons form *anterior roots* that pass with spinal nerves to the skeletal muscles of the trunk and limbs. Posterior horns contain intermediate cells. They receive impulse from sensory cells and carry them to the another cell. Intermediate cells form the spongy zone, gelatinous substance, proper nucleus and thoracic nucleus (Clarke-Steiling column).

Lateral columns in thoracic-lumbar portion contain autonomic cells that form **lateral intermediate nucleus**. In intermediate central part **medial intermediate nucleus** carry intermediate cells.

White substance contains only neuron long processes (axons), the nerve fibers which form ascending (sensory, afferent) and descending (motor, efferent) pathways. White substance divided by sulci and is arranged in three funiculi: anterior, lateral, and posterior. Both anterior funiculi are communicated each other by white commissura.

Funiculi in the **Posterior Funiculus** comprises the **fasciculus gracilis** [*tract of Goll*] (lies next the posterior median septum) and the **fasciculus cuneatus** [*tract of Burdach*] (laterally). They conduct impulses of conscious muscle sense.

Pathways in the **Anterior Funiculus** (descending): anterior corticospinal [pyramidal] tract, tectospinal tract, reticulospinal tract, olivospinal tract, and vestibulospinal tract. Ascending pathway – anterior spinothalamic tract.

Ascending pathways in the **Lateral Funiculus**:

- dorsal spinocerebellar tract (*tract of Flechsig*)
- ventral spinocerebellar tract (*tract of Gowers*)
- lateral spinothalamic tract

Medially they can find descending pathways:

- corticospinal [pyramidal] tract
- rubrospinal tract (*of Monakow*)

Portion of the spinal cord that carries two pairs of ventral and dorsal roots or one pair of spinal nerves called **segment**. There are 8 cervical, 12 thoracic, 5 lumbar, 5 sacral and 1 coccygeal segments. Roots which exit from the spinal cord lower than second lumbar segment form together with the filum termanale **cauda equina**.

The medulla spinalis is ensheathed by three protective membranes, separated from each other by two concentric spaces:

1. The **Dura mater**
2. The **Arachnoid**
3. The **Pia mater**

The dura mater is separated from the wall of the vertebral canal by the **epidural cavity**, which contains a quantity of fat tissue and a plexus of veins. Between the dura mater and the subjacent arachnoid is a capillary interval, the **subdural cavity**, which contains a small quantity of fluid, probably of the nature of lymph. The **arachnoid** is a thin, transparent sheath, separated from the pia mater by a comparatively wide interval, the **subarachnoid cavity**, which is filled with cerebrospinal fluid. The **pia mater** closely invests the medulla spinalis and sends delicate septa into its substance; a narrow band, the **ligamentum denticulatum**, extends along each of its lateral surfaces and is attached by a series of pointed processes to the inner surface of the dura mater.

## SPINAL NERVES

Joining of the ventral and dorsal spinal roots forms 31 pairs of the **spinal nerves**. After emerging from the intervertebral foramen, each spinal nerve gives off a small **meningeal branch** (sensory) which supplies the dura mater, and an anterior or **ventral, posterior or dorsal divisions** (both mixed), also **white and gray communicating branches** for nearest sympathetic ganglion (in thoraco-lumbar C<sub>VIII</sub>-L<sub>II</sub> segments).

## POSTERIOR RAMI

<b>Structure</b>	<b>Location/Description</b>	<b>Notes</b>
<b>arachnoid mater</b>	intermediate one of the three layers of meninges	arachnoid mater is a thin membrane which is pressed against the inner surface of the dura mater by cerebrospinal fluid pressure; arachnids are spiders, the space deep to this layer (subarachnoid space) has a spider web-like appearance
denticulate ligament	a lateral extension of pia mater from the spinal cord	denticulate ligament attaches to the dura mater to anchor the spinal cord; it forms a scalloped free border; there are 2 (one on each side)
<b>dura mater</b>	outermost of the meningeal layers covering the brain and spinal cord	"tough mother"; it is the most durable of the meninges and provides support and protection for the brain and spinal cord; two types are described which differ in structure: cranial and spinal
dura mater, spinal	outermost covering of the spinal cord, it forms the dural sac containing the spinal cord within vertebral canal	dural sac ends at S2, coccygeal ligament (filum terminale externum) continues inferiorly to attach to coccyx
<i>epidural fat</i>	loose connective tissue within the epidural space	
<i>epidural space</i>	the space external to the sac of spinal dura mater within the vertebral canal	the epidural space contains epidural fat and the internal vertebral plexus of veins which is valveless (clinically relevant)
filum terminale internum	thread-like extension of the pia mater from the conus medullaris of the spinal cord	filum terminale internum is best seen between vertebral levels L2 and S2; it becomes enclosed within the filum terminale externum
filum terminale externum	thread-like extension of the dura mater below the end of the dural sac at S2	it attaches to the coccyx; also known as the coccygeal ligament



Structure	Location/Description	Notes
meninges	three layers of connective tissue covering the brain and spinal cord; dura mater, arachnoid mater, and pia mater	meninges provide protection and nourishment of the brain, brainstem and spinal cord
<b>pia mater</b>	delicate membrane that lies on surface of the brain and spinal cord	"delicate mother", it is the most delicate of the meninges; this layer faithfully follows all surface contours of the brain and spinal cord; pia mater has 2 specializations: denticulate ligament and filum terminale internum
<i>subdural space</i>	the space between the dura mater and the arachnoid mater	this is a potential space only; the pressure of CSF in the subarachnoid space pushes arachnoid against dura
<i>subarachnoid space</i>	the space between the arachnoid and the pia mater	subarachnoid space contains cerebrospinal fluid and spider web-like filaments
cauda equina	dorsal and ventral roots of all spinal nerves inferior to L1	lies within the lumbar cistern
conus medullaris	cone-shaped inferior end of the spinal cord; located at vertebral level L1	at birth, the conus medullaris is at the level of L2/L3
cervical enlargement	vertebral level C4 through T1	created by the rootlets of spinal nerves C5-T1 that form the brachial plexus
lumbrosacral enlargement	vertebral level T11 through L1	Created by the rootlets of spinal nerves L1-S4 that form the lumbosacral plexus

The posterior rami, the *rami dorsales*, supply motor branches to those muscles which belong to the autochthonous back muscles, and sensory branches to the skin. The first dorsal cervical branch is motor and runs as the **suboccipital nerve** to the suboccipital muscles. The **greater occipital nerve** runs from the II cervical ramus to the skin and splenius capitis and cervicis and longissimus muscles.

The dorsal lumbar branches (**superior cluneal nerves**) supply the skin in upper part of buttocks. The dorsal sacral branches (**medii cluneal nerves**) supply the skin in middle part of buttocks. Anterior rami of the

spinal nerves (with the exception of thoracic) form the plexus. There are cervical, brachial, lumbar and sacral plexuses.

## CERVICAL PLEXUS

The cervical plexus is formed from the ventral rami of the first four spinal nerves (C1-C4). It is located under sternocleidomastoid muscle. The *motor, cutaneous and mixed nerves* start from this plexus.

Short motor branches run directly to the deep cervical muscles: the anterior and lateral rectus capitis muscles, and the longus capitus and longus colli muscles of the head and neck, anterior, middle and posterior scalenus muscles, also sternocleidomastoid and trapezius muscles. Fibers associated with the hypoglossal nerve and form the ansa cervicalis that innervates the infrahyoid muscles: the omohyoid, sternothyroid and sternohyoid, thyrohyoid.

The sensory nerves of the plexus penetrate the fascia behind the sternocleidomastoid muscle:

- **transverse cervical nerve** of the neck (supplies the anterior cervical region)
- **lesser occipital nerve** (for lateral occipital region)
- **greater auricular nerve** (the region of the ear)
- **supraclavicular nerves** (supply the supraclavicular region, the shoulder and the upper thoracic region)

The **Phrenic nerve** (mixed) enters the superior thoracic aperture and runs through the mediastinum to the diaphragm, giving off small branches for the sensory innervation of the pericardium. It divides on the surface of the diaphragm to supply all the *diaphragmatic muscle*. Branches provide the sensory fibers to the serous coverings of the diaphragm, the *pleura* cranially and caudally the *peritoneum* covering it and the liver and gallbladder.

## BRACHIAL PLEXUS

The brachial plexus formed by the ventral rami of spinal nerves C<sub>5</sub>-T<sub>1</sub>. It lies on the deep neck muscles and is divided into a *supraclavicular part* and an *infraclavicular part*.

*Supraclavicular Part passes through the interscalenus foramen and consists of the superior, middle and inferior trunks and gives off motor nerves to the muscles of the shoulder girdle:*

- the **dorsal scapular** nerve (which supplies the levator scapulae muscle and the rhomboideus major and minor muscles),
- the **suprascapular** nerve (suprascapular muscle and infraspinatus muscle)
- the **subscapular** nerve (passes to the subscapular and teres major muscle)
- the **subclavius** nerve (to the subclavius muscle)
- **lateral and medial pectoral** nerves (which supply the pectoralis major and pectoralis minor muscles)
- the **long thoracic** nerve (whose branches supply the serratus anterior muscle)
- the **thoracodorsal** nerve (which supplies the latissimus dorsi muscle)

• Axillary nerve branches off from posterior cord of the Infraclavicular Part. It passes deep in the axillary fossa through the quadrilaterum foramen to the back surface of the scapula. It supplies the capsule of the shoulder joint and gives off motor branches for deltoid and teres minor muscles. Branch *superior lateral brachial cutaneous nerve* passes to the skin, which it supplies the skin in the deltoid region.

*Infraclavicular Part.* According to relation to the axillary artery they distinguish the **lateral** cord, the **medial** cord and the **posterior** cord.

### Nerves start from the medial cord:

**1. Medial cutaneous brachial** nerve (supplies the skin of the ventromedial region of the brachium).

**2. Medial antebrachial cutaneous** nerve (supplies the skin of the ventromedial region of the forearm).

**3. Ulnar nerve** runs in the medial bicipital sulcus without (!) giving off any branches. It crosses the elbow joint on the backside in a medial epicondyle. Here the nerve may be felt and pressure on it produces an “electric” type of pain which radiates to the ulnar side of the hand. The nerve passes in the *ulnar sulcus* on the forearm through the flexor carpi ulnaris muscle and then runs below this muscle to the wrist joint. It does not traverse the carpal tunnel but passes over the flexor retinaculum to the palmar surface of the hand where it divides into *superficial* and *deep branches*. In the forearm it gives off branches to the flexor carpi ulnaris muscle and to the ulnar half of the flexor digitorum profundus muscle. In the middle of the forearm a sensory branch is given off, the dorsal branch

of the ulnar nerve, which passes to the ulnar side of the back of the hand where it supplies the skin. Another sensory branch, the *palmar branch* of the ulnar nerve, is given off in the distal third of the forearm. It passes to the palm of the hand and supplies the skin of the hypothenar eminence. The superficial branch, as the fourth common palmar digital nerve, passes to the interosseous space between the ring and little fingers and divides into the proper palmar digital nerves, which supply the sensory innervation of the volar surface of the little finger and the ulnar side of 4-th finger. The deep branch gives off branches to all the muscles of the hypothenar eminence (abductor muscle of the fifth finger, the flexor brevis muscle of the minimus finger, and the opponens muscle of the minimus finger) and all the dorsal and palmar interosseous muscles, the third and fourth lumbrical muscles, the adductor pollicis muscle, and the deep head of the flexor pollicis brevis muscle.

**4. Median nerve** is formed on the anterior surface of the axillary artery by parts of the *medial and lateral cords*. The nerve runs to the elbow in the medial bicipital sulcus and does not (!) supply anything in brachial region. Then it reaches the forearm between the two heads of the pronator teres muscle. It extends to the wrist between the flexor digitorum superficialis and the flexor digitorum profundus in *median sulcus*. Before it enters the *carpal canal* it lies superficially between the tendons of the flexor carpi radialis muscle and the palmaris longus. In the carpal canal it divides into its terminal branches. The *muscular branches* of the nerve supply the pronators and most of the flexors of the forearm: pronator teres, the flexor carpi radialis, the palmaris longus and the flexor digitorum superficialis muscle. The anterior *antebrachial interosseous nerve* runs on the interosseous membrane to the deep muscles. In the lower third of the forearm, the sensory palmar branch of the median nerve passes to the skin of the ball of the thumb, the radial side of the wrist and the palm of the hand. The median nerve gives off branches to the periosteum, the elbow joint, the radiocarpal joint and the mediocarpal joint. After passing through the carpal canal the median nerve divides into the *common palmar digital nerves* I, II, III, each of which divide at the level of the proximal metacarpophalangeal joints into the two *proper palmar digital* nerves. They give off a branch to the thenar muscles (abductor pollicis brevis muscle, superficial head of the flexor pollicis brevis muscle and the opponens pollicis muscle). The *common palmar digital nerves* supply the I-II lumbrical muscles. Sensory branches supply the skin of thenar, of the 1<sup>st</sup>, 2<sup>d</sup>, 3<sup>d</sup> and part of the 4<sup>th</sup> fingers.

## CARPAL TUNNEL SYNDROME

Carpal tunnel syndrome is a condition that causes a “needles-and-pins” sensation to the index and middle finger of the wrist, and is caused by compression or stretching of the medial nerve. It is a common disorder with people whose occupation require a great deal of wrist flexion or prolonged extension. It has been commonly called the “secretary’s disease” and is seen commonly in writers, typists, pianists, and even more recently, computer professions. The symptoms can vary, but usually include pain in the middle area of the wrist, swelling of wrist, numbness or tingling in index and middle fingers, and loss of function of hand in severe cases. Splints applied to dorsiflex the wrist occasionally help. Cortisone injections may help, and surgery to strip away build-up of adhesive tissue may be required. This condition can recur even after treatment and tends to worsen in the evening and night.

Beside the Median nerve **Musculocutaneous nerve** also start *from the lateral cord*. The nerve runs through the coraco-brachialis muscle between the biceps and brachialis muscles (and nerve supplies them) as far as the elbow. The sensory fibers of the nerve at the elbow pass through the fascia onto the surface and, as the **lateral antebrachial cutaneous nerve**, supply the skin in the lateral part of the forearm.

### **The posterior cord gives off the axillary and radial nerves**

**Radial nerve** runs from the axilla in the *radial canal* and supplies the long, lateral and medial heads of the triceps brachii and anconaeus muscles. Also *inferior lateral* and *posterior brachial cutaneous nerves* pass to the skin, which it supplies on the lateral and posterior surface of the arm. Radial nerve crosses the elbow joint and divides at the level of the head of the radius into its two terminal branches, the *superficial* and *deep branch*. The deep branch gives off numerous muscular branches and finally extends to the wrist joint as the *posterior antebrachial interosseous nerve*. Radial nerve supplies all superficial and deep posterior antebrachial muscles, brachioradialis muscles, also skin in posterior region. On the back of the hand the superficial branch gives off the 5 dorsal digital nerves which supply the only skin of radial part of the hand, the back surface of the 1<sup>st</sup>, 2<sup>nd</sup>, 3<sup>d</sup> fingers.

## INTERCOSTAL NERVES

12 pairs of the ventral rami of the thoracic spinal nerves run between the ribs as **intercostal nerves** (the 12<sup>th</sup> nerve called *subcostal nerve*). They pass in *sulcus costae* between the external and internal intercostal muscles and supply them, also the transverse thoracic muscle. Six upper intercostal nerves give off *anterior* and *lateral cutaneous branches* for skin in chest region, also *medial* (Th<sub>II-IV</sub>) and *lateral* (Th<sub>IV-VI</sub>) *mammary branches* for innervating the breast. Six lower intercostal nerves pass into the depth of the abdominal muscles, into the sheath of the rectus abdominis muscle and supply muscles (\*) and skin in anterior and lateral abdominal region (\* – rectus abdominis, external, internal oblique and transverse abdominis, pyramidalis muscles).

## LUMBAR PLEXUS

The lumbar plexus is formed from part of Th<sub>12</sub> and L<sub>1</sub>–L<sub>4</sub> ventral rami of the thoracic and lumbar spinal nerves. Lumbar plexus lies inside the psoas major muscle. The lumbar plexus gives off *motor branches* directly to the psoas major and psoas minor muscles, the quadratus lumborum muscle.

5. The **iliohypogastric nerve** runs on the inner surface of the quadratus lumborum muscle and then between the transversus abdominis muscle and the internal oblique muscle of the abdomen and innervates these muscles. It gives off the *lateral cutaneous branch* which supplies the lateral region of the hip and the cutaneous branch for skin above the inguinal ligament.

6. The **ilioinguinal nerve** runs along the inguinal ligament and takes part in the innervation of the broad abdominal muscles, the sensory innervation of the skin of the mons pubis, and the upper part of the scrotum or the labia majora in the female.

7. The **lateral femoral cutaneous nerve** passes over the iliacus muscle to just below the anterior superior iliac spine. It then extends through the lateral part of the *muscular lacuna*, to the skin of lateral surface of the thigh.

8. The **femoral nerve** passes on the lateral margin of the psoas major muscle as far as the inguinal ligament, and through the *muscular lacuna* to the anterior surface of the thigh. Beneath the inguinal ligament the nerve trunk divides into a number of branches: a primarily sensory ventral group, *anterior cutaneous branches* for the skin of thigh, a *motor branches*

to the anterior muscles of the thigh, and the *saphenous nerve*. The femoral nerve supplies the rectus femoris, the vastus medialis, lateralis and the vastus intermedius; the sartorius muscle. It gives off small sensory twigs to the capsule of the knee joint and vessels. The **saphenous nerve** runs into the *adductor canal*. It is a purely sensory nerve and gives off an *intrapatellar branch*, to supply the skin below the patella. Then *saphenous nerve* supplies the skin on the anterior and medial surfaces of the lower leg, the medial margin of the foot as far as the great toe.

9. The **obturator nerve** supplies motor fibers to the adductor muscles (\*) of the thigh. The nerve passes through the *obturator canal* where it extends to the thigh. It supplies a *muscular branch* to the obturator externus muscle and then divides into a superficial and a deep branches. *Cutaneous branch* to the skin of the medial surface of the thigh.

(\* – adductor longus, adductor brevis muscles, pectineus and the gracilis muscles, adductor magnus muscle).

10. The **genitofemoral nerve** divides early into two branches, either in or on the psoas muscle. The *genital branch* passes over the inguinal ligament and innervates the cremaster muscle or the ligamentum teres and supplies the sensory innervation of the skin of the scrotum or the labia majora. The *femoral branch* passes below the inguinal ligament and reaches the saphenous hiatus. It supplies the skin of the thigh lateral to the area of the genital branch.

## SACRAL PLEXUS

The sacral plexus is formed from L<sub>IV</sub>-L<sub>V</sub>, S<sub>I</sub>-S<sub>IV</sub> ventral rami of the lumbar and sacral spinal nerves. Sacral plexus lies on the piriform muscle and gives off short and long branches.

### SHORT BRANCHES:

- small **muscular branches** pass directly to muscles in the pelvic region: internal obturator, superior and inferior gemelli piriform quadratus femoris muscles

- **superior gluteal nerve** passes through the *suprapiriform* foramen to supply the motor innervation of the medius and minimus gluteus muscle and tensor fasciae latae

- **inferior gluteal nerve** leaves the pelvis through the *infrapiriform foramen* and supplies several branches to the gluteus maximus muscle

- **pudendal nerve** leaves the pelvis through the *infrapiriform foramen* and passes dorsally around the ischial spine to enter the *ischiorectal fossa* through the lesser sciatic foramen. It gives off here *inferior rectal* nerves

to external anal sphincter, *perineal* nerves to ischiocavernosus, bulbospongiosus, transversus perinei superficial and profundus muscles and skin. *Posterior scrotal (labial)* nerves and *dorsal penis (clitoridis)* nerve supplies external genitals and sphincter urethrae.

### **LONG BRANCHES:**

1. **Posterior femoral cutaneous nerve** leaves the pelvis through the *infrapiriform foramen* and passes below the gluteus maximus muscle to the skin in posterior surface of the thigh. It is a purely sensory nerve and gives off branches to the lower margin of the buttocks, the *inferior cluneal nerves*, the perineal branches.

2. **Sciatic nerve** (the largest in human body) nerve leaves the pelvis through the *infrapiriform foramen* and passes toward the knee beneath the gluteus maximus muscle and the biceps muscle. It supplies the long head of the biceps femoris muscle, semitendinosus and semimembranosus. Then it divides into the *tibial nerve and common peroneal nerve* above the knee joint.

**Tibial nerve** runs vertically through the middle of the popliteal fossa deep to the gastrocnemius muscle in *cruropopliteal canal*. The **medial sural cutaneous nerve** separates in the popliteal fossa and runs downward between the two heads of the gastrocnemius muscle (supplies the skin of medial leg region) to combine with the peroneal communicating branch to form the *sural nerve*. This passes lateral to the Achilles tendon and behind and around the lateral malleolus to reach the lateral margin of the foot. It gives off *lateral calcaneal branches* to the skin of the lateral side of the heel, and the *lateral dorsal cutaneous nerve* to the lateral margin of the foot. *Motor branches* of the tibial nerve arise in the popliteal fossa for: the gastrocnemius muscle, soleus muscle and plantaris and popliteal muscles the tibialis posterior muscle, flexor digitorum longus muscles and the flexor hallucis longus also the interosseous membrane, the periosteum of the tibia, the ankle joint and tibiofibular joint. Below the medial malleolus tibial nerve divides into two terminal branches, the *medial and lateral plantar nerves*.

a) The **medial plantar nerve** runs in the *medial plantar sulcus* and innervates the abductor hallucis muscle, the flexor digitorum brevis muscle and the flexor hallucis brevis muscles. It divides into the three common plantar digital nerves which supply lumbrical muscles 1 and 2 and divide further into the deep digital plantar nerves that supply the skin of the spaces between the toes from the great to the fourth toe.



b) The second terminal branch, the **lateral plantar nerve** runs in the *lateral plantar sulcus*, supplies the skin of the region of the small toe and to the interosseous muscles, the adductor hallucis muscle and the lateral 3 and 4 lumbrical muscles, flexor digiti minimi brevis muscle.

• **Common peroneal nerve** passes along the biceps muscle at the lateral margin of the popliteal fossa to the head of the fibula. It winds around the neck of the fibula toward the anterior surface of the lower leg and enters the peroneus longus muscle. Within the muscle it divides (*common peroneal nerve*) into the *superficial and deep peroneal nerves*. The *lateral sural cutaneous nerve* supplies the skin of the lateral surface of the lower leg, and the communicating *medial sural cutaneous nerve* that together with the forms the *sural nerve*.

c) The **superficial peroneal nerve** passes between the peroneus longus muscle and the fibula to the dorsum of the foot. It gives off *muscular branches* to the peroneus longus and brevis muscles. The remainder of the nerve is purely sensory; it divides into two terminal branches, the *medial dorsal cutaneous nerve* and the *intermediate dorsal cutaneous nerve* which supply the skin of the dorsum of the foot, with the exception of the space between the great and second toes.

d) The **deep peroneal nerve**, which is predominantly motor, turns anteriorly to the anterior muscles of the leg and passes to the dorsum of the foot. The *deep peroneal nerve* gives off several *motor branches* to the extensor muscles of the lower leg and the foot, to the tibialis anterior muscle, the extensors of the digits (longus and brevis) and the extensors of the great toe (longus and brevis). The terminal branch is sensory and supplies the adjacent surfaces of the interspace between the great and second toes.

## COCCYGEAL PLEXUS

The coccygeal plexus is formed from ventral rami of the sacral and coccygeal spinal nerves ( $S_v$ ,  $Co_1$ ). It is located on coccygeal muscle. *Anococcygeal nerves* start there and innervate the skin in adjacent area.

## BRAIN

The brain [encephalon, cerebrum] during the fourth week develops from three primary cerebral vesicles: *prosencephalon*, *mesencephalon* and *rhombencephalon*. Prosencephalon forms two secondary cerebral vesicles: telencephalon and diencephalon. Rhombencephalon gives origin for medulla oblongata and metencephalon. Mesencephalon separates from rhombencephalon by isthmus.

Metencephalon develops into *pons* and *cerebellum*. Midbrain comprises *tectum* and *pedunculi cerebri*. Diencephalon contains *thalamus* and *hypothalamus*. Telencephalon (forebrain) gives origin for rhinencephalon, basal nuclei of gray matter, pallium of hemispheres, corpus callosum and fornix.

The brain can be divided into two cerebral hemispheres, brain stem and cerebellum. A hemisphere has a base, dorsolateral and medial surfaces. 12 pairs of the cranial nerves exit from the encephalon base (see table below).

On the brain base students should find:

- *medulla oblongata*
- *pons*
- *medii cerebellar pedunculi*
- *cerebral pedunculi*, *interpeduncular fossa* lies between the two peduncles. Its floor is perforated by large numbers of blood vessels, the *posterior perforated substance*

- 2 *mammillary bodies* are located forward from interpeduncular fossa
- *tuber cinereum* with *infundibulum* that carries the *hypophysis*
- *optic tracts* which join each other and form optic chiasm
- *optic nerve*
- *olfactory triangles* with *anterior perforated substance*
- *olfactory tracts*
- *olfactory bulbs*

On the medial surface of the brain students should find:

- *Cerebral hemispheres* communicate each other by *corpus callosum*. Corpus callosum anteriorly carries a *genu* that passes into *rostrum*. Last continue as a *lamina rostralis* and *lamina terminalis*. Back part of the corpus callosum called *splenium*

- Above the corpus callosum there is *fornix cerebri* posteriorly passes into *crura fornicis*, anteriorly continue as a *columna fornicis*
- *Lamina septi pellucidi* is tightened between corpus callosum and *columna fornicis*

*Thalamus* positioned under fornix

## Cranial Nerves:

№	Name	Position	Foramen	Function
<b>I</b>	<b>Olfactory</b>	olfactory bulb	openings of the cribriform plate of ethmoid bone	smell
<b>II</b>	<b>Optic</b>	optic chiasm	optic canal	vision
<b>III</b>	<b>Oculomotor</b>	interpeduncular fossa	superior orbital fissure	eye muscles
<b>IV</b>	<b>Trochlear</b>	superior medullary velum	superior orbital fissure	eye muscles
<b>V</b>	<b>Trigeminal</b>	between the pons and medii cerebellar pedunculi	(1) <b>Ophthalmic:</b> superior orbital fissure; (2) <b>Maxillary:</b> foramen rotundum; (3) <b>Mandibular:</b> foramen ovale	face sensation & mastication
<b>VI</b>	<b>Abducent</b>	between the pons and pyramids	superior orbital fissure	eye muscles
<b>VII</b>	<b>Facial</b>	cerebellopontine angle	internal acoustic meatus, stylomastoid foramen	face muscles; salivary & lacrimal glands
<b>VIII</b>	<b>Vestibulo-cochlear</b>	cerebellopontine angle	internal acoustic meatus	hearing & balance
<b>IX</b>	<b>Glossopharyngeal</b>	dorsal lateral sulcus of medulla oblongata	jugular foramen	pharynx; tongue & parotid gland
<b>X</b>	<b>Vagus</b>	dorsal lateral sulcus of medulla oblongata lower X pair	jugular foramen	pharynx, larynx & viscera
<b>XI</b>	<b>Accessory</b>	dorsal lateral sulcus of medulla oblongata lower XI pair	jugular foramen	neck muscles (Trapezius/ster nucleido-mastoid)
<b>XII</b>	<b>Hypoglossal</b>	between olive and pyramid	hypoglossal canal	tongue & neck muscles

- Backward from the thalamus *there is quadrigeminal plate* with two upper and two lower hillocks, the *superior* and *inferior colliculi*
  - *Cerebral aqueduct [Silvii]* passes under mesencephalic tectum. It communicates front with the *3<sup>d</sup> ventricle*, back with the *4<sup>th</sup> ventricle*
  - The *4<sup>th</sup> ventricle* is bordered upper and lower by the superior medullary velum and inferior medullary velum
  - The floor of the IV<sup>th</sup> ventricle, the *rhomboid fossa*, occupies the dorsal surface of the medulla oblongata and the pons
  - *Cerebellum* consists of two hemispheres which connected by *vermis*
- Cerebral hemispheres are separated by **median longitudinal fissura** that passes to the corpus callosum. Cerebrum is separated from the cerebellum by **transverse fissura**.

## MEDULLA OBLONGATA

The medulla oblongata also called as *cerebral bulb*, located between the *pyramidal decussation* and the lower margin of the *pons*, forms the transition from the spinal cord to the brain. The **anterior median fissure** separates the **pyramids**. The *anterior* and *posterior lateral sulcus* boundary the **olives**. On the posterior surface funiculi thicken to form the *tuberculum nuclei cuneati* and the *gracilis*, which are bordered in the midline by the **posterior median sulcus**. Posterior surface of the medulla oblongata form a lower part of rhomboid fossa.

**Gray substance** of the medulla oblongata is presented by:

- Olivar nuclei
- gracilis and cuneatus nuclei
- cardiac, vasomotor and respiratory centers
- nuclei of the IX-XII cranial nerves

**White substance** of the medulla oblongata consists of ascending tracts that form *medial lemniscus* and descending tracts and *reticular formation*.

## Reticular Formation

The neurons of the brainstem and their **network** of communicating processes are known as the **reticular formation**. It lies in the midpart of the tegmentum and extends from the spinal cord to the midbrain. In the medial region there are large-celled nuclei from which arise long ascending and descending tracts. Groups of nerve cells regulate respiration, heartbeat

and blood pressure (changes due to physical work or emotion). The reticular formation influences on the motor system. Through its connections with the nonspecific nuclei of the thalamus, the reticular formation influences the state of consciousness (ascending activation system).

## PONS

Pons is positioned front from the medulla oblongata and communicates with cerebellum by *medii cerebellar peduncle*. Pons has an anterior and posterior surfaces. *Basilar sulcus* located on the anterior surface. Dorsal surface of the pons form upper part of rhomboid fossa. *Striae medullares* separate pons from medulla oblongata. **Gray substance** of the pons is presented by the proper *pontine nuclei*, nuclei of the V-VIII cranial nerves. On the border between anterior and posterior parts of the pons (*tegmentum* and *base of the pons*) the **trapezoid body** lies with the *dorsal and ventral nuclei* in the base. **White substance** of the pons consists of *medial lemniscus*, descending pyramidal tracts and *reticular formation*.

## CEREBELLUM

The cerebellum is the integrative organ for coordination and fine synchronization of body movements and for regulation of muscle tone. It forms the roof of the IVth ventricle. Its superior surface is covered by the cerebrum. The medulla oblongata is imbedded in its inferior surface. There is an unpaired central part, the **vermis** of the cerebellum, and two **cerebellar hemispheres**. This tripartition is only obvious on the inferior surface, where the vermis forms the floor of a furrow, the *vallecula of the cerebellum*. The outer surface of the cerebellum exhibits a number of small, almost parallel convolutions, the **cerebellar folia**, separated by **sulci**. Flocculus located laterally from the brainstem.

On both sides the cerebellum is connected with the brain stem by the cerebellar peduncles, through which pass all the afferent and efferent pathways. Between the two cerebellar peduncles lies the roof of the IVth ventricle with the *superior medullary velum* and the *inferior medullary velum*.

A transverse section reveals the cortex and nuclei of the cerebellum. In a sagittal section the configuration of a tree appears, the so-called **arbor vitae**. The **cerebellar nuclei** lie deep in the white matter:

1. The **fastigial nucleus** (roof nucleus) near the midline in the white matter of the vermis.
2. The **nucleus globosus**.
3. In the **nucleus emboliformis**, at the hilus of the Dentate nucleus
4. The **Dentate nucleus**, fibers of the cerebellar cortex in the region between the vermis and the hemisphere (pars intermedia) are supposed to end.

The efferent and afferent tracts of the cerebellum run through the three cerebellar peduncles:

1) through the **inferior cerebellar peduncle**, which contains the spinocerebellar tracts and the connections with the vestibular nuclei.

2) through the **middle cerebellar peduncle** with fibers from the pons. These arise from the pontine nuclei and form the continuation of the corticopontine tracts.

3) through the **superior (cranial) cerebellar peduncle**, which constitutes the efferent fiber system to the red nucleus and the thalamus.

## ISTHMUS RHOMBOENCEPHALI

Isthmus rhomboencephali develops between the Rhomboencephalon and Mesencephalon and comprises three main parts:

1. the **superior (cranial) cerebellar peduncle**
2. the **superior medullary velum**
3. the **trigone of the lemniscus**, which is bordered by cerebral peduncle, superior (cranial) cerebellar peduncle and inferior brachii of the quadrigeminal plate.

## FOURTH VENTRICLE

Fourth ventricle is a cavity of the rhomboencephalon. Its *roof* is formed by the superior medullary velum with the *tela choroidea* and the inferior medullary velum. The *tela choroidea* contains the choroid plexus, its vessels secrete the cerebrospinal fluid. The floor of the fourth ventricle is formed by rhomboid fossa (dorsal surface of the pons and medulla oblongata). Fourth ventricle communicates with the third ventricle by cerebral aqueduct (Sylvius), also with the subarachnoid space by *median aperture (foramen of Magendie)* and *2 lateral aperture (Luschka's foramen)*.

## RHOMBOID FOSSA

Rhomboid fossa positioned on the dorsal surface of the pons and medulla oblongata and forms the floor of the IVth ventricle. The inferior cerebellar peduncle, medii cerebellar peduncle and the superior cerebellar peduncle border rhomboid fossa. The floor of the rhomboid fossa shows bulges near the *median sulcus* over the nuclei of the cranial nerves: *medial eminence, facial colliculus, trigone of the hypoglossal nerve, trigone of the vagus nerve* and the *vestibular area*.

The rhomboid fossa is crossed by myelinated nerve fibers, the *striae medullares*, which appear at the *lateral recess*. There are processes of the dorsal acoustic nucleus. Rhomboid fossa contains nuclei of the V-XII cranial nerves.

## MESENCEPHALON

Mesencephalon ventrally is formed by the *cerebral peduncles* and dorsally *lamina tecti*. The *cerebral aqueduct* (Sylvius) is a cavity of the mesencephalon. On the dorsal surface of the mesencephalon lies the *quadrigeminal plate*, with two upper and two lower hillocks, the *superior* (subcortical visual centre) and *inferior colliculi* (subcortical hearing centre). *Brachii* from the superior colliculi extend to the *lateral geniculate body*, *brachii* from the inferior colliculi extend to the *medial geniculate body*.

Cerebral peduncles are the thick cords that extend from pons to the cerebral hemispheres. The *interpeduncular fossa* lies between the two peduncles. Its floor is perforated by large numbers of blood vessels, the *posterior perforated substance*. In sulcus on the medial surface of the peduncles there is **oculomotor nerve** [III]. In section of the peduncles *substantia nigra* separates the **tegmen** and the **base**. The base is formed by conducting tracts that pass from cortex cerebri to the spinal cord, medulla oblongata and pons. There are **nucleus ruber** (red) in the tegmen, on the level of superior colliculi **oculomotor** [III] (motor) and **accessory** (Yakubovycha, Edinger-Westphal /parasympathetic/) nuclei are located. On the level of inferior colliculi motor **trochlear** [IV] is located.

Cerebral **aqueduct** (Sylvius) is a narrow canal that connects III and IV ventricles and surrounded by gray substance.

### Nuclei of the V-XII Cranial Nerves

N <sup>o</sup>	Name	Nucleus	Function	Location
<b>V</b>	<b>Trigeminal</b>	Motor nucleus mesencephalic, pontine, spinal nuclei	Motor sensory	Pons, mesencephalon, pons, spinal cord
<b>VI</b>	<b>Abducent</b>	Abducent	Motor	Colliculus facialis (superficially)
<b>VII</b>	<b>Facial</b>	Facial (forms genu) nucleus of the tractus solitarius superior salivatory	Motor Sensory parasympathetic	Colliculus facialis (deep), Pons
<b>VIII</b>	<b>Vestibulo-cochlear</b>	Superior, inferior, medial and lateral vestibular (4), Ventral and dorsal cochlear (2)	All sensory	Vestibular area  lateral recess
<b>IX</b>	<b>Glossopharyngeal</b>	Ambiguus nucleus of the tractus solitarius Inferior salivatory	Motor Sensory parasympathetic	Medial eminence Medulla oblongata
<b>X</b>	<b>Vagus</b>	Ambiguus nucleus of the tractus solitarius dorsal nucleus	Motor Sensory parasympathetic	Medial eminence Medulla oblongata Trigone of the vagus nerve
<b>XI</b>	<b>Accessory</b>	Cranial nucleus, spinal nucleus	Motor Motor	Medial eminence spinal cord
<b>XII</b>	<b>Hypoglossal</b>	hypoglossal	Motor	Trigone of the hypoglossal nerve



## DIENCEPHALON

Diencephalon comprises the thalamencephalon and hypothalamus. Thalamencephalon consists of **thalamus opticus**, **epithalamus** and **metathalamus**. **Hypothalamus** formed by front optic part and back (olfactory) part.

**Thalamus opticus** is a paired body, which consists of gray substance. In the front it carries the *anterior tubercle*. The posterior extremity *pulvinar* is expanded, directed backward and lateralward, and overlaps the superior colliculus. Each thalamus about 4 cm. in length, and presents two extremities, an anterior and a posterior, and four surfaces, superior, inferior, medial, and lateral. Medial surfaces of the right and left thalamus communicated by *interthalamic adhesion*. Upper surfaces of the thalamus are bordered by *stria medullaris* (medial) and *stria terminalis* (lateral). Gray substance forms the *anterior, medial, dorsal* and *ventrolateral* groups of nuclei, which are separated each from other by white substance.

**Epithalamus** consists of the **pineal body (Epiphysis)**, and the *habenulae* with *trigonum habenulae*, the *posterior commissure*. Pineal body is connected with thalamus by the habenulae.

The **Metathalamus** comprises the geniculate bodies, a medial and a lateral. The **medial geniculate body** (*corpus geniculatum mediale*) lies under cover of the pulvinar of the thalamus. The **inferior brachium** from the *inferior colliculus* attaches to the medial geniculate bodies. The **lateral geniculate body** (*corpus geniculatum laterale*) is an oval elevation on the lateral part of the pulvinar. The **superior brachium** from the *superior colliculus* attaches to the lateral geniculate bodies.

Anterior part of the **Hypothalamus** consists of the optic chiasm and *tuber cinereum* with *infundibulum* that carries the *hypophysis*. Posterior part consists of the *mammillary bodies* and *subthalamic region* that carries the *corpus subthalamicum* (nucleus of Luis). The **third ventricle**, the cavity of the diencephalon has 6 walls:

- lateral walls formed by medial surface of the thalamus
- lower wall (floor) formed by hypothalamic region. There are infundibuli recess and optic recess
  - anterior wall formed by terminal lamina, columna fornicis and anterior cerebral commissura
  - anterior wall is formed by the habenular commissure and posterior commissure. There is suprapineal recess
  - upper wall (roof) formed by tela choroidea of the III ventricle with plexus choroideus

There is *interventricular foramen* (of Monro) between anterior thalamic tubercle and columnna fornicis. Foramen communicates the III ventricle with the lateral ventricles of cerebrum. Cerebral aqueduct connects the III ventricle with the cavity of the IV ventricle.

### PINEAL BODY

The pineal body (corpus pineale; epiphysis) is a small, conical, reddish-gray body lies in the depression between the superior colliculi and has an endocrine role. *Habenulae* extend from the epiphysis to the right and left thalamus. The pineal recess of the third ventricle is located near base of the epiphysis. The epiphysis covered by capsule externally, the septa separate glandular parenchyma into lobuli. Special glandular pinealocytes and gliocytes are the cells of the epiphysis. Often there is “sand” in the gland of adults. The epiphysis produces hormone which inhibits the hypophysis activity until puberty age and takes part in regulation of the metabolism.

### HYPOPHYSIS

The hypophysis (pituitary endocrine gland) is a reddish-gray, somewhat oval mass. It is attached to the end of the infundibulum, and is situated in the fossa hypophyseos of the sphenoidal bone, where it is retained by a circular fold of dura mater, the diaphragma sellae. The hypophysis consists of anterior (adenohypophysis) part and posterior (neurohypophysis) part. **Adenohypophysis** has three portions: anterior (or *pars distalis*), *pars intermedia* and *pars tuberalis*. **Neurohypophysis** has *pars nervosa* and *infundibulum*. Adenohypophysis (*pars distalis*) secretes somatotropin, adrenocorticotropin, thyrotropin, folliculotropin, prolactin and luteotropin. *Pars intermedia* produces melanocytestimulating hormone. Neurohypophysis secretes vasopressin and oxytocyn both of which are produced in the hypothalamus.

### TELENCEPHALON

The telencephalon includes the cerebral hemispheres with their cavities, the lateral ventricles.

Each cerebral hemisphere may be divided into three fundamental parts: the pallium, the rhinencephalon, and basal nuclei, also fornix and corpus callosum.

The **Rhinencephalon**, associated with the sense of smell, is the oldest part of the telencephalon, and forms almost the whole of the hemisphere in some of the lower animals, e. g., fishes, amphibians, and reptiles. In man it is rudimentary. It divides into *central* and *peripheral* parts. The central part includes the hippocampus, gyrus fornicatus (gyrus cinguli + gyrus hippocampi), gyrus dentatus, septum pellucidum and uncus. The peripheral part includes the olfactory bulb, olfactory tract, olfactory trigone and anterior perforated substance. Cortical smell analyzer located in the *uncus*. Rhinencephalon is a center of emotional colouring of sensible perception of external environment (**Limbic system**). Together from all subcortical centers it is by energy source for cortex and answers for vitally important man reactions regulates activity of internal organs: hunger feeling and thirst, sounds perceptions and smells. Here are the memory mechanisms.

**Basal nuclei** are the paired masses of gray matter located deep within the white matter in base of the forebrain. Basal nuclei include 1) corpus striatum, 2) claustrum and 3) nucleus amygdaloideus.

**Corpus striatum** is composed of **caudate nucleus** (it has a head, body and tail) and **lentiform nucleus** (it consists of medial and lateral globus pallidus and putamen). There is a thick lamina of white substance, the **internal capsule** between caudate nucleus and globus pallidus. It has the prominence of the curve is called the *genu*, the *frontal crus* and the *occipital crus*. The occipital crus separates the lentiform nucleus from the thalamus and carries *optic and acoustic radiation*.

The **nucleus amygdaloideus** is an ovoid gray mass situated at the lower end of the inferior cornu of the lateral ventricle (in temporal lobe).

**White Matter of the Cerebrum.** The **external capsule** located between putamen and claustrum. The **extrema capsule** separates the claustrum and cortex of the insula.

The **corpus callosum** connect right and left cerebral hemispheres. Corpus callosum anteriorly carries a *genu* that passes into *rostrum*. Last continue as a *lamina rostralis* and *lamina terminalis*. Back part of the corpus callosum called *splremium*. Anterior fibers of the corpus callosum form the *frontal forceps*, posterior fibers of the corpus callosum – the *occipital forceps*.

The **fornix cerebri** located under corpus callosum and has a *body*, *columna fornicis* (anteriorly) and *crura fornicis* (posteriorly). Crus fused with the hippocampus and form the *fimbria hippocampi*. **Anterior commissura** positioned closely to the columna fornicis.

The **septum pellucidum** is tightened between corpus callosum and fornix. It consists of the 2 *laminae* and *cavity* between them.

### **Cortex of the Cerebrum**

A **hemisphere** is covered by **cortex** and has *inferior, dorsolateral* and *medial* surfaces. The anterior end of the hemisphere is named the *frontal pole*; the posterior, the *occipital pole*; and the anterior end of the temporal lobe, the *temporal pole*. The right and left hemispheres are separated medially by a deep cleft, named the **longitudinal cerebral fissure**. The surfaces of the hemispheres are molded into a number of irregular eminencies, named **gyri** or convolutions, and separated by furrows termed **fissures** and **sulci**. The hemispheres consist of 5 lobes: frontal, parietal, occipital, temporal and insula (located in depth of lateral sulcus).

On the dorsolateral surface of the hemisphere can be finding the **Central sulcus** [Rolandi] that separates frontal and parietal lobes. The **Lateral sulcus** [Sylvii] that separates temporal lobe from the frontal and parietal lobes. **Parietooccipital** sulcus passes between parietal and occipital lobes on the medial surface.

There are some sulci on the *dorsolateral* surface of the **frontal lobe**: precentral sulcus, superior frontal sulcus, and inferior frontal sulcus. They separate: precentral gyrus, superior frontal gyrus, middle frontal gyrus, and inferior frontal gyrus. The inferior frontal gyrus is divided into opercular, triangular and orbital parts by anterior and ascending rami.

The lateral surface of the **parietal lobe** is cleft by a well-marked furrow, the intraparietal sulcus and the postcentral sulcus. There are postcentral gyrus, superior parietal lobule and inferior parietal lobule. The last contains the supramarginal and angular gyri.

The **temporal lobe** is divided into superior, middle, and inferior gyri by the superior and middle temporal sulci. Three or four gyri will be seen springing from the depth of the hinder end of the lateral sulcus, these are named the *transverse temporal gyri* (Heschl).

The **occipital lobe** is small and pyramidal in shape. It is traversed by the transverse occipital sulci that border occipital gyri.

On the **insula** (it is located in depth of lateral sulcus) they distinguish circular and central sulci which border longi and breve gyri.

There are some sulci on the *medial* surface of the hemisphere: sulcus corporis callosi, cingulate sulcus, hippocampal sulcus, parietooccipital and calcarine sulcus. They separate corpus callosum from gyrus cinguli, superior frontal gyri, gyrus parahippocampalis, dentate gyrus, paracentral lobule (of Bets), precuneus and cuneus. Gyrus cinguli and gyrus

parahippocampalis with isthmus form fornicate gyrus that it is the central part of the rhinencephalon.

On the **inferior** surface of the hemisphere can be finding: collateral sulcus, occipitotemporal sulcus, rhinal sulcus and orbital sulcus. They separate the lateral occipitotemporal gyrus, medial occipitotemporal gyrus, lingual gyrus, gyrus rectus and orbital gyri.

### **Cortical Fields**

We distinguish some specific cortical fields that control motor, sensory, language and others functions. They can be divided into more general motor area, sensory area and also some specific sensory centres.

**Motor area** involved with the control of voluntary muscles. It is located in precentral gyrus and paracentral lobule (motor homunculus).

Centre of conjugate deviation of the eyes to the opposite side is located in posterior part of the middle frontal gyrus.

**Sensory area** responsible for cutaneous and muscular sensations (temperature, pain and tactile), located in postcentral gyrus and paracentral lobule (sensory homunculus).

Centre of stereognosis is located in superior parietal lobule closely to intraparietal sulcus. It responsible for the *body schema*: the right can be differentiated from the left.

Auditory centre located in the transverse temporal gyri (Heschl). Function is interpretation of auditory sensations.

Visual cortical centre situated in calcarine sulcus. Function of the occipital lobe is conscious perception of vision.

Smell and tasting centre located in part of limbic system – uncus.

Centre of praxia is located supramarginal gyrus.

Language areas:

motor -

1. Motor speech area (Broca's centre). Damage in the region of the lower frontal convolution produces motor aphasia.

2. Writing (graphic) area located in middle frontal gyrus.

sensory -

3. Auditory language centre (Wernicke's area) located in superior temporal gyrus. It responsible for understanding of spoken language.

4. Reading centre situated in angular gyrus (responsible also for reading, writing, counting and calculating).

### **Lateral ventricles**

The two lateral ventricles are cavities situated in the lower and medial parts of the cerebral hemispheres. They are separated from each other by a median vertical partition, the **septum pellucidum**, but communicate with the third ventricle and indirectly with each other through the **interventricular foramen**. Each lateral ventricle consists of a central part, and three prolongations from it, termed anterior, posterior and inferior cornua.

The anterior horns passes forward into the frontal lobe. It bordered:

- medially – by lamina of septum pellucidum
- laterally – by head of caudate nucleus
- anteriorly and roof – by corpus callosum

Central part is found in parietal lobe. It is limited:

• below – by body of caudate nucleus and dorsal surface of the thalamus;

• upwards and laterally – by fibers of corpus callosum, which form a roof.

The posterior horns localised in occipital lobes and cover by white matter ‘tapetum’. They carry the bulb and the calcar avis on medial wall, and a collateral triangle on the floor.

The inferior horns are found in temporal lobe. They are bounded:

- medially – by hippocampus;
- below – by white matter, which forms collateral eminence;
- superolaterally – by white matter;
- superomedially – by a tail of caudate nucleus.

The central part and temporal horn of lateral ventricle contain *choroid plexus* of lateral ventricle generated of penetration pia mater by vessels. Choroid plexus passes to the III ventricle through interventricular foramen. Choroid plexus takes part in formation of larger half of cerebrospinal fluid.

A **cerebrospinal fluid** passes from lateral ventricles through the interventricular foramen into third ventricle, where its amount increases. Then it flows from third ventricle through the cerebral aqueduct into fourth ventricle. In the fourth ventricle a cerebrospinal fluid passes the subarachnoid space through the median (of Magendie) and lateral (of Luschka) aperture and also to the central canal of the spinal cord. Cerebrospinal fluid of the subarachnoid space returns to the venous blood in the venous sinuses through the Pachioni’s arachnoid granulation.

## **Meninges of the brain**

The brain is enclosed by in 3 meninges: **dura mater, arachnoid** and **pia mater**. Dura mater is the periosteum for internal surface of the skull bones and there is no space between dura mater and bones. There is **subarachnoid space** between choroid and pia mater, which is filled in by cerebrospinal fluid. This space has expansions, which are called ‘cisterns’:

- cerebellomedullary cistern;
- chiasmatic cistern;
- interpeduncular cistern;
- cistern of the lateral fossa;
- pontocerebellar cistern;
- superior cistern.

Dura mater has some processes extend into the cavity of the skull and separating the brain parts:

• *Falx cerebri* occupies a longitudinal fissura cerebri and separates the brain to right and left hemispheres;

• *Falx cerebelli* lies in longitudinal cerebellum furrow and separates it into right and left cerebellum hemispheres;

• *Diaphragma sellae* closes hypophysial fossa, separating a hypophysis from diencephalon.

• *Tentorium cerebelli* occupies a tranverse fissura cerebri and separates the cerebellum from the occipital lobe of the telencephalon.

• Dura mater forms a *trigeminal cavity* on anterior surface of the temporal pyramide.

The processes of dura mater approaching sulcuses on the skull bones slit and fasten to sulcus edges, forming the **venous sinuses** where venous blood flows:

- superior sagittal sinus;
- inferior sagittal sinus;
- straight [rectus] sinus;
- occipital sinus;
- inferior petrosal sinus;
- superior petrosal sinus;
- transverse sinus;
- cavernous sinus;
- intercavernous sinus;
- sphenoparietal sinus;
- sigmoid sinus.

These sinuses flow together in *confluence sinuum*. Venous blood from all sinuses passes into sigmoid sinus, and then – into internal jugular

vein. The arachnoid forms the Pachioni's *arachnoid granulation*. They extend from venous sinuses in internal surface skull vault bone and form foveoli granulares. Arachnoid granulations provide a cerebrospinal fluid flow from subarachnoid space into venous blood. Emissary veins and diploic veins communicate the sinuses of dura mater with the superficial head veins.

### **Blood supplying of the Brain and Spinal cord**

System of internal carotid, subclavian and posterior intercostal arteries supply the brain and spinal cord. **Internal carotid artery** passes into skull through the carotid canal and gives off the *anterior cerebral* arteries for medial surface of frontal, parietal lobes of cerebrum. The anterior cerebral arteries (right and left) united by *anterior communicating* artery. *Middle cerebral* artery passes in lateral sulcus and reach the temporal and parietal lobes of cerebrum. The anterior choroid artery starts from the internal carotid artery and forms the choroid plexus of the cerebral ventricles. *Posterior communicating* artery joins the internal carotid artery with posterior cerebral artery (from system of subclavian artery).

Subclavian artery gives off **vertebral artery**, which passes through foramen in transverse processes of the cervical vertebrae and foramen magnum into cranial cavity. Posterior spinal arteries spring from vertebral arteries. Right and left anterior spinal arteries start from the vertebral arteries then join together forming Zacharchenko's circle. Both *anterior* and *posterior spinal* arteries supply the spinal cord.

Right and left vertebral arteries join together to form **basilar artery** laying in basilar sulcus of the pons. Branches from basilar artery supply cerebellum, pons, midbrain and internal ear. In of front pons basilar artery ramifies into right and left *posterior cerebral* artery which supply occipital and temporal lobes, midbrain and diencephalon. In subarachnoid space on the base of cerebrum there is **arterial circle** (of Willis [Wilizii]). This circle is generated by internal carotid, anterior and posterior cerebral, anterior and posterior communicating arteries.

Venous sinuses, superficial and deep veins of brain, veins of the dura mater, bone veins drain the brain. As result venous blood reaches the internal jugular vein.

**Pathways of the brain and spinal cord** subdivide into: associative, commissural and projection fibers.

**Associative pathways** are the tracts communicating functional areas of one hemisphere. They can be divided into long associative fibres and short associative fibres. The long associative pathways include:

MC



1. Superior longitudinal fascicle communicates frontal, parietal and occipital lobes;
2. Inferior longitudinal fascicle communicates parietal, occipital, temporal lobes;
3. Uncinate fascicle – communicates frontal, parietal and temporal lobes;
4. Fornicate fascicle – communicates central areas of rhinencephalon;

To short associative tracts are *arcuate fibres* of the cerebrum, which communicate neighbouring convolutions within hemisphere.

The **Commissural pathways** communicate symmetric areas of both hemispheres of cerebrum and both halves of spinal cord for co-ordination of their activity. There are:

1. corpus callosum;
2. anterior cerebral commissura;
3. posterior cerebral commissura;
4. habenular commissura;
5. fornicate commissura;
6. interthalamic adhesion;
7. posterior white commissura of spinal cord.

The **Projecting pathways** are the tracts, which communicate the cerebrum and spinal cord with working organs. They subdivided into ascending (sensible) and descending (motor). The sensible projecting tracts into its turn subdivide into exteroceptive, interoceptive and proprioceptive. The motor projecting fibers tracts are pyramidal and extrapyramidal.

To exteroceptive (E) tracts belong the tracts temperatural, palpable, pain sensivity, also vision, hearing, olfaction. The proprioceptive (P) tracts subdivided into tracts of cortical direction (Goll tracts and Burdach) and cerebellar directions (Flechsig and Gowers tracts). Anterior and lateral corticospinal tracts and also corticonuclear tract belong to pyramidal pathways. The extrapyramidal tracts include rubrospinal, vestibulospinal, reticulospinal, olivospinal pathways.

(E) Pain and temperature sensation pathway (**Lateral spinothalamic tract**).

1. Body of first neuron is found in *spinal* ganglion. The peripheral process of this neuron terminates by exteroceptor in skin, and central – on the strength of posterior rootlets into posterior horns of spinal cord, where contacts with second neuron.

2. The second neuron localised in proper nucleus of posterior horns of spinal cord. Its axons make a crossing in grey commissura of spinal cord and pass in lateral funiculus (lateral spinothalamic tract). Axons within the medial of lemniscus reach the thalamus, where terminate by synapse with body of third neuron.

3. The third neuron is in lateral nucleus of *thalamus*, and its axons 'thalamocortical tract' pass to postcentral gyrus (cortical analyser of skin sensation) through the back third of internal capsule.

(E) Pressure and touch sensation pathway (**Anterior spinothalamic tract**).

1. Body of first neuron is found in *spinal* ganglion. The peripheral process of this neuron terminates by exteroceptor in skin, and central – in the gelatinose substance of spinal cord, where contacts with second neuron.

2. The second neuron axons make a crossing in grey commissura of spinal cord and pass in lateral funiculus (anterior spinothalamic tract). Axons reach the thalamus, where terminate by synapse with body of third neuron.

3. The third neuron is in *thalamus*, it passes to postcentral gyrus (cortical analyser of skin sensation) through the back third of internal capsule.

Proprioceptive pathway (cortical direction) – Bulbothalamic tract.

1. The first neuron of this tract lies in spinal ganglion. Its peripheral process terminates by proprioceptor in muscles, tendons, joints capsules and ligaments. The central process passes with posterior rootlets into spinal cord and form in white matter Goll tract – fascicle (upper 11 segments). The process passes to *medulla oblongata*, where terminate by synapse with second neuron.

2. The second neurons are in gracilis and cuneate nuclei of *medulla oblongata*. Axons this neuron form bulbothalamic tract, which composes a base of medial lemniscus. Axons of second neuron cross (deccusation of lemniscus) and reach the *thalamus*, where terminate by synapse with third neuron.

3. The third neurons pass through the internal capsule and form the thalamocortical tract.

(P) Proprioceptive pathways with cerebellar direction (Spino-cerebellar tracts).

**Posterior spinocerebellar tract** (Flechsig tract)

1. The first neuron is in *spinal* ganglion. Its peripheral process terminates by proprioceptor and central with the posterior rootlets of spinal cord passes to the grey matter.

2. The second neuron lies in thoracic nucleus of posterior horns (Clarck-Steiling). Its axons pass in lateral funiculus. Then it reaches the cortex of the *cerebellar* vermis through the inferior cerebellar pedunculi and *dentate nucleus*. Nervous impulse passes to the ruber nucleus.

**Anterior spinocerebellar tract** (Gowers tract). Two-neurons way. This tract differs from previous by its second neuron, a body of which is found in medial intermediate nucleus of spinal cord. Axons of the second neuron get across and pass into lateral funiculus, reaching the superior cerebral velum. They cross here and pass to the vermis and dentate nucleus. Nervous impulse also passes to the ruber nucleus.

### **Lateral corticospinal (pyramidal) tract**

1. A Body of first neuron is found in gigantic pyramidal cells (Bets) of top and middle third of precentral gyrus of the *cortex*. Axons pass through anterior third part of internal capsule, pons, medulla oblongata; part of fibres gets across forming the pyramids. The crossed fibres of first neuron pass in lateral funiculus of the spinal cord 'lateral corticospinal (pyramidal) tract' and terminate in anterior horns of spinal cord.

2. The second neuron lies in motor nucleus of anterior horns, and its axons pass with the anterior rootlets and *spinal* nerves as far as skeletal muscles of the trunk and extremities.

### **Anterior corticospinal (pyramidal) tract**

1. Major part of fibres of first neurons of anterior corticospinal tract does not cross in pyramids of medulla oblongata, and passes in anterior funiculus of the spinal cord. Axons cross in grey commissura terminate by synapse with bodies of second neurons. first

2. The second neuron lies in motor nucleus of anterior horns, and its axons pass within the anterior rootlets and spinal nerves as far as skeletal muscles of the trunk and extremities.

### **Corticenuclear tract**

1. The first neuron of this tract is found in gigantic pyramidal cells of cortex in lower third of precentral gyrus. Axons pass through the genu of internal capsule, base of cerebral peduncles and terminate in motor nucleus of rhomboid fossa and midbrain, previously passing across partially on opposite side.

2. The second neuron lies in motor nucleus of rhomboid fossa and midbrain of opposite side, and its axons with cranial nerves pass as far as striped muscles of the head and superficial neck muscles.

*Extrapyramidal pathways* transmit impulses providing muscles tone and reflexes of equilibrium and execution of automated motions. They include rubrospinal, tectospinal, vestibulospinal, reticulospinal and olivospinal tracts.

### **Rubrospinal tract**

1. The first neuron is found in red nucleus (n. ruber). Its axons make tegmental decussation and pass through the base of cerebral peduncles, pons, and medulla oblongata. They form tract in lateral funiculus and reach motor nuclei in anterior horns of spinal cord.

2. The second neuron lies in motor nucleus of anterior horns of spinal cord, and its axons on the strength of anterior rootlets and spinal nerves reach trunk and extremities muscles.

This 2-neuron tract is descending link for reflex link of unconscious motion coordination. Spinocerebellar tracts (Flechsig and Gowers tracts) are the ascending links for this regulation. Spinocerebellar tracts send impulses for rubrospinal tracts through the intermediate link (from cerebellar vermis and dentate nuclei to the ruber nuclei).

**Corticopontocerebellar tract** (way of cortical correction of the cerebellum)

This 2-neuron tract starts from all lobes of cerebral hemispheres. Axons run through the internal capsula to the proper pontini nuclei. Second neurons cross and pass to the cerebellar vermis through the middle cerebellar pedunculi. Some links directed also to dentate and ruber nuclei. This pathway materializes cortical correction of unconscious motion coordination.

## **AUTONOMIC NERVOUS SYSTEM**

**Autonomic (vegetative) nervous system** – this is part of nervous system, which provides innervation of all vessels, internal organs, smooth

muscles and glandular epithelium including. It co-ordinates work of all of internal organs, regulates the metabolic and trophic processes in all organs and walls, supports organism homeostasis. Function of autonomous department controlled by influence of higher autonomous (vegetative) centres, which are contained in cerebellum, hypothalamus, and basal nuclei of forebrain and in cortex of cerebrum. This department has a row of peculiarities, which distinguish it from *somatic nervous system*:

– group localization of autonomic (vegetative) nuclei in central nervous system:

- higher autonomic center – **hypothalamus**, frontal cortex of the hemisphere, cerebellum

- midbrain

- rhomboid fossa

- spinal cord

– congestion of effector neuron bodies in ganglia;

– 2 neurons tract from central autonomous (vegetative) system to organ:

– 1<sup>st</sup> neuron – preganglionic, 2nd neuron – postganglionic;

– major part of peripheral fibers of autonomous part does not have myelin coat;

– speed of nervous impulse on autonomous part is lesser, than in somatic nervous system;

Autonomous nervous system has sympathetic and parasympathetic divisions.

## SYMPATHETIC (THORACOLUMBAR) DIVISION

Sympathetic centres are located in *lateral intermediate nuclei* of lateral horns (spinal cord segments C<sub>8</sub>-Th<sub>1</sub>-Th<sub>12</sub>-L<sub>1</sub>-L<sub>2</sub>).

Peripheral sympathetic division includes right and left sympathetic trunks, communicating branches, prevertebral sympathetic ganglia, plexuses and fibbers, which pass to organs and tissues.

*Sympathetic trunk* is a paired formation, which is found on sides from vertebral column and consists of 20-25 paravertebral sympathetic ganglia, joint between each other by interganglionic rami. The white communicating branches from spinal nerves approach to sympathetic trunk. They are preganglionic fiber (passes from lateral intermediate nucleus in composition of anterior rootlets and spinal nerve to nearest paravertebral

sympathetic ganglion). The white communicating branches pass to eighth cervical, all thoracic and two top lumbar spinal ganglion.

Sympathetic trunk consists of 3 cervical, 10-12 thoracic, 4-5 lumbar, 4-5 sacral and one unpaired coccygeal ganglia. White communicating branches (preganglionic fibers) approach to upper cervical, lower sacral and coccygeal ganglia by the interganglionic branches. Ganglia of sympathetic trunk give off the gray communicating branches, which direct to nearest spinal nerve and contain postganglionic fibers.

**Superior cervical ganglion** is a largest ganglion of sympathetic trunk, is located in the level of transversal processes of 2-3 cervical vertebrae. Superior cervical ganglion gives off the following branches:

- gray communicating rami for I-IV cervical spinal nerves;
- internal carotid nerve passes to carotid artery and forms internal carotid plexus, which passes into cranial cavity. Sympathetic rootlet for pterygopalatine ganglion (radix sympathica – deep petrosal nerve) separates from internal carotid plexus. *Deep petrosal nerve* passes through the pterygopalatine canal get the pterygopalatine fossa, transitory passing through the ganglion and realize innervation of the vessels and glands of mucous membrane of the nose cavity and mouth, conjunctive and face skin;
- jugular nerve is passes on wall of internal jugular vein, where divides into branches passing to the 9<sup>th</sup>, 10<sup>th</sup> and 11<sup>th</sup> cranial nerves;
- laryngo-pharyngei nerves take hand in formation laryngo-pharyngeus plexus, innervating mucous membrane and vessels of the pharynx and larynx;
- superior cervical cardiac nerve passes down parallelly with sympathetic trunk, to deep part of cardiac plexus.

**Middle cervical ganglion**, inconstant, located anteriorly from transversal process of 6th cervical vertebra. This ganglion is connected with superior and inferior ganglia by interganglionic rami. They form subclavian loop around subclavian artery. Middle cervical ganglion gives off such branches:

- gray communicating branches to V-VI cervical spinal nerves;
- common carotid nerves, which take hand in formation of external carotid plexus and plexus of inferior thyroid artery;
- middle cervical cardiac nerve passes alongside of superior cervical cardiac nerve and enters into deep part of cardiac plexus.

**Inferior cervical ganglion** frequently flows together with first thoracic ganglion and forms a cervicothoracic ganglion (stellate ganglion).

It lies on neck of first rib, behind subclavian artery. Ganglion gives off the following branches:

- gray communicating branches to VI-VIII cervical spinal nerves;
- subclavian nerves, which form subclavian plexus, that ramifies on branches of this artery;
- branches to vagus and phrenic nerves;
- vertebral nerve, which forms vertebral plexus round vertebral artery.

This plexus spreads with branches of vertebral artery to spinal cord and brain meninges;

- inferior cervical cardiac nerve is passes to deep part of cardiac plexus.

**Thoracic ganglia** of sympathetic trunk (10-12), which are contained near caput of ribs laterally from vertebral bodies. Thoracic ganglia receive the communicating white branches containing preganglionic fibers. Thoracic ganglia give off the following branches:

- gray communicating branches, which approach to intercostal nerves;
- thoracic cardiac nerves being a party to forming of cardiac plexus;
- thoracic pulmonary branches passing to bronchi and lungs, forming pulmonary plexus;
- thoracic aortic rami, which form thoracic aortic plexus;
- major splanchnic nerve, formed by branches from VI-IX thoracic ganglia and consist overwhelmingly of preganglionic fibers. This nerve passes through the lumbar part of diaphragm into abdominal cavity and terminates in ganglia of abdominal plexus;
- minor splanchnic nerve starts from X-XI thoracic sympathetic ganglia and also has preganglionic fibers. It passes down into abdominal cavity (through the lumbar part of diaphragm) and enters into ganglia of abdominal plexus.

The **lumbar ganglia** of lumbar department of sympathetic trunk are represented by 4-5 ganglia and interganglionic branches. These ganglia are found on anterior-lateral surface of lumbar vertebrae bodies. The lumbar ganglia of right and left sympathetic trunk unite between oneself by communicating branches. The first and second lumbar ganglia approach the communicating white branches. Each ganglion gives off the gray communicating branches to lumbar spinal nerves and *lumbar splanchnic* nerves, which pass to abdominal plexus and have both preganglionic and postganglionic nervous fibers.

**Sacral ganglia** of sympathetic trunk formed by 4 ganglia, which lie on pelvic surface of sacrum, medially from pelvic sacral foramen. The right and left sympathetic trunks terminate in unpaired (coccygeal) ganglion.

The sacral ganglia of right and left side unite each other by transversal branches. They give off communicating gray branches for sacral spinal nerves and sacral splanchnic nerves, which pass to superior and inferior hypogastric autonomic (vegetative) plexus.

Preganglionic fibers in composition of major and minor splanchnic nerves, and also lumbar splanchnic nerves approach to the *prevertebral* sympathetic ganglia, which lie at the anterior surface of backbone closely to celiac trunk and superior mesenteric artery. This semilunar-shaped *celiac ganglia*, *superior mesenteric ganglion*, *aortorenal ganglia*, *phrenic ganglia*, *renal ganglia* and some other. Postganglionic fibres from them pass to organs together with blood vessels and form same name plexus. Celiac plexus (the biggest) supplies a liver, spleen, stomach, pancreas, small intestine and large intestine (to descending colon).

Celiac plexus continues around abdominal aorta, forming *abdominal aortic plexus*. It innervates kidney, suprarenal glands, ureters and testicles (ovaries).

*Inferior mesenteric plexus* starts closely to inferior mesenteric artery. It innervates descending and sigmoid colon, superior part of the rectum. *Superior hypogastric plexus* located in point of aortic bifurcation. It receives splanchnic nerves from lower lumbar and upper sacral sympathetic ganglia. Superior hypogastric plexus divides into right and left *inferior hypogastric plexuses* lower then promontorium. Inferior hypogastric plexus reaches the organs and tissues of lesser pelvis with arterial branches from internal iliac artery. It innervates seminal vesicles, prostate (male) uterus, Fallopian tubes, vagina (female), also rectum, urinary bladder.

## PARASYMPATHETIC (CRANIOSACRAL) DIVISION

**1. Central part** of parasympathetic division consists of the cranial part and pelvic part. *Cranial part* located in midbrain and rhomboid fossa. *Mesencephalic* portion contains accessory oculomotor (Yakubovych-Edinger-Westphal) nucleus, and *bulbar portion* contains superior salivary nucleus and inferior salivary nucleus and dorsal nucleus of vagus nerve. *Pelvic* part carries the parasympathetic nuclei, which lie in gray matter of sacral segments  $S_{II} - S_{IV}$  of spinal cord.

**2. Peripheral part** consists of the *ganglia*, nerves and fibers.

*Ciliary ganglion* is formed by bodies of second /postganglionic/ neurons. It positioned in orbite near the optic nerve. The preganglionic fibres start from accessory oculomotor (Yakubovych-Edinger-Westphal)



nucleus in composition of oculomotor nerve and separate from inferior branch as a *radix oculomotorius*, terminate by synapse with cells in ciliary ganglion. The postganglionic nervous fibres in composition of *short ciliary nerves* (nervi ciliares breves) pass to sphincter muscle of pupil and ciliary muscle. Sensory branches of nasociliary nerve and sympathetic postganglionic fibres from cavernous plexus pass through the ganglion.

**Pterygopalatine ganglion** lies in pterygopalatine fossa. It receives parasympathetic preganglionic fibres from superior salivary nucleus (with greater petrosal nerve). Last forms n. canalis pterygoidei (Vidian nerve) with sympathetic rootlet (from internal carotid plexus), sympathetic neurons innervate blood vessels. The postganglionic fibres join the ganglionic (sensory) nerves from maxillary nerve. Zygomatic nerve carries parasympathetic fibres to the lacrimal nerve (through the communicating branch) for innervating lacrimal gland. Nasal and palatine nerves provide complete innervating of the mucous membrane (and glands) in nasal cavity and palate.

**Submandibular ganglion** lies on medial surface same name salivary gland. Preganglionic parasympathetic fibres start from superior salivary nucleus in composition of *chorda tympani*. Last joins the lingual nerve that gives off sensory twigs for ganglion. Postganglionic fibres from this ganglion together with sensory and sympathetic fibres (from facial plexus) innervate submandibular salivary gland (often also sublingual gland).

**Sublingual ganglion** /inconstant/ located on external surface of sublingual salivary glands. It receives and gives off the same branches as submandibular parasympathetic ganglion.

**Otic ganglion** adjoins with mandibular of nerve under ovale foramen. This ganglion obtains parasympathetic innervation from inferior salivary nucleus (lesser petrosal nerve). Postganglionic fibres in composition of auriculotemporal nerve innervate parotid salivary gland. Postganglionic sympathetic fibres (from middle meningeal plexus) which innervate the vessels of parotid salivary glands.

**Parasympathetic part** of X vagus nerve commences in dorsal nucleus of vagus nerve and contains a numerous of intramural ganglia. These ganglia enter to composition of cardiac, esophageal, pulmonary, gastric, intestinal, and others splanchnic plexus. Postganglionic neurons supply smooth muscles, glands and vessels of internal organs in neck, thoracic and abdominal regions.

Parasympathetic nerves of the pelvis origin from nuclei in sacral segments  $S_{II} - S_{IV}$  of spinal cord. Preganglionic fibers [**pelvic splanchnic nerves**] pass to the terminal ganglia near organs. Postganglionic fibers

innervate urinary bladder, reproductive organs, Lower half of descending colon, sigmoid colon and rectum.

## SENSORY ORGANS

### VISUAL ORGANS

**Eye** consists of eyeball, auxiliary eye organs and the optic nerve. Eyeball has nucleus and wall. Auxiliary eye apparatus includes eyelids, muscles of eyeball, lacrimal apparatus, orbital fasciae, vessels and nerves.

**Eyeball** is surrounded by adiposal body of orbita, muscles of eyeball and orbital fascia. Bony orbit is covered by periorbita. It has an anterior pole, posterior pole, and axis. Axis courses between poles. Optic axis starts from anterior pole to central fossa of the retina. Line that is found transversal on surface of eyeball and is found in the middle to distance between poles is called equator, and line passing perpendicularly to equator is called meridian.

Eyeball wall consists of three coats: fibrous (external), vascular (middle) and internal (retina).

**Fibrous** coat of eyeball subdivides on transparent *cornea* (anteriorly) and *sclera* (the rest). Venous sinus of sclera (Schlemm's canal) localised between cornea and sclera.

**Vascular** eye coat has: 1] proper vascular coat '*choroidea*', which connects with sclera and delimited by perivascular space. 2] *Ciliary body* consists of ciliary corona and by 70 ciliary processes. There is ciliary muscle in ciliary body, its contraction provides eye accommodation. 3] *Iris* carries the round orifice in centre – *pupilla*. Smooth muscles, which form a pupil muscle-sphincter and pupil muscle-dilator are round the pupil.

Internal coat of eyeball – '*retina*'. There are external pigmental layer and internal nervous layer in visual part of the retina. According to function they distinguish posterior larger visual part of retina, which contains rods and cones, and lesser blind part of retina. There are neither rods nor cones in blind part. Ora serrata is the boundary between optic and blind parts, which accords with transition of choroid into ciliary body. In posterior part of retina is found a disc of the optic nerve that has a small concavity. Macula is located in the centre of retina. Central fossa is the place of best sight sharpness, where is observed most rods and cones.

**Nucleus** of eyeball consists of vitreous body, lens, and aqueous humor in anterior and posterior chambers.

**Vitreous body** represents by transparent mass without any vessels. It occupies largest portion of eyeball behind lens.

The transparent **lens** consists of tight layers of proteins. The thin, clear lens **capsule** encloses the lens and provides attachment for the **suspensory ligament (zonular fibers)**.

**Anterior chamber** of eyeball placed between posterior surface of cornea surface and anterior surface of the iris. **Posterior chamber** is found between posterior surface by iris and anterior surface of lens. The anterior and posterior chambers are filled by *aqueous humor*, which produced by ciliary processes of ciliary body and unite each other by the medium of pupil. Between cornea and iris is found iridocorneal corner, which is filled by pectinate ligament with the Fontana's spaces. Aqueous humor drains from anterior chamber through fountain spaces to the Schlemm's canal (venous sinus of sclera).

Additional eye structures include: extrinsic muscles of eyeball, eyebrows, eyelids, conjunctiva, lacrimal apparatus.

### **Extraocular Musculature**

#### ***Levator palpebrae superioris***

•Origin: inferior aspect of the lesser wing of sphenoid (adjacent to the common annular tendon) •Insertion:

1.medial and lateral walls of the orbit 2.superior tarsus

•Action: elevates the eyelid •Blood: branches of ophthalmic artery

•Nerve: oculomotor nerve (III cranial)

#### ***Lateral rectus***

•Origin:

1.common annular tendon (which comes off the body and lesser wing of sphenoid) 2.margins of the optic canal

•Insert: posterior to the sclerocorneal junction (each muscle inserting along its own directional axis) •Action: abducts eye •Blood: branches of ophthalmic artery •Nerve: abducens nerve (VI cranial)

#### ***Medial rectus***

•Origin:

1.common annular tendon (which comes off the body and lesser wing of sphenoid) 2.margins of the optic canal

•Insert: posterior to the sclerocorneal junction (each muscle inserting along its own directional axis) •Action: adducts eye •Blood: branches of ophthalmic artery •Nerve: oculomotor nerve (III cranial)

### ***Superior rectus***

•Origin:

1.common annular tendon (which comes off the body and lesser wing of sphenoid) 2.margins of the optic canal

•Insert: posterior to the sclerocorneal junction (each muscle inserting along its own directional axis) •Action:

1.elevates 2.medially rotates 3.adducts the eye

•Blood: branches of ophthalmic artery

•Nerve: oculomotor nerve (III cranial)

### ***Superior rectus***

•Origin:

1.common annular tendon (which comes off the body and lesser wing of sphenoid) 2.margins of the optic canal

•Insert: posterior to the sclerocorneal junction (each muscle inserting along its own directional axis) •Action:

1.elevates 2.medially rotates 3.adducts the eye

•Blood: branches of ophthalmic artery

•Nerve: oculomotor nerve (III cranial)

### ***Inferior rectus***

•Origin:

1.common annular tendon (which comes off the body and lesser wing of sphenoid) 2.margins of the optic canal

•Insert: posterior to the sclerocorneal junction (each muscle inserting along its own directional axis) •Action:

1.depress 2.laterally rotates 3.adducts the eye

•Blood: branches of ophthalmic artery

•Nerve: oculomotor nerve (III cranial)

### ***Superior oblique***

•Origin: body of sphenoid •Insert: upper lateral quadrant of the posterior half of the sclera (via the trochlea, as a pulley) •Action:

1.depress 2.medially rotates 3.abducts the eye

•Blood: branches of ophthalmic artery

- 1.depress 2.medially rotates 3.abducts the eye
- Blood: branches of ophthalmic artery
- Nerve: trochlear nerve (IV cranial)

***Inferior oblique***

- Origin: orbital surface of maxilla •Insert: lower lateral quadrant of the posterior half of the sclera (via the suspensory ligament, as a pulley)
- Action:
  - 1.elevates 2.laterally rotates 3.abducts the eye
- Blood: branches of ophthalmic artery
- Nerve: oculomotor nerve (III cranial)

**Extrinsic ocular muscles subdivide into recti (straight) and oblique**

<i>Muscle</i>	<i>Rotation of eyeball</i>	<i>Cranial nerve innervation</i>
Lateral rectus	Lateral	Abducens (VI)
Medial rectus	Medial	Oculomotor (III) - inferior branch
Superior rectus	Superior and medial	Oculomotor (III) - superior branch
Inferior rectus	Inferior and medial	Oculomotor (III) - inferior branch
Inferior oblique	Superior and lateral	Oculomotor (III) - inferior branch
Superior oblique	Inferior and lateral	Trochlear (IV)

They originate in common annular tendon and insert into sclera and can rotate eyeball on frontal and vertical axis. As result pupilla moves up, down laterally and medially. Superior oblique muscle passes through a pulleylike cartilagenous loop, the trochlea, before attaching to the eyeball. **Levator palpebrae superioris** muscle elevates upper eyelid.

Periosteum of orbit is ‘*periorbita*’ forming the cover of bones and passes through the optic canal into dura mater encephali. Eyeball is enveloped by *vagina of eyeball* (Tenon`s capsule). *Adiposal body* of orbit localised between vagina of eyeball and periorbita, which forms elastic pillow for eyeball.

Superior and inferior **eyelids** cover and protect eyeball. Front surface of eyelids is covered by skin. Posterior surface of the eyelids and anterior free surface of eyeball are covered by thin **conjunctiva**. Last forms superior and inferior sac of conjunctiva.

**Tarsal plates**, composed of dense regular connective tissue, are important in maintaining the shape of the eyelids. **Yeybrows** (supercilium) consist of short, sick hair positioned transversally above both eyes along the superior orbital ridges of the skull.

into the nasal cavity. The *excretory ductuli* of lacrimal gland (10-15) open into *conjunctival sac* of upper eyelid (superior rivas). With each blink of the eyelids, tears pass medially and downward and drains into *lake* and two small openings, called **lacrimal puncta** on both sides of the *lacrimal caruncle*. From here, tears drain through the *lacrimal canaliculus* into the *lacrimal sac* and continue through the *nasolacrimal duct* to the inferior meatus of the nasal cavity.

## OLFACTORY ORGAN

Olfactory receptors placed in *olfactory region* of nasal cavity (in superior nasal meatus). Receptors (1<sup>st</sup> neuron) associated with epithelial supporting cells. The peripheral process of olfactory cells carry the olfactory cilia and the central process form 15-20 olfactory nerves (**1<sup>st</sup> cranial nerve**), which pass through the foramina in cribriform plate and reach the *olfactory bulb*. The axons of 2<sup>d</sup> neurons run through the olfactory tract terminate in *olfactory triangle and anterior perforating substance*, where the bodies of the 3<sup>d</sup> neurons lie. Axons of the 3<sup>d</sup> neurons get the *uncus* and other part of *limbic system*, which is cortical olfactory analyser.

## ***EAR (HEARING AND EQUILIBRIUM ORGAN)***

Ear subdivides on auricle (outer ear), middle ear and internal ear. Auricle and external auditory meatus belong to outer ear. Middle ear contains a tympanic cavity and auditory tube (Eustachian). Internal ear composes an osseous labyrinth and membranous labyrinth.

**AURICLE** contains a cartilage covered by skin. In inferior part a cartilage is absent there is auricular *lobule* (earlobe). Also auricle has a *helix, triangular fossa, antihelix, concha, tragus, antitragus*.

**External auditory meatus** is open outside, in depth from cavity of middle ear it dissociates by tympanic membrane. External auditory meatus has cartilaginous part and inner osseous part. Cartilaginous part composes one-third length of auditory meatus. Osseous part occupies two thirds of auditory meatus. Auditory meatus is curved S-like and for its straightening attached to examination of tympanic membrane necessary to draw off auricle posterior, up and outside.

**Tympanic cavity** positioned in thickness of temporal pyramid and has **the** following **walls**:

1. *tegmental* wall (superior);

2. *jugular wall* (inferior);

3. *labyrinthic wall* (medial), where found 2 windows: vestibular (oval) window and cochlear (round) window. Vestibular window is closed by base stapes. Round window is tightened by secondary tympanic membrane;

4. *mastoid wall* (posterior). On it located **stapedius muscle**. Superiorly posterior wall continues into mastoid cave, the mastoid cells open in it;

5. *carotid wall* (anterior), a tympanic foramen of auditory tube and **muscle-tensor of tympanic membrane** are found here;

6. *membranous wall* (lateral) is formed tympanic membrane. Epitympanic recess contains a head of malleus and body of the incus.

Three **auditory ossicles** (malleus, incus and stapes), and two muscles are placed in tympanic cavity. **Malleus** has a head and manubrium with anterior and lateral processes. *Muscle-tensor of tympanic membrane* handle fastened to malleus. **Incus** consists of body, short and long legs. Body of incus adjoins to head of malleus, forming incusomalleus joint. Long leg unites with stapes. **Stapes** has a head, anterior leg and posterior leg and base stapes, which closes a vestibular window. *Musculus stapedius* fastens to posterior leg of stapes. Muscles of tympanic cavity regulate auditory ossicles and prevent their oscillation during loud sounds.

**Osseous labyrinth** consists of cochlea, vestibulum and semicircular canals.

**Vestibulum** represents by cavity, its lateral wall carries vestibular and cochlear fenestrae (windows). *Vestibular (oval) fenestra* contains a base of stapes, and a *cochlear (round) window* is closed by the secondary tympanic membrane. There are 5 foramens of the semicircle canals in posterior wall of vestibulum, anterior wall has a big foramen conducting into cochlear canal. Crest of internal wall separates a *spherical recess* from *elliptic recess*. Internal foramen of vestibular canalicule opens in elliptic recess.

Osseous **semicircular canals** represented by three arched tubes lying in three mutually perpendicular planes. There are *anterior, posterior and lateral* semicircular canals. Each semicircular canal has broadened part in its base anterior, posterior and lateral osseous *ampule*. Semicircle canals join the vestibulum by the medium of osseous legs. Those legs containing ampule are called ampular legs. The legs of the anterior and posterior

semicircular canal fuse together into one. As result the semicircle osseous canals unite with vestibulum by five foramina.

**Cochlea** (snail shell) lies anteriorly from vestibulum, represented by osseous tube forming two and half turns round cochlear axis (*modiolus*). There is osseous *spiral plate* inside the cochlea, apex of the cochlea called **cupula**. In cochlear base internal foramen of cochlear canaliculi is found.

**Membranous labyrinth** is inserted in osseous labyrinth, has the lesser dimensions and repeats the course of osseous labyrinth. The perilymphatic space is situated between internal surface of osseous labyrinth and external surface of membranous one and filled with liquid – *perilymph*. Membranous labyrinth is filled with the *endolymph*. Membranous labyrinth consists of vestibular part (a), semicircular canals (b) and cochlear duct (c).

A. *Vestibular labyrinth* consists of **utricle** and **sacculus**. Utriculus lies in elliptic recess of osseous labyrinth and connects with semicircular ducts, and a sacculus lies in spherical recess of osseous labyrinth and connects with cochlear duct by communicating duct. Utriculus and sacculus communicate each other by the medium of utriculosaccular duct. From last endolymphatic duct starts that passes in vestibular canalicule. Endolymphatic duct passing from external foramen of vestibular canaliculus on posterior surface of pyramide of temporal bone, reaches endolymphatic sacculus placed under cerebral dura mater.

B. Semicircular ducts are inserted in osseous semicircular canals. So there are *anterior, posterior and lateral semicircular ducts*. They carry anterior, posterior and lateral membranous ampulae. Receptors of balance of rotating located in *cristae ampullares*. Receptors of balance located in *static maculae* in utriculus and sacculus.

C. *Cochlear duct* positioned in spiral canal and starts from vestibular osseous labyrinth and finishes in blind end. On transversal cut a cochlear duct has triangle shape and enclosed by external, superior and inferior walls. External wall fused together with periosteum of spiral canal; an inferior wall is a tympanic wall, it supplementes the spiral plate; superior wall is vestibular wall. Cochlear duct occupies middle part of osseous spiral canal and separates *tympanic scala* from *vestibular scala*. Spiral organ (Corti) localised in cochlear duct on spiral membrane, which belongs to peripheral part of auditory analyser.

**Sound waves** are received by tympanic membrane from *auricle* and *external acoustic meatus*. Oscillation of *tympanic membrane* is transfered to auditory ossicles – *malleus, incus* and *stapes*. Base of stapes, which



covers a window vestibulara, begins oscillates the *perilymph*. Oscillation passes through *vestibular scala*, *helicotrema* and *tympenic scala*. Then *vestibular wall* (Reisner's membrane) starts to vibrate. Last forces the oscillation of the *endolymph* in cochlear duct. This vibration is received by sensory *haircells* of spiral (Korti) organ.

### Auditory tract

1. *Body of first neuron* of auditory tract positioned in cochlear ganglion (spiral cochlear ganglion). The peripheral process of first neurons terminates in spiral organ and the central process neurons form **cochlear part of VIII cranial nerve**. It passes through the internal auditory meatus into cranial cavity, where terminates by synapse with second neuron.

2. *The bodies of second neurons* of cochlear nerve are found in anterior and posterior cochlear nucleus in lateral recess of rhomboid fossa. Axons of second neurons form fascicles having a name *trapezoid body*. These fibres terminate partly in superior olivar nucleus. One from posterior cochlear nucleus form *striae medullaris* of fourth ventricle.

3. *The third neuron* of auditory tract positioned in superior olivar nucleus. Their axons a lateral lemniscus, which runs through the isthmus of rhombencephalon (triangle of lemniscus) and reach the subcortical hearing centres.

4. The bodies of fourth neurons of auditory tract located in *medial geniculate body* and *inferior colliculus* of midbrain. Then axons run through the posterior third of posterior leg of *internal capsule* and reach Geshla gyrus (*cortical hearing analyser* in superior temporal gyrus). Axons of the fourth neurons also pass from inferior colliculus to the anterior funiculus of spinal cord as *vestibulospinal tract*. Instantaneous reaction in response to sound (protective reflex) realises by means of this pathway.

### Visual tract

Optic nerve is a part of visual analyser. Three neurons of visual tract are located in retina: **1** – fotoreceptors rods and cones, **2** – bipolar cells and **3** – ganglionic (multipolar) cells. Axons of third neurons form the **II Optic nerve**, which passes through the *optic canal* and get the cranial cavity. Medial fibres of the optic nerve pass to the opposite side and form the *optic chiasma*. Lateral fibres part do not cross each other and keep their own side. Then fibres of the optic nerve form *optic tract* wich get the

*subcortical sight centres (lateral geniculate body and superior colliculus of midbrain). Then 4<sup>th</sup> neurons are located under pulvina thalami. Their axons run through the posterior leg of internal capsule (visual radiation) and reach cortical visual analyser in calcarine sulcus (occipital lobe).*

Axons of optic tract contact with cells in accessory oculomotor / parasympathetic/ nucleus (Yakubovych-Edinger-Westphal's) by means of intermediate neuron. There are link for realising the **pupillar reflex** and **accomodation**. Axons of fifth neurons run in composition of oculomotor nerve get a *ciliary ganglion*, where sixth neurons positioned. Their axons pass with short ciliary nerves into eyeball and give innervating for *ciliary and sphincter pupillae muscles*. This reflex does not depend on our will and consciousness.

Fibres of **III Oculomotor nerve** starts from *motor* nucleus and *accessory* oculomotor /parasympathetic/ nucleus (Edinger-Westphal's). They are found in lamina tecti of midbrain (superior colliculus). Nerve exits from brain in interpeduncular fossa then it passes through the superior orbital fissura. Here it subdivides into *superior and inferior* branches. Nervous fibres from superior branch innervate superior rectus muscle and levator of superior eyelid. Motor fibres from inferior branch innervate inferior and medial rectus muscles and also inferior oblique muscle. The parasympathetic fibres form *oculomotor radix* and reach the ciliary ganglion. The postganglionic parasympathetic fibres from ganglion pass in composition of short ciliary nerves to ciliary and sphincter pupillae muscles.

**IV Trochlear nerve** has an own motor nucleus, which is disposed in quadrigeminal plate on level of inferior colliculus of midbrain. Their axons exit from brain from superior cerebral vellum, then pass laterally from lateral cerebral pedunculi and through the superior orbital fissura. Trochlear nerve supplies superior oblique muscle.

**VI Abducens nerve** has a motor nucleus, which is disposed superficially in facial colliculus (rhomboid fossa). Axon exits from brain in fissure between pyramids of medulla oblongata and pons, and from skull – through the superior orbital fissura. Abducens nerve supplies lateral oblique muscle.

**V Trigeminal nerve** has one *motor* nucleus and *mesencephalic, pontine & spinal sensory* nuclei. They localised in pons (rhomboid fossa), mesencephalon and spinal cord. Nerve starts from brain by *sensory* rootlet and *motor* rootlet between pons and middle cerebellar pedunculi. Sensory rootlet represents by central process of sensory cells, which lie in *trigeminal*

## V-X CRANIAL NERVES

### Cranial Nerves

#	Name	Position	Foramen	Function
<b>I</b>	Olfactory	olfactory bulb	openings of the cribriform plate of ethmoidal bone	smell
<b>II</b>	Optic	optic chiasm	optic canal	vision
<b>III</b>	Oculomotor	interpeduncular fossa	superior orbital fissure	eye muscles
<b>IV</b>	Trochlear	superior medullary velum	superior orbital fissure	eye muscles
<b>V</b>	Trigeminal	between the pons and medn cerebellar pedunculi	(1) Ophthalmic superior orbital fissure, (2) Maxillary foramen rotundum, (3) Mandibular foramen ovale	face sensation & mastication
<b>VI</b>	Abducent	between the pons and pyramids	superior orbital fissure	eye muscles
<b>VII</b>	Facial	cerebellopontine angle	internal acoustic meatus, stylomastoid foramen	face muscles, salivary & lacrimal glands
<b>VIII</b>	Vestibulo-cochlear	cerebellopontine angle	internal acoustic meatus	hearing & balance
<b>IX</b>	Glossopharyngeal	dorsal lateral sulcus of medulla oblongata	jugular foramen	pharynx, tongue & parotid gland
<b>X</b>	Vagus	dorsal lateral sulcus of medulla oblongata lower X pair	jugular foramen	pharynx, larynx & thoracic and abdominal viscera
<b>XI</b>	Accessory	dorsal lateral sulcus of medulla oblongata lower XI pair	jugular foramen	neck muscles (Trapezius/ sternocleidomastoid)
<b>XII</b>	Hypoglossal	between olive and pyramid	hypoglossal canal	tongue & neck muscles

*ganglion* (Gasser's) on top of pyramide of temporal bone. This ganglion is contained in trigeminal cavity (Meckel's) which is formed by dura mater. Motor rootlet represents by axons from motor cells (motor nucleus).

Trigeminal nerve passes from skull by three divisions:

1. Ophthalmic nerve, sensory, exits from skull through the superior orbital fissura;
2. Maxillary nerve, sensory, exits from skull through the rotundum foramen;
3. Mandibular nerve, mixed, exits from skull through the ovale foramen.

**1.1. Ophthalmic** nerve fossa subdivides in orbital into frontal nerve, lacrimal nerve and nasociliary nerve. *Nasociliary* nerve passes on superomedial wall of orbite and under block innervating medial eye corner and nose. Sensory *long ciliary nerves* pass to the coats of the eyeball, *short ciliary nerves* pass through the ciliary ganglion and carry parasympathetic and sympathetic fibres for eyeball with all its tissues and muscles (sphincter pupillae, dilator pupillae and ciliary muscle). *Posterior and anterior ethmoidal* nerves pass through the posterior and anterior ethmoidal foramen. They innervate mucous membrane of ethmoidal cells (air sinus) and anterior part of nose cavity.

*Frontal* nerve passes on middle part of upper wall of orbite and passes on forehead skin over *supraorbital* and *frontal* notches by three branches, innervating forehead skin and top eyelid. *Lacrimal* nerve passes on upper-lateral wall of orbite, transfixes a lacrimal gland, innervating it. Passing out from gland, it innervates the skin of lateral eye corner. Postganglionic and parasympathetic fibres from pterygopalatine ganglion (which pass with zygomatic nerve) pass to lacrimal nerve and provide a secretory innervation of the lacrimal gland.

**5.2. Maxillary** nerve passes through the rotundum foramen and reaches the pterygopalatine fossa, where ramifies on three branches: infraorbital nerve, zygomatic nerve and ganglionic branches to pterygopalatine ganglion.

*Infraorbital* nerve passes through the inferior orbital fissura enters into orbite, where lies on its lower wall, passes in infraorbital fissura and infraorbital sulcus and canal. Nerve passes into canine fossa, forming '*pes anserinus minor*'. There are *inferior palpebral*, *external nasal* and *superior labial* nerves that innervate skin from medial eye corner to mouth corner. *Superior alveolar nerves* (*posterior, middle and inferior*) start from infraorbital nerve in maxilla. They innervate mucous membrane of the maxillary

(Haymori) sinus and form superior dental plexus. The last gives off the *superior dental nerves* and *superior gingival branches* of the upper jaw.

Zygomatic nerve passes through the inferior orbital fissura entering orbita. Then it passes into zygomaticoorbital foramen and divided into *zygomaticofacial* and *zygomaticotemporal* sensory branches for skin of face and temporal region. Zygomatic nerve carries postganglionic parasympathetic fibres from pterygopalatine ganglion and gives off them to lacrimal nerve. Parasympathetic fibres provide secretory innervation of the lacrimal gland.

The ganglionic branches start from maxillary nerve and pass to pterygopalatine ganglion. Postganglionic branches include *greater palatine* nerve and *lesser palatine* nerve that pass through the greater palatine canal and lesser palatine foramens, innervating mucous membrane of the hard and soft palatine. The *posterior nasal* (medial and lateral) nerves pass through the sphenopalatine foramen pass into nasal cavity, where innervate mucous membrane of the nasal cavity. *Nasopalatine* nerve (Scarp') start from the nasal branches and reach the mucous membrane of the hard palatine through the incisive canal. Postganglionic parasympathetic fibres from pterygopalatine ganglion are in composition of these nerves.

**5.3 Mandibular nerve** carries both the motor and sensory fibres. After passing out from ovale foramen mandibular nerve gives off the motor branches that innervate all 4 masticatory muscles, also *velli palatine tensor* muscle and nerve *tensor of tympanic membrane muscle*. Sensory branches of the mandibular nerve: buccal nerve, auriculotemporal nerve, lingual nerve inferior alveolar nerve and meningeal branches.

Buccal nerve transfixes a buccinator muscle and innervates mucous membrane of the cheek and also mouth corner skin.

Auriculotemporal nerve begins by two rootlets that envelop a middle meningeal artery, and then unite into one trunk, which transfixes parotid gland, innervating it and skin of temporal area, also, the auricle. Postganglionic parasympathetic fibres from **otic ganglion** pass in composition of this nerve, which provide a secretory innervation of parotid gland.

Lingual nerve passes on internal surface of lower jaw under mucous membrane of the mouth cavity and enters into lower part of tongue, providing a general sensory innervation of the anterior 2/3 part and sensory innervation sublingual and submandibular salivary glands. Chorda tympani (from 7th cranial nerve), which contains the gustatory (tasting) and secretory (parasympathetic) fibres. Gustatory fibres innervate of tasting buds on mucous membrane of the anterior 2/3 part of the tongue, and

secretory (parasympathetic) enter into **submandibular** and sublingual parasympathetic **ganglia**. The postganglionic fibres from these ganglia provide a secretory innervation the same name – submandibular and sublingual salivary glands.

Inferior alveolar nerve (mixed) has a motor branches that supply *mylohyoid muscle* and anterior belly of the *digastric muscle*. The sensory fibres enter into mandibular channel, where form inferior dental plexus, branches innervate the *teeth and gums* of lower jaw. From canal these fibres are passing out from bone as a *mental nerve*, which terminates in skin of lower lip and chin.

**VII Facial nerve** consists of 1- *proper facial nerve*, which has fibers starting from motor nucleus in depth of facial colliculus in rhomboid fossa, and 2- *intermediate nerve*, which has a fibers of sensory nucleus of solitarius tract and parasympathetic – superior salivatory nucleus.

Facial nerve passes through facial canal, gives off motor branch for *stapedius muscle*, then exits from skull through the stylomastoid foramen and innervates *posterior auricular, stylohyoid* muscles and posterior belly of *digastric* muscle. Facial nerve enters into thickness of parotid salivary glands (but does not innervate it!) and forms there parotid plexus. Last gives off the motor branches which innervate ***facial expression (mimetic) muscles***. There are: temporal branches (supply auricular, orbicularis oculi and occipitofrontalis muscles), zygomatic branches (they supply zygomatic major and orbicularis oculi muscles), buccal branches (supply zygomatic major and minor, levator labii superioris, buccinator, orbicularis oris, nasalis, and risorius muscles), marginal mandibulae branch (supplies depressor anguli oris and depressor labii inferioris, mentalis muscles) and cervical branch (for the platysma).

*Intermediate nerve* has two divisions: Nervus petrosus major and Chorda tympani.

**Greater petrosal nerve** (preganglionic secretory fibers to the lacrimal glands, nasal glands and palatal glands) separates off from the geniculate ganglion, extends through the hiatus of the canal for the greater petrosal nerve, across the foramen lacerum and finally through the pterygoid canal to the *pterygopalatine ganglion*.

**Chorda tympani** carries preganglionic secretory fibers to the submandibular and sublingual glands and taste fibers to the anterior two third of the tongue. Taste (sensory) fibers contain peripheral axons of cells localized in geniculate ganglion. The central process of neurocytes of this ganglion terminate in nucleus of solitarius tract. Chorda tympani passes

through the petrotympanic fissura and joins the *lingual nerve* (from the V<sup>th</sup> cranial nerve), then its branches reach the tongue and *parasympathetic* submandibular and sublingual ganglia for innervating the same names salivary glands.

**IX Glossopharyngeal nerve** is mixed nerve, which has a nucleus ambiguous (motor), nucleus of the tractus solitarius (sensory) and inferior salivatory nucleus (parasympathetic) in rhomboid fossa. Sensory fibers start from a superior and inferior *ganglia* in region of the jugular foramen. Glossopharyngeal nerve reaches the tongue root, where divides by final branches **rr. *linguales***, that innervating mucous membrane the posterior third of the tongue.

Glossopharyngeal nerve gives off the following branches:

1. *Tympanic nerve* (mixed) passes through tympanic canalicule and enters into tympanic cavity. Here its sensory branches together with caroticotympanic nerves (sympathetic) form *tympanic plexus* which innervate mucous membrane of the tympanic cavity and auditory tube (*r. tubarius*). The parasympathetic preganglionic fibers start from inferior salivatory nucleus, exit from tympanic cavity through hyatus nervi petrosi minoris as *lesser petrosal nerve*. Last passes in sulcus and enters into *otic ganglion*. Postganglionic fibres provide a secretory innervation of parotid salivary glands.

2. *Pharyngeal* branches pass to lateral wall of the pharynx, where together with branches of vagus nerve and sympathetic trunk form *pharyngeal plexus*. Last provides innervating of the muscles and mucous membrane of the throat.

3. *Tonsillar* branches pass to mucous membrane of the palatine tonsils and palatal arches.

4. Branch of stylopharyngeal muscle.

5. Branch of carotid sinus, innervating the receptors of carotid glomus and sinus.

6. Communicating branch with the auricular branch of vagus nerve.

**X Vagus nerve** (mixed) contains *motor* fibers which start from nucleus ambiguus, *parasympathetic* (preganglionic) fibers form dorsal nucleus and *sensory* fibers from superior and inferior ganglia in jugular foramen.

• Cranial part of vagus nerve gives off the following branches:

*Meningeal* branch which starts from superior ganglion and passes to cranial dura mater in posterior cranial fossa;

*Auricular* branch, which starts from superior ganglion, passes over mastoid canalicule of temporal bone and innervates the skin of external surface of auricle and posterior wall of external acoustic meatus.

- Cervical part of vagus nerve gives off:

*Pharyngeal branches* with branches of Glossopharyngeal nerve and sympathetic trunk form *pharyngeal plexus*, that innervates mucous membrane and muscles of the throat (superior and middle constrictors; levator veli palatini, palatopharyngeus and palatoglossus, uvulae muscles).

*Superior cervical cardiac branches* pass downward along common carotid artery and communicate with sympathetic nerves, enter into cardiac plexus and supply the heart (sensory and parasympathetic innervating).

*Superior laryngeal nerve* originate from inferior ganglion and carry sensory, motor and parasympathetic preganglionic fibers. Motor fibers of the *external branch* innervate cricothyroid and inferior constrictor muscles, sensory fibers (*internal branch*) supply mucous membrane of the larynx over vocal fold, mucous membrane of the epiglottis and tongue root.

*Recurrent laryngeal nerve* passes upward between esophagus and trachea and sends a numerous twigs. *Inferior laryngeal nerve* supplies mucous membrane of the larynx below vocal fold and the rest of muscles (thyroarytenoid, lateral and posterior cricoarytenoid, transverse and oblique arytenoid, vocalis). *Tracheal, esophageal* and *inferior cervical cardiac branches* supply internal organs.

- Thoracic part of vagus nerve gives off:

*Thoracic cardiac branches* which pass to cardiac plexus;

*Bronchial branches* with sympathetic nerves form pulmonary plexus. Last enters in lungs with bronchi.

Esophageal branches form *esophageal plexus* round this organ.

- Abdominal part of vagus nerve is represented by anterior and posterior vagal trunks, which originate from esophageal plexus. *Anterior vagal trunk* located on front surface of the stomach and gives branches gives off the anterior gastric and hepatic branches. *Posterior vagal trunk* supplies back gastric wall, and gives off coeliac branches to reach coeliac plexus. Then fibers of vagus nerve with sympathetic fibers supply the liver, spleen, pancreas, kidneys, small and large intestine (including a upper department of descending colon).

**XI Accessory nerve** is a motor nerve, which has a ambiguous nucleus (cranial) and nucleus of accessory nerve (spinal nucleus). The accessory rootlets pass through the jugular and magnum foramen. Trunk of accessory nerve divides into internal branch and external branch. Internal branch



joints vagus nerve, and an external branch reaches the sternocleidomastoid and trapezius muscles (innervating them).

**XII Hypoglossal nerve** is a motor nerve, which has an motor nucleus in hypoglossal trigone of rhomboid fossa. Nerve exits from myelencephalon by numerous rootlets in furrow between pyramid and olive, and passes through the of hypoglossal canal. Hypoglossal nerve runs into submandibular triangle (it borders lingual triangle here) and enters into tongue thickness, where disintegrates on lingual branches, that innervate all tongue muscles (Extrinsic: Genioglossus, Hyoglossus and Styloglossus muscles; and intrinsic: Superior Longitudinal, Inferior Longitudinal, Transverse and Vertical muscles).

Hypoglossal nerve gives off the descending ramus which joins with descending branch from cervical plexus forming **ansa cervicalis**. It gives off the motor branches innervating infrahyoid muscles: sternohyoid, sternothyroid, omohyoid and thyrohyoid.

## TASTE ORGAN

In man gustatory buds (2000 in number) are situated in mucous membrane of the *tongue*, palatine, pharynx, epiglottis. Most of gustatory buds localised in *vallatae*, *foliatae* and *fungiform papillae* of the tongue. In front 2/3 part of tongue tasting impulses are perceived by fibres of *chorda tympani* (intermediate nerve), in back 1/3 portion of tongue – by *glossopharyngeal nerve*, in lingual root and epiglottis – by fibres of *vagus nerve*.

The central process of first neurons, that are situated in mouth cavity, pass in composition of VII, IX, X cranial nerves to tasting sensory nucleus that positioned in medulla oblongata – *nucleus tractus solitarius*. Axons of second neurons run to the *thalamus*, where the third neuron is situated. Axons of third neurons terminate in *uncus* (cortex of cerebrum), where is situated a cortical taste analyzer.

## GENERAL COVER (skin)

Includes a skin and hypodermic stratum. Skin forms general bodies cover, which defends the organism from influence of external environment. It carries out regulation of warmly, metabolism, breathing, excretes the sweat and fat and is as depot of power resources. Skin is sensory organ and built from two layers:

1. *epidermis* (superficial layer);

2. *dermis* (deep layer, or proper skin), which consists of fibrous connective tissue, elastic and muscular fibers.

Blood and lymphatic capillaries, and terminal nervous bodies present in superior dermal layer. Lower stratum of dermis passes into hypodermic base where agglomeration of adipose cells is situated.

Skin color depends on pigment (melanin), which positioned in innermost layer of epidermis. Hair and nails derive from epidermis.

**Hairs** cover the skin (except palms, soles, transitional part of lips, head and preputium of penis, minor pudenda labia). Hair has a *shaft* and *root*. Last lies in deepness of skin and terminates by hair bulb, which provides growth of hair. Root of hair lies *hair follicle* where *sebaceous gland* opens and *erector pili muscle* attaches.

**Nail** is flattened elastic structures of a horny texture plate lying in connective tissue nail bed where it begins to growth. In nail there distinguish a nail *root*, nail *body* and *free edge*, which stick out from nail bed border, and also cover margin and lateral margin.

**Skin Glands.** Derivates of skin – *sebaceous glands* and *sweat glands* – are learned in histology course carefully.

**Hypodermic stratum** contains nervous and venous plexus, lymphatic vessels and hypodermic adipose tissue, which carry out function of thermal isolation and depot of energetic reserve. Also a soft connective tissue there is situated.

**Mammary gland** is modified sweat gland, which lies on fascia of major pectoral muscle on level of the III-VI ribs. Body of breasts consists of lobes of mammary gland, which contain 15-20 *lobules* of mammary gland, dis severed one from one by bands of connective tissue. The smallest lobules consist of a cluster of rounded alveoli, which open into the smallest branches of the *lactiferous ducts*; these ducts communicate by to form larger ducts, and these end in a single canal, corresponding with one of the chief subdivisions of the gland. They converge toward the areola, beneath which they form dilatations *sinus*, which serve as reservoirs for the milk, and, at the base of the *papillæ*. Lobes are disposed relatively to mammary *nipple* radially, and the mammary ducts open on the top of nipple. *Mammary areola* positioned round mammary nipple covered areolar tubercles where open *areolar glands*.



Оригінал-макет підготовлено у відділі комп'ютерної верстки  
видавництва "Укрмедкнига"  
Тернопільської державної медичної академії ім. І.Я. Горбачевського.  
Майдан Волі, 1, м. Тернопіль, 46001, Україна.

Надруковано у друкарні видавництва "Укрмедкнига"  
Тернопільської державної медичної академії ім. І.Я. Горбачевського.  
Майдан Волі, 1, м. Тернопіль, 46001, Україна.

Свідоцтво про внесення до державного реєстру суб'єктів видавничої справи  
ДК № 348 від 02.03.2001 р.